



Providing Choice & Value

Generic CT and MRI Contrast Agents



**FRESENIUS
KABI**

CONTACT REP

AJNR

MR Imaging of BK Virus Encephalitis

D.P. Friedman and A.E. Flanders

AJNR Am J Neuroradiol 2006, 27 (5) 1016-1018

<http://www.ajnr.org/content/27/5/1016>

This information is current as
of July 29, 2025.

D.P. Friedman
A.E. Flanders

SUMMARY: BK virus infection is most often associated with urologic disease in patients who have undergone renal or bone marrow transplantation. We report a rare case of biopsy-confirmed BK virus encephalitis in an immunocompromised patient with hemorrhagic cystitis, in whom dramatic imaging findings were present despite relatively mild clinical symptoms. MR imaging demonstrated widespread increased signal intensity on T2- and fluid-attenuated inversion recovery–weighted images, with restricted diffusion, in the cerebellum, cerebral white matter, and deep gray matter structures. The simultaneous presence of urologic abnormalities and neurologic deficits in certain immunocompromised patients should prompt consideration of BK virus encephalitis.

BK virus infects as much as 80%–90% of the population; most primary infections are asymptomatic or minimally symptomatic (fever, upper respiratory symptoms).¹ After primary infection, a latent infection is established in renal epithelial cells and possibly other tissues (including the brain).^{1–4} Significant clinical manifestations are almost always limited to patients with impaired immune function.^{1–3} The spectrum of clinical and imaging manifestations of BK virus encephalitis is not known. To the best of our knowledge, only a few cases (diagnosed by polymerase chain reaction of CSF) have been reported.^{5–8}

Case Report

During treatment of hemorrhagic cystitis secondary to BK virus in December 2003, a 38-year-old woman developed progressive mental status changes and lethargy. Neurologic examination revealed generalized psychomotor slowing and dysarthria, but the examination was otherwise nonfocal. In 1989, the patient had been treated for nodular sclerosing Hodgkin lymphoma; in 2002, she suffered a relapse that was treated with radiation, chemotherapy, and ultimately a stem cell and bone marrow transplant in February 2003. Although her lymphoma was in remission, she developed multiple urologic problems, including intractable hemorrhagic cystitis.

MR imaging of the brain was performed to evaluate her current neurologic decline. The examination demonstrated widespread increased signal intensity on T2 and fluid-attenuated inversion recovery (FLAIR)–weighted images, along with restricted diffusion, in the cerebellum and cerebral hemispheric white matter (Fig 1A–H). Similar abnormalities were present in the globus pallidi bilaterally and, to a lesser extent, the thalami (Fig 1A). The deep cerebellar white matter and cerebral cortex appeared to be spared. The cerebellum was diffusely swollen (Fig 1I). There was no abnormal enhancement or hemorrhage. On the basis of the imaging findings, the differential diagnosis included hypoxic-ischemic injury, encephalitis, or a toxic, metabolic, or drug-related process. Further medical and laboratory evaluation did not yield a diagnosis, and a brain biopsy was performed. The biopsy showed nonspecific reactive astrocytosis and rare perivascular lymphocytes; no viral inclusions were identified. Tissue polymerase chain reaction for BK virus revealed 8 viral DNA copies/1000 cells; this was felt to be most compatible with BK virus encephalitis. The patient continued to receive antiviral agents (gancyclovir,

valcyclovir, acyclovir) for treatment of her BK viremia and encephalitis and also had adjustment of her immunosuppression. Her neurologic status improved, though she died 5 months later of multiple other medical problems.

Discussion

Human polyoma viruses are members of the Papovaviridae family, which are small, nonenveloped viruses with a closed, circular double DNA-stranded genome.^{1,9} Polyoma viruses are ubiquitous in nature and can be isolated from a number of species. They are named BK and JC after the initials of the patients in whom they were first discovered in 1971. The BK virus was isolated from the urine of a renal transplant recipient with ureteric stenosis. The JC virus was isolated from the brain tissue of a patient with Hodgkin disease and progressive multifocal leukoencephalopathy. Infections with BK virus usually occur first in childhood (age 3–4 years) via the respiratory tract; most primary infections are asymptomatic or minimally symptomatic (fever, upper respiratory symptoms).¹ After primary infection, a latent infection is established in renal epithelial cells, and possibly other tissues (including the brain). By adulthood, as many as 90% of individuals have antibodies to BK virus.^{1–4}

In states of relative or absolute immunodeficiency, the BK virus can reactivate and cause disease. BK viremia can be seen in patients with a variety of immunodeficiencies but appears most frequently in renal and bone marrow transplant patients.^{1,3,5,9–11} Clinically significant infections with BK virus have also been described in patients with acquired immunodeficiency syndrome.^{6,8,12} In rare cases BK virus can cause significant disease in immunocompetent hosts.⁷ BK virus has been associated with such diverse entities as hemorrhagic cystitis, ureteric stenosis, tubulointerstitial nephritis, vasculopathy, pneumonitis, encephalitis, retinitis, and even multiorgan failure.^{1–12} In particular, whenever an episode of renal dysfunction occurs in a patient with a renal transplant, BK virus should be ruled out as the cause.

To the best of our knowledge, there have been only a few reported cases of BK virus encephalitis^{5,8}; the diagnosis has usually been established by testing of CSF with the polymerase chain reaction. In our case, the diagnosis was established by using a polymerase chain reaction assay of tissue. In one reported case, MR imaging showed diffuse, reversible white matter changes, most prominent on long-TR images.⁷ In our patient, an extensive white matter abnormality was identified in the supratentorial brain; it was interesting that the deep white matter of the cerebellum was largely spared. Deep gray matter structures were also involved. Restricted diffusion,

Received March 11, 2005; accepted after revision April 27.

From the Department of Radiology, Jefferson Medical College and Thomas Jefferson University Hospital, Philadelphia, Pa.

Address correspondence to David P. Friedman, Department of Radiology, Jefferson Medical College and Thomas Jefferson University Hospital, 132 South 10th St, Suite 1072, Main Building, Philadelphia, PA 19107.

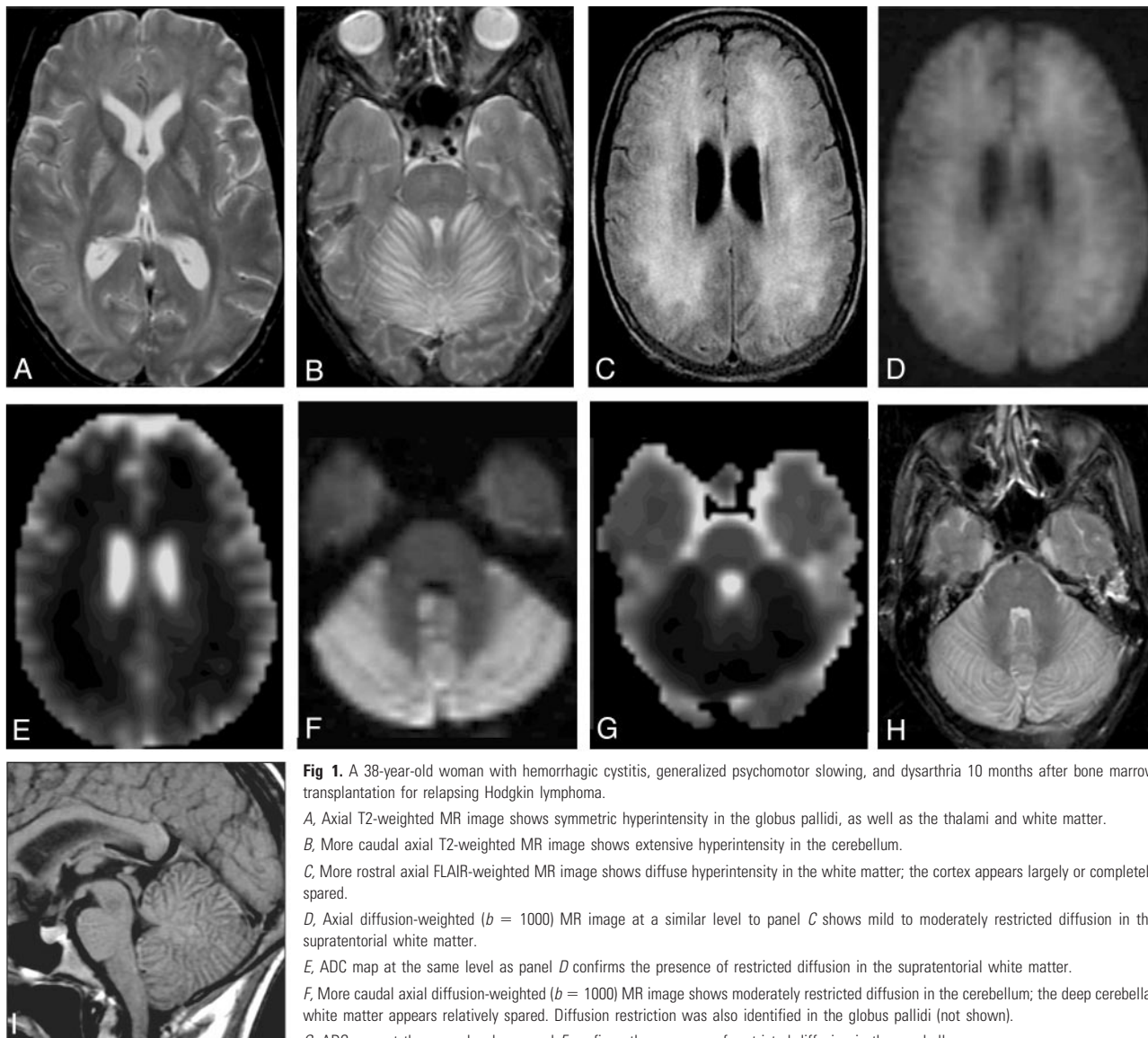


Fig 1. A 38-year-old woman with hemorrhagic cystitis, generalized psychomotor slowing, and dysarthria 10 months after bone marrow transplantation for relapsing Hodgkin lymphoma.

A, Axial T2-weighted MR image shows symmetric hyperintensity in the globus pallidi, as well as the thalami and white matter.

B, More caudal axial T2-weighted MR image shows extensive hyperintensity in the cerebellum.

C, More rostral axial FLAIR-weighted MR image shows diffuse hyperintensity in the white matter; the cortex appears largely or completely spared.

D, Axial diffusion-weighted ($b = 1000$) MR image at a similar level to panel C shows mild to moderately restricted diffusion in the supratentorial white matter.

E, ADC map at the same level as panel D confirms the presence of restricted diffusion in the supratentorial white matter.

F, More caudal axial diffusion-weighted ($b = 1000$) MR image shows moderately restricted diffusion in the cerebellum; the deep cerebellar white matter appears relatively spared. Diffusion restriction was also identified in the globus pallidi (not shown).

G, ADC map at the same level as panel F confirms the presence of restricted diffusion in the cerebellum.

H, Axial T2-weighted MR image at a similar level as panel F shows extensive hyperintensity in the cerebellum.

I, Sagittal T1-weighted enhanced MR image shows generalized swelling and hypointensity of the cerebellum. The deep cerebellar white matter appears relatively spared. There is no abnormal enhancement of the visualized parenchyma.

which can be present in the setting of encephalitis, was identified in the affected areas of the parenchyma. Although the cerebellum was diffusely swollen, swelling was not demonstrated in the supratentorial brain. The cause for the distribution and appearance of these lesions is not known. Also interesting, despite the extensive imaging abnormalities, the patient demonstrated only modest, nonfocal, cognitive neurologic deficits.

Encephalitis refers to parenchymal inflammation caused by a variety of pathogens, most commonly viruses. Some agents have a predilection for particular areas of the brain; for example, herpes simplex type I favors the limbic system, cytomegalovirus favors the periventricular white matter, and *Listeria monocytogenes* favor the brain stem and cerebellum. Other agents may affect multifocal areas of cortex. MR imaging usually shows abnormal hyperintensity on T2- and FLAIR-weighted images in the gray matter, white matter, and/or deep gray nuclei; diffusion restriction is com-

monly seen.¹³ In this context, the clinical and MR imaging findings in this patient, though not characteristic of a particular infectious agent, are certainly compatible with the diagnosis of encephalitis.

Treatment of clinically significant BK virus infection is currently under investigation. Reduction of immunosuppression in transplant recipients is a mainstay of treatment; however, this therapy clearly has deleterious implications for the success of the transplant. Administration of the antiviral agent cidofovir (Vistide) may also be beneficial.¹

Conclusion

BK virus is a ubiquitous infectious agent that can be isolated from most adults. Although rare, BK virus can cause diffuse encephalitis, and this diagnosis should be considered in certain immunocompromised patients, particularly those with coexistent urologic disease and neurologic decline.

References

1. Reploeg MD, Storch GA, Clifford DB. **BK virus: a clinical review.** *Clin Infect Dis* 2001;33:191–202
2. Shinohara T, Matsuda M, Cheng SH, et al. **BK virus infection of the human urinary tract.** *J Med Virol* 1993;41:301–05
3. Hogan TF, Broden EC, McBain JA, et al. **Human polyomavirus infections with JC virus and BK virus in renal transplant patients.** *Ann Intern Med* 1980;92:373–78
4. Elsner C, Dorries K. **Evidence of human polyomavirus BK and JC infection in normal brain tissue.** *Virology* 1992;191:72–80
5. Behzad-Bekbahani A, Klapper PE, Vallely PJ, et al. **BK virus DNA in CSF of immunocompetent and immunocompromised patients.** *Arch Dis Child* 2003;88:174–75
6. Bratt G, Hammarin AL, Grandien M, et al. **BK virus as the cause of meningo-encephalitis, retinitis, and nephritis in a patient with AIDS.** *AIDS* 1999;13:1071–75
7. Voltz R, Jager G, Seelos K, et al. **BK virus encephalitis in an immunocompetent patient.** *Arch Neurol* 1996;53:101–03
8. Vallbracht A, Lohler J, Grossman J, et al. **Disseminated BK type polyomavirus infection in an AIDS patient associated with central nervous system disease.** *Am J Pathol* 1993;143:29–39
9. Imperiale M. **The human polyomaviruses, BKV and JCV: Molecular pathogenesis of acute disease and potential role in cancer.** *Virology* 2000;267:1–7
10. Arthur RR, Shah KV, Baust SJ, et al. **Association of BK viruria with hemorrhagic cystitis in recipients of bone marrow transplants.** *N Engl J Med* 1986;315:230–34
11. Nichelhect V, Hirsch HH, Binet IF, et al. **Polymavirus infection of renal allograft recipients: from latent infection to manifest disease.** *J Am Soc Nephrol* 1999;10:1080–89
12. Cubukcu-Dimopulo O, Greco A, Kamar A, et al. **BK virus infection in AIDS.** *Am J Surg Pathol* 2000;24:145–49
13. Hansman Whiteman ML, Bowen BC, Donovan Post MJ, et al. **Intracranial infection.** In: Atlas SW, ed. *Magnetic resonance imaging of the brain and spine*. 3rd ed. Philadelphia: Lippincott Williams and Wilkins;2002:1099–1100