



Discover Generics

Cost-Effective CT & MRI Contrast Agents



[VIEW CATALOG](#)

AJNR

Mutation in ROBO3 Gene Recently Demonstrated in Patients with Horizontal Gaze Palsy with Progressive Scoliosis

John MacDonald

AJNR Am J Neuroradiol 2007, 28 (2) 198
<http://www.ajnr.org/content/28/2/198>

This information is current as of September 8, 2025.

Mutation in ROBO3 Gene Recently Demonstrated in Patients with Horizontal Gaze Palsy with Progressive Scoliosis

The recent report in *AJNR* by dos Santos et al¹ shows a case of MR imaging features in a child with horizontal gaze palsy with progressive scoliosis. This rare disorder has recently been shown by Jen et al² to be secondary to defective brain stem crossing of descending corticospinal and somatosensory axons due to mutations in the ROBO3 gene that is necessary for axon crossing in the hindbrain.

References

1. dos Santos AV, Matias S, Saraiva P, et al. MR imaging features of brain stem hypoplasia in familial horizontal gaze palsy and scoliosis. *AJNR Am J Neuroradiol* 2006;27:1382–83
2. Jen JC, Chan W, Bosley TM, et al. Mutations in a human ROBO gene disrupt hindbrain axon pathway crossing and morphogenesis. *Science* 2004;304:1509–13. Epub 2004 Apr 22

John MacDonald
Child Neurology
Minneapolis Clinic of Neurology
Minneapolis, Minn

Ectopic Posterior Pituitary Lobe and Cortical Dysplasia

We read with interest the report by Mitchell et al¹ of 4 cases of ectopic posterior pituitary lobe and periventricular heterotopia on MR imaging studies. The authors suggested that ectopic posterior pituitary lobe with growth hormone deficiency is part of a spectrum associated with septo-optic dysplasia and concluded that the coexistence of periventricular heterotopia dysplasia implies a common underlying genetic mechanism. Further, in 1 case, they found the presence of a heterozygous *HESX1* mutation, a gene associated with ectopic posterior pituitary lobe and septo-optic dysplasia, and suggested that this gene is important in the development of both ectopic posterior pituitary lobe and periventricular heterotopia.

We report a case of a 4-year-old boy with a history of seizures. The patient had an episode of convulsive seizure in March 2006, with a left focal onset. His medical history included panhypopituitarism and optic atrophy of the right eye. Physical examination was significant for a pale right optic disk. MR imaging revealed ectopic posterior pituitary lobe, a hypoplastic pituitary, and a hypoplastic optic chiasm on the T1-weighted sagittal images (Fig 1A, -B). Incidentally, the pituitary stalk could not be visualized. T2-weighted axial and coronal fluid-attenuated inversion recovery (FLAIR) images showed bifrontal cortical dysplasia and a strip of ectopic gray matter extending from the head of the right caudate nuclei to the orbitofrontal lobe (Fig 2A, -B). T2-weighted axial images also revealed small optic nerves, especially on the right side.

The syndrome of septo-optic dysplasia consists of a combination of malformations including hypoplasia or absence of a septum pellucidum or corpus callosum, optic nerve hypoplasia or dysplasia, pituitary-hypothalamic dysfunction, and occasionally other cerebral abnormalities such as schizencephaly or cortical dysplasia. This heterogeneity of features has resulted in some disagreement as to how septo-optic dysplasia is to be defined and categorized. For example, both Barkovich et al² and Miller et al³ attempted to define and classify septo-optic dysplasia into distinct anatomic subsets. However, Polizzi et al⁴ suggested that septo-optic dysplasia should be recategorized as a heterogeneous malformation syndrome encompassing multiple brain, endocrine, and systemic anomalies, rather than a single, precisely defined entity. Our patient did not have hypoplasia or absence of the septum pellucidum; however, the presence of an ectopic posterior pituitary lobe, optic nerve hypoplasia, optic chiasm hypoplasia,

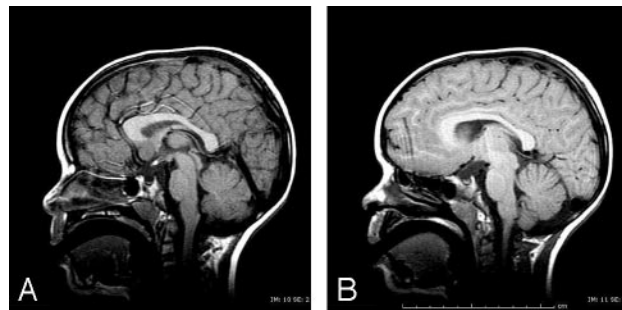


Fig 1. A, Sagittal T1-weighted image shows a hyperintensity corresponding to an ectopic posterior pituitary lobe located in the hypothalamic area. The pituitary is small.

B, Paramedian sagittal T1-weighted image reveals a thin optic chiasm and a small pituitary.

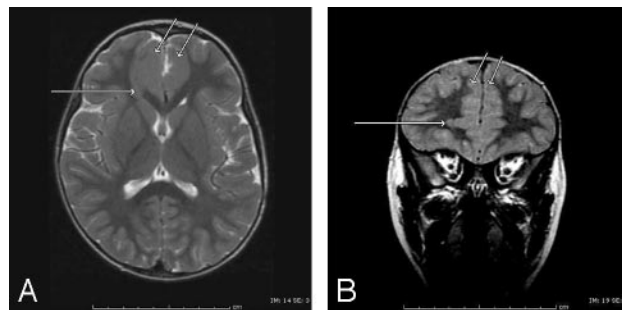


Fig 2. A, Axial T2-weighted image reveals thickening of the cortical gray matter at the medial aspect of both frontal lobes, compatible with bifrontal cortical dysplasia (short arrows). Also seen is a strip of ectopic gray matter extending from the head of the right caudate nuclei to the orbitofrontal cortex (long arrow).

B, Coronal FLAIR image shows a strip of ectopic gray matter extending from the head of the right caudate nuclei to the orbitofrontal cortex (long arrow) as well as bifrontal thickening of the cortical gray matter (short arrows).

cortical dysplasia, and ectopic gray matter suggests features of septo-optic dysplasia.

We, therefore, agree with Mitchell et al¹ that the presence of ectopic posterior pituitary lobe is often associated with other important cerebral malformations, even in the absence of classic features of septo-optic dysplasia. Like the cases presented by Mitchell et al,¹ our patient had an ectopic posterior pituitary lobe. One difference is that the pituitary stalk in our patient could not be well visualized. We are curious as to whether the etiology of this finding had a common mechanism with the other abnormalities or if this was secondary to trauma or some other cause. In addition, our patient presented with bifrontal cortical dysplasia and an ectopic strip of gray matter in the right frontal lobe. These entities are due to abnormalities in neuronal cell migration, as is periventricular heterotopia seen in all 4 of Mitchell's patients.

Thus, we support the theory that these cerebral malformations may have a common mechanism in the development of ectopic posterior pituitary lobe and suggest that they are part of a complex of features seen in septo-optic dysplasia.

References

1. Mitchell LA, Thomas PQ, Zacharin MR, et al. Ectopic posterior pituitary lobe and periventricular heterotopia: cerebral malformations with the same underlying mechanism? *AJNR Am J Neuroradiol* 2002;23:1475–81
2. Barkovich AJ, Fram EK, Norman D. Septo-optic dysplasia: MR imaging. *Radiology* 1989;171:189–92
3. Miller SP, Shevell MI, Patenaude Y, et al. Septo-optic dysplasia plus: a spectrum of malformations of cortical development. *Neurology* 2000;54:1701–03