

# Generic Contrast Agents

Our portfolio is growing to serve you better. Now you have a choice.



[VIEW CATALOG](#)

# AJNR

## **Rapid Intracranial Clot Removal with a New Device: The Alligator Retriever**

C.W. Kerber, I. Wanke, J. Bernard, Jr., H.H. Woo, M.W. Liu and P.K. Nelson

*AJNR Am J Neuroradiol* 2007, 28 (5) 860-863

<http://www.ajnr.org/content/28/5/860>

This information is current as of May 14, 2025.

## ORIGINAL RESEARCH

C.W. Kerber  
I. Wanke  
J. Bernard, Jr.  
H.H. Woo  
M.W. Liu  
P.K. Nelson

# Rapid Intracranial Clot Removal with a New Device: The Alligator Retriever

**BACKGROUND AND PURPOSE:** Despite availability of an approved drug to treat acute cerebral ischemia, most patients with stroke do not realize a good outcome. A method that would rapidly increase or restore cerebral perfusion before irreversible cell death should improve patient outcomes.

**MATERIALS AND METHODS:** We recently had the opportunity to treat 6 middle-aged-to-elderly patients who presented with signs and symptoms of acute cerebral ischemia, by mechanically removing their (predominantly) middle cerebral artery clots by using a new retrieval device that had been previously approved by the US Food and Drug Administration for intravascular retrieval of foreign bodies. During a 2-month period, the 6 patients were treated in 5 separate institutions. No patient had an unsuccessful attempt at clot removal. The cases were collected by personal communication with each operator.

**RESULTS:** In all instances, use of the device resulted in rapid clot removal. Each patient had a large improvement in National Institutes of Health Stroke Scale score. Two of the 6 patients had experienced failure of another clot retrieval device, and 3 patients required no systemic thrombolytics, reducing the likelihood of one of the most feared complications of stroke therapy, intracranial hemorrhage.

**SUMMARY:** We believe that use of this device may result in improved outcomes for patients with acute ischemic stroke. In our limited experience, it provided a rapid, safe, and effective means for achieving revascularization.

If time is brain,<sup>1,2</sup> then a device that would remove clot expeditiously and safely should lead to improved patient outcomes.

Community awareness programs have emphasized the need for rapid triage of patients with cerebral ischemia, and patients with neurologic change are tending to come to the emergency department sooner. However, even with an approved treatment, that treatment is rarely carried out. Scott<sup>3</sup> has shown that even 5 years after approval, intravenous thrombolytic therapy is given in only 1%–2% of patients with stroke in America.

More discouraging is the fact that even with recent advances in intravenous and intra-arterial thrombolytic therapy, many patients do not realize a good outcome.<sup>4</sup> This therapeutic field would welcome any improved device that could safely hasten cerebral reperfusion.

Theoretically, older clots—particularly those that come to the cerebral circulation as emboli from organized cardiac thrombus—might be more difficult to lyse than more recently formed clots. Furthermore, clots that contain large amounts of calcium and cholesterol may not lyse under any circumstance.<sup>5</sup> Thus, there is a need for rapid mechanical removal.<sup>6,7</sup>

Although the only generally accepted standard of ischemic stroke care is the intravenous administration of recombinant tissue plasminogen activator (tPA),<sup>8</sup> most patients with stroke

do not fit into the restrictive treatment guidelines. Of those who do, most still fail to benefit from the treatment. At least in part, that failure is mechanical: Unless there is blood flow to and through the offending lesion, no amount of administered thrombolytic can reach it or be expected to act on it.

We have recently used a simple grasping device that has allowed us rapidly to remove mature thrombus from cerebral vessels, and we wish to report its utility and method of use.

## Technique and Patients

We recently had the opportunity to treat 6 middle-aged-to-elderly patients who presented with signs and symptoms of acute cerebral ischemia, by mechanically removing their (predominantly) middle cerebral artery clots by using a new retrieval device. That device had been previously approved for intravascular retrieval of foreign bodies. During a 2-month period, the 6 patients were treated in 5 separate institutions. No patients had unsuccessful attempts at clot removal. The cases were collected by personal communication with each operator.

The Alligator Retrieval Device (ARD, Chestnut Medical Technologies, Menlo Park, Calif) consists of 4 small jaws mounted on a solid core shaft, which when introduced through a microcatheter with an inside diameter of at least 0.021 inches, form a 4-pronged grabbing device (Fig 1). (The US Food and Drug Administration—cleared indication for the ARD is for the retrieval of intravascular foreign bodies in the peripheral and neurovasculature.) Except for the jaws at the tip, the device has the appearance and behavior of a standard microguidewire. After the operator engages the clot, pushing the catheter forward slightly over the extended and opened prongs closes them slightly, and they grasp intraluminal foreign bodies (Fig 2).


In clinical use, a suitable microcatheter is delivered to the point of obstruction (Fig 3A–C) by using standard techniques. The ARD is then pushed a few millimeters beyond the catheter tip; this additional step allows the jaws to open (Fig 3D). The operator then advances the microcatheter minutely while not permitting wire movement; then the operator partially closes the 4 jaws and traps the clot. Both device

Received June 3, 2006; accepted after revision September 12.


From the Department of Neuroradiology (C.W.K.), University of California, San Diego Medical Center, San Diego, Calif; the Department of Neuroradiology (I.W.), University Hospital of Essen, Essen, Germany; Carolina Neurosurgery and Spine Associates (J.B.), Charlotte, NC; the Section of Cerebrovascular and Endovascular Neurosurgery (H.H.W.), Cleveland Clinic Foundation, Cleveland, Ohio; the Division of Neurosurgery (M.W.L.), Department of Surgery, Queen Mary Hospital, The University of Hong Kong, Hong Kong, China; and the Department of Radiology (P.K.N.), New York University Medical Center, New York.

J. Bernard and P.K. Nelson are stockholders in Chestnut Medical Technologies.

Please address correspondence to Charles Kerber, MD, UCSD Medical Center, 200 West Arbor Dr, San Diego, CA 92103-8756; e-mail: kaos@ucsd.edu



**Fig 1.** The jaws of the device, now fully open, protrude through a microcatheter tip. We strongly recommend that potential users lead the microcatheter first to the point of obstruction with a soft guidewire, then exchange the guidewire for the ARD, extending it just beyond the tip of the microcatheter around the thrombus.



**Fig 2.** Once the ARD is in position, we gently and smoothly push the catheter forward, slightly closing the jaws of the device over this gelatin-simulated thrombus.

and microcatheter are withdrawn a few centimeters, and contrast agent is injected through the guiding catheter to ensure that the clot has actually been trapped (Fig 3E). The entire system is then withdrawn into the internal carotid artery, down into the descending aorta, where with vigorous suction through the side arm of the rotating hemostatic valve, the clot is aspirated and delivered into the guiding catheter. Figure 3F shows an image of patient 1 immediately after clot removal.

### Reports

All procedures were performed as either lifesaving or brain-saving maneuvers. The cases accrued over a 60-day period. All patients were evaluated and treated under approved institutional guidelines. Patients 1, 3, and 6 are illustrative.

**Patient 1.** A 79-year-old European/American woman, was transferred to our hospital 7 hours following the acute onset of profound left hemiparesis that progressed to coma. Her National Institutes of Health Stroke Scale (NIHSS) score was 15. We discovered that she was in atrial fibrillation and was also on warfarin (Coumadin). Her international normalized ratio was 2.6.

During the 8th hour after her stroke, she was brought to the angiography suite, a guiding catheter was placed into her right internal carotid artery, and angiography was performed. We then placed a 0.021-inch-internal-diameter microcatheter adjacent to the clot and

directed the ARD beyond the catheter tip, allowing the jaws to open. With careful fluoroscopic control, road-mapping, and maximum magnification, we advanced the microcatheter several millimeters, partially collapsing the jaws of the device around the clot. We then brought the entire microcatheter/ARD system back 2 cm, injected contrast agent through the guiding catheter, and showed that there was good distal arterial filling and no residual clot (Fig. 3A–E).

The patient began moving her plegic side within 1 hour but developed a capsular infarct because the clot had covered a lateral lenticulostriate artery. She continued to improve on therapy, and at 30 days, her NIHSS score was 3, with only slight hand drift and left facial flattening apparent.

**Patient 3.** A 50-year-old woman developed an acutely occluded right middle cerebral artery during an attempted placement of a Neuroform stent (Boston Scientific, Natick, Mass). She received 3 mg of intra-arterial tPA immediately and was also treated with systemic cooling (body temperature dropped to 33°C). Multiple passes with a Merci retriever device (Concentric Medical, Mountain View, Calif) were unsuccessful. The first attempt at retrieval with the ARD was successful. No additional therapy was undertaken. She was discharged home the next day. NIHSS score before and after clot retrieval and recovery was zero.

**Patient 6.** A 76-year-old woman presented to the emergency department with a 1-day history of mild ataxia. She was found to be in atrial fibrillation, and while under observation, she became aphasic and right-body hemiplegic. NIHSS score was 25. Her head CT and CT perfusion study showed small recent cerebellar infarcts and a left middle cerebral artery occlusion.

Subsequent conventional angiography confirmed an occluding left M1 segment thrombus, which was removed with an ARD, re-establishing flow approximately 2.5 hours following her acute deterioration. She received no anticoagulants or thrombolytics except for heparin in the flush solutions.

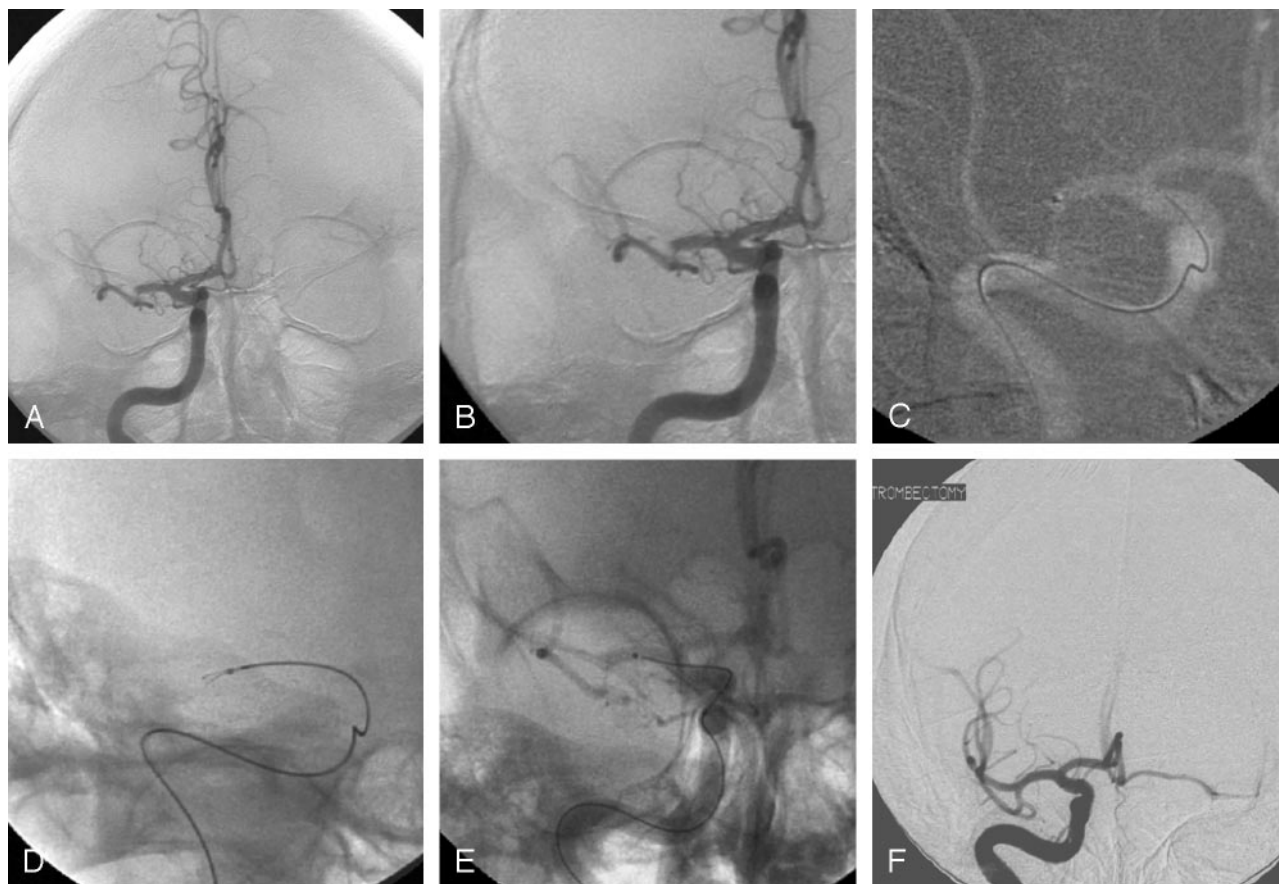
Her periprocedural course was significant for treatment of aspiration pneumonia. She was placed on warfarin (Coumadin) during week 3 following which she was transferred to a rehabilitation facility. She recovered completely from her hemiplegia but continued to have a moderate expressive dysphasia, with trace right facial weakness. Her NIHSS score at 90-day follow-up had improved to 3.

### Results

In the 1st, 5th, and 6th patients, no systemic thrombolytics were used, and mechanical removal of the clot was technically simple and rapid, resulting in complete restoration of cerebral perfusion. Our 2nd patient had failure of thrombolytics, yet rapid reperfusion occurred following removal of his clot. In patient 3, both thrombolytics and another retrieval device failed, yet despite the patient's arterial tortuosity, the clot was removed easily. The course of patient 4 was similar—after failed mechanical and thrombolytic therapy, clot extraction produced a complete recovery from an NIHSS score of 13. The improvement is summarized in the Table.

### Discussion

Despite extensive community educational efforts and the superior ability of the emergency department physicians to recognize and diagnose stroke,<sup>9</sup> there has been little change in clinical outcome following ischemic stroke treatment. What was initially reported as a significant outcome improvement after infusion of intravenous recombinant tPA<sup>8</sup> has become,



**Fig 3.** A, Frontal angiogram from patient 1. The occlusion of the distal M1 segment is apparent and, as will be seen later on the post-treatment frontal image (F), covers the most lateral lenticulostriate artery.

B, The magnified frontal working view. Images C–E are made at this working projection.

C, We place the microcatheter tip at the point of obstruction.

D, The ARD is extended 3 mm beyond the catheter tip

E, Both microcatheter and device are withdrawn about 2 cm. Injection of contrast agent shows reperfusion of the distal vessels.

F, The pretreatment angiogram (A) can be compared with the posttreatment injection. Because the striate artery was covered, the patient developed a small capsular infarction.

Patient data					
Patient	Age	Hours since ictus	Pre-NIHSS	Post-NIHSS	Comment
1	79	8	15	3	No thrombolytic used
2	84	4	16	na	Though neurologically improved, patient died later of systemic causes
3	50	1	0	0	Another retriever device failed
4	80	2	13	0	Another retriever device failed
5	54	4	14	1	No thrombolytic used
6	76	2.5	25	3	No thrombolytic used

**Note:**—NIHSS indicates National Institutes of Health Stroke Scale; na, not applicable.

on closer examination, a treatment that has not lived up to its original promise. The results in both the ECASS II<sup>10</sup> and ATLANTIS trials<sup>11</sup> showed outcomes that have not replicated the NINDS results.<sup>8</sup> Furthermore, in the original NINDS trial, more than 19 of 20 patients did not satisfy entry criteria, and of those who were treated, there was only a 12% absolute (32% relative) number of patients who completed the study with minimal or no disability. Viewed in another way, 88% (or 68%) did not improve. When all the variables are considered, we must suspect that some 95% of patients with ischemic stroke are not effectively treated.

There is another problem with the tPA protocol. Patient

evaluation shows improvement in outcomes only at the 3-month follow-up examination. Thus, in many centers, patients who do not immediately improve receive no further therapy. Opportunity for clot removal and restoration of perfusion is thus lost. Any attenuated middle cerebral artery is an ominous finding, a finding that predicts poor clinical outcome, especially death.<sup>12,13</sup> This group of patients has been shown to respond poorly to intravenous tPA.<sup>13</sup> We believe it is this group of patients who would most likely benefit from an invasive procedure. In fact, all of our patients had major clot in the middle cerebral artery, and all improved.

We learned valuable lessons with these patients. The first



was in the decision-to-treat process. Although systemic antiplatelet drugs such as abciximab (ReoPro) likely aid in the reperfusion process, a more rapid decision to remove thrombus mechanically appears to be warranted, rather than waiting for the effects of antiplatelet drugs or plasminogen activators, particularly because the restoration of flow can serve to carry thrombolytic to perfusion territories occluded by secondary more recent clot. Second, the technical aspects of clot removal appear relatively simple with this device. Essentially a modified guidewire compatible with current catheters, this device should be able to reach most clots provided they can be accessed with a microcatheter. Gently butting the delivery microcatheter against the obstruction (that position determined by subtraction angiography) allows accurate placement of the prongs of the retrieval device. A partial collapse of that retrieval device avoids fragmenting the clot. Removing the microcatheter, device, and clot proximally a few centimeters and then checking for contrast agent runoff saves considerable time, allowing the operator to make a rapid decision about whether the clot is trapped or whether another capture attempt is needed. Finally, Because clots tend to fragment as they are drawn into the guiding catheter, we recommend bringing the entire system into the descending aorta before attempting to bring the embolus back into the guiding catheter, only then vigorously aspirating the guiding catheter through the rotating hemostatic valve as the ARD, clot, and microcatheter are pulled into the guiding catheter.

The ARD engages the clot from the proximal side of the obstruction. This obviates moving beyond the clot with a microcatheter and wire into ischemic and poorly visualized distal vasculature and should simplify the removal of the clot and may offer safety advantages as well.

The downside risk of any device introduced into the cerebral circulation is that of vessel perforation. Although we have found this device relatively simple to use, adequate care, training, and proficiency in intracranial vascular navigation is the first and essential requirement for the use of this device.

If time is indeed brain—a truism often repeated by workers in this field—then the fastest safe means of re-establishing cerebral perfusion should yield the greatest clinical benefit. We understand that we have not touched on the problem of patient selection, believing that those guidelines are yet in evolution, especially as demonstrated by our 1st patient, who was more than 8 hours from onset of her stroke.

Ideally, one would perform a blinded prospective study to evaluate the efficacy of any new device, but at this early stage, we must rather depend on our clinical judgment to choose between competing devices—or even whether to remove clot at all. Proper patient selection techniques continue to evolve

and will undoubtedly reveal the patient population that can most benefit from acute revascularization in the setting of stroke. On an intellectual level, one always prefers blinded scientific analysis, but in the case of evolving technology, that approach is often inappropriate and counterproductive.

Research efforts in the treatment of acute ischemic stroke are, unfortunately, weighted in the direction of a search for the magic bullet. A look at grants underway on the NINDS Web-site shows more than 200 directed toward drug treatment but only a half-dozen related to endovascular intervention. We hope to change that paradigm, and with devices such as the ARD, which are intuitively easy to use, safe, and effective, we are 1 step closer to our goal.

## Summary

Use of this device may result in improved outcomes for patients with an acute ischemic stroke. In our limited experience, it provided a rapid, safe, and effective means for achieving revascularization.

## References

1. Brott TG, Haley EC Jr, Levy DE, et al. **Urgent therapy for stroke. Part I. Pilot study of tissue plasminogen activator administered within 90 minutes.** *Stroke* 1992;23:632–40
2. Haley EC Jr, Levy DE, Brott TG, et al. **Urgent therapy for stroke. Part II. Pilot study of tissue plasminogen activator administered 91–180 minutes from onset.** *Stroke* 1992;23:641–45
3. Scott P. **Management of acute ischemic stroke.** *Semin Respir Crit Care Med* 2002;23:69–81
4. Devuyst G, Bogousslavsky J. **Recent progress in drug treatment for acute ischemic stroke.** *Cerebrovasc Dis* 2001;11(suppl 1):71–79
5. Halloran JL, Bekavac I. **Unsuccessful tissue plasminogen activator treatment of acute stroke caused by a calcific embolus.** *J Neuroimaging* 2004;14:385–87
6. Kerber CW, Bair JD, Berger RM, et al. **Snare retrieval of intracranial thrombus in patients with acute stroke.** *J Vasc Interv Radiol* 2002;13:1269–74
7. Chopko BW, Kerber C, Wong W, et al. **Transcatheter snare removal of acute middle cerebral artery thromboembolism: technical case report.** *Neurosurgery* 2000;46:1529–31
8. **Tissue plasminogen activator for acute ischemic stroke: The National Institute of Neurological Disorders and Stroke rt-PA Stroke Study Group.** *N Engl J Med* 1995;333:1581–87
9. Kothari RU, Brott T, Broderick JP, et al. **Emergency physicians: accuracy in the diagnosis of stroke.** *Stroke* 1995;26:2238–41
10. Hacke W, Kaste M, Fieschi C, et al. **Randomised double-blind placebo-controlled trial of thrombolytic therapy with intravenous alteplase in acute ischaemic stroke (ECASS II): Second European-Australasian Acute Stroke Study Investigators.** *Lancet* 1998;352:1245–51
11. Clark WM, Wissman S, Albers GW, et al. **Recombinant tissue-type plasminogen activator (Alteplase) for ischemic stroke 3 to 5 hours after symptom onset: The ATLANTIS Study—a randomized controlled trial. Alteplase Thrombolysis for Acute Noninterventional Therapy in Ischemic Stroke.** *JAMA* 1999;282:2019–26
12. Tomsick T, Brott T, Barsan W, et al. **Thrombus localization with emergency cerebral CT.** *AJNR Am J Neuroradiol* 1992;13:257–63
13. Tomsick T, Brott T, Barsan W, et al. **Prognostic value of the hyperdense middle cerebral artery sign and stroke scale score before ultraearly thrombolytic therapy.** *AJNR Am J Neuroradiol* 1996;17:79–85