

Generic Contrast Agents

Our portfolio is growing to serve you better. Now you have a *choice*.



FRESENIUS
KABI

[VIEW CATALOG](#)

AJNR

Neuroimaging Clinics: Molecular Neuroimaging, Vol. 16, No. 4

AJNR Am J Neuroradiol 2008, 29 (1) 207

doi: <https://doi.org/10.3174/ajnr.A0732>

<http://www.ajnr.org/content/29/1/207.2>

This information is current as
of May 11, 2025.

BOOK REVIEWS

Section Editor: Robert M. Quencer

Neuroimaging Clinics: Molecular Neuroimaging, Vol. 16, No. 4

D. Schellingerhout, guest ed. Philadelphia: W.B. Saunders; 2006. 172 pages.

Take a step into the future of molecular imaging in neuroradiology with a copy of the November 2006 issue of *Neuroimaging Clinics of North America*.

Chapters chosen by guest editor Dawid Schellingerhout include Opioid Imaging, Dopamine Imaging, Brain PET, MR Spectroscopy, Diffusion Imaging Related to Cell Architecture, Optical Imaging, Tracking of Cell- and Viral-Based Therapies, and Current/Future Clinical Trials. What makes this issue of the *Clinics* interesting is that it compiles, in 1 cover, the forefronts of molecular imaging, so for one wondering where this field is heading, there would be no better place to start than here. Readers will then find out exactly what neuromolecular imaging is and what subjects fall under its domain. It is clearly a discipline that takes us beyond the commonly recognized imaging of molecular events such as positron-emission tomography (PET), MR spectroscopy, and diffusion imaging.

To me, it is unfortunate but perhaps inevitable (because of the immaturity of the science) that many of the diseases described in various chapters are unaccompanied by imaging. For instance, in the chapter on dopamine imaging, descriptions of changes expected in Parkinson disease and seeing how Parkinson's could differ from multisystem atrophy or progressive supranuclear palsy are not demonstrated, only described. In a similar fashion, descriptions of alterations in psychiatric disorders such as schizophrenia, depression, attention deficit hyperactivity disorder, drug abuse, etc, are only discussed, not shown. The chapter on single-photon emission CT and PET of multidrug-resistant P-glycoprotein describes in detail the pharmacologic and biochemical bases of this glycoprotein but gives no clinical imaging. In essence, the first 75 pages are long on the basic science of molecular imaging and will, in all likelihood, be read by just those with a deep interest in the foundations of molecular imaging.

It is when the book reaches its halfway point that clinical imaging appears in the chapters on PET, MR spectroscopy, and diffusion imaging. The chapter on PET reviews the detailed mechanisms of cell trapping by fluorodeoxyglucose (FDG), the various traces that can be used for PET brain imaging, and the method of quantification of the uptake relative to a healthy brain. For some reason, the images presented are small (eg, the case of a low-grade glioma studied with

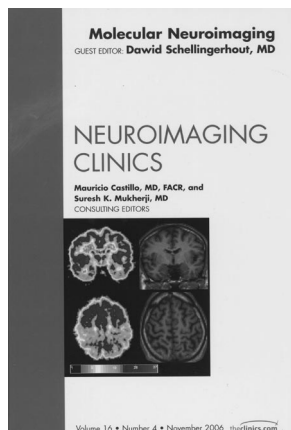
MR, ^{11}C -methionine PET, and FDG-PET). In that case, one also could take exception to the legend that the T1 gadolinium study showed no enhancement. The paucity of imaging in this chapter (just 2 cases) is disappointing.

The chapters on MR spectroscopy and diffusion imaging may strike a more practical and resonant chord with the neuroradiology community. A brief history of MR and MR spectroscopy precedes a general summary of MR spectroscopy and the importance of identifying various peaks on single- or multivoxel spectroscopy. The few clinical examples and the discussion of the spectra will be seen by the experienced neuroradiologist as basic information devoid of any new observations. In a similar fashion, the chapter on diffusion reviews the fundamentals of this technique and does so in a depth reasonable for this audience. Applications of diffusion imaging cover the well-known areas of stroke, tumor grading, and response to therapy. One concept explained in the chapter, which, perhaps, is unfamiliar to many, is "functional diffusion mapping" or fDM. This method is a novel way of assessing the alterations of a given area with time related to changing apparent diffusion coefficient (ADC) values. A nice example showing the potential of fDM is a treated tumor indicating what areas have become cystic, necrotic, or have remained stable; and possible new areas suggesting a tumor with decreased ADC values. Although not in clinical use, clearly a potential for this technique exists. The authors also demonstrate the power of high-level b-value diffusion gradients when performed on a 3T system. Here, the differentiation between edema and a solid tumor is displayed more dramatically than with standard b-values.

Optical imaging with the use of bioluminescence and fluorescence is in its infancy, with no neuroclinical applications. However, for those wanting some information on this relatively new field, extensive explanation and animal experimental models are presented in this chapter. In a similar manner, the last 2 chapters (Molecular Imaging of Novel Cell- and Viral-Based Therapies and Clinical Trials in a Molecular World) will allow the more research-minded clinician to understand where imaging and basic science may intersect and grow.

In summary, one would hope that in the next 5 years, a blossoming of molecular imaging as described in this book will allow that discipline to be incorporated into routine interpretations of brain imaging. Perhaps a future issue of *Neuroimaging Clinics of North America* will show us that.

DOI 10.3174/ajnr.A0732



BOOK REVIEW

Head and Neuroanatomy: Thieme Atlas of Anatomy

M. Schuenke, E. Schulte, U. Schumacher, L.M. Ross, E.D. Lamperti, and E. Taub, eds. Stuttgart, Germany: Thieme; 2007. 420 pages, 1182 illustrations, 72 tables, \$64.95.

This beautifully illustrated, 420-page, softcover atlas is, in fact, more (*much more*) than a neuroanatomy atlas. The