

# Generic Contrast Agents

Our portfolio is growing to serve you better. Now you have a choice.



[VIEW CATALOG](#)

# AJNR

## Spinal Imaging: Diagnostic Imaging of the Spine and Spinal Cord

*AJNR Am J Neuroradiol* 2008, 29 (7) e60-e61

doi: <https://doi.org/10.3174/ajnr.A0984>

<http://www.ajnr.org/content/29/7/e60>

This information is current as  
of May 6, 2025.

## Spinal Imaging: Diagnostic Imaging of the Spine and Spinal Cord

J.W.M. Van Goethem, L. van den Hauwe, and P.M. Parizel, eds.  
Berlin/Heidelberg, Germany, and New York: Springer; 2007, 602  
pages, 1218 illustrations including 36 in color, \$319.00.

In their preface to *Spinal Imaging: Diagnostic Imaging of the Spine and Spinal Cord*, the editors state their aim of providing a comprehensive textbook overview of diagnostic spinal imaging, replete with many illustrations and tables, while also retaining ease of use through a consistent applied logical organization throughout. In this goal, they have achieved great success. The text is not a quiz-yourself book of unknown cases or a collection of clinical vignettes. Instead, in a rather compact volume (10.7 × 7.8 inches), they have managed to include a thorough overview appropriate for the radiologist in training, as well as the depth and breadth of coverage valued in a day-to-day reference for the practicing radiologist. It will presumably be kept close by the PACS station by its owners.

The book is divided into 10 sections: “Congenital,” “Pediatric Spine,” “Biomechanics,” “Degenerative Disease,” “Trauma,” “The Postoperative Spine,” “Tumors,” “Bone Marrow,” “Infection and Inflammation,” and “Sacrum.” There are one to several chapters in each section, further dividing the major disease categories, such as tumors, into distinct yet related topics, such as intradural spinal tumors, metastatic disease of the spine, and primary tumors of the osseous spine.

The clarity of the layout of the text, figures, and table is a strength of the volume. On the first page of each chapter, there is an organized listing of the subtopics covered with page numbers. There is also a bulleted outline of key points handily located at the beginning of each chapter for quick perusal. An additional organizational feature is the very extensive subject index compiled at the book’s end. Generously distributed throughout each chapter are numerous tables displaying clinical and imaging grading criteria, imaging indications, and pulse sequence comparisons. High-quality line drawings are used when most appropriate to clarify confusing concepts, such as the nomenclature for various types of disk herniations; complex anatomy, such as the ligamentous structures of the cervicocranial junction; and the dynamic pathophysiology of instability.

Another one of the stated goals of the editors is to have the book carefully explain the controversial aspects of the role of imaging in the diagnosis of neck and low back pain, especially when many “so-called radiographic abnormalities . . . are commonly also encountered in asymptomatic individuals.”

To this end, they have included an entire chapter within the “Degenerative Disease” section on “Evidence-Based Medicine for Low Back Pain,” which provides a rigorous clinical context in which to understand the findings that we may or may not be able to identify on spinal imaging. A chapter dedicated to the “Pathology of the Posterior Elements” helps redress the overemphasis on purely diskogenic disease in the etiology of low back pain and sciatica. Spinal instability is covered in the context of imaging with an axial loading device. Although these devices are not in wide use at this time, the discussion of the dynamic pathophysiologic changes able to be studied with such imaging techniques is fascinating and provides a deeper understanding of the degenerative sequela of these frequent changes seen on routine images.

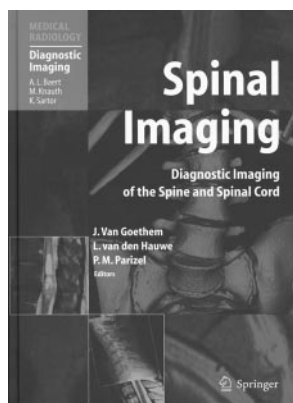
Although there were more than 40 contributors, a remarkable consistency of organization and tone is used throughout the text. The authors achieve clarity and readability by using a standard third-person textbook style throughout except in one of the surgical procedures chapters, where the author’s personal experience with innovative microsurgical techniques is shared. In addition to a reference list at the end of each chapter, the author and date of specific citations are printed along with the descriptive text rather than just as superscript notations. Rather than being distracting, it adds greater weight to the statements therein and highlights the presence of many recent citations from the early and mid-2000s.

The abundant illustrations are of outstanding quality, including a balanced variety of imaging techniques used in modern spinal imaging. Although plain film examples are used, MR imaging and CT images predominate to reflect current practice. The latest advances in volumetric multidetector CT acquisition are used in the CT imaging examples. Multiplanar reformatted images, so crucial for the obliquities relevant to spinal pathology, appear to be derived from isotropic or near-isotropic source data, lacking the “stair-step” artifact often found in imaging examples in older texts. 3D volume-rendered images are used where most illustrative, for example, in the chapter on scoliosis, though only a few are optimally displayed in color. Color plates are used effectively in the “Tumor” section, where advanced imaging techniques such as MR tractography and MR–positron-emission tomography fusion are briefly discussed.

The chapter on “Degenerative Disk Disease” is predominantly devoted to explanation and illustration of the nomenclature recommended by the combined task forces of the North American Spine Society, American Society of Spine Radiology, and American Society of Neuroradiology. Numerous well-selected MR imaging examples are included to illustrate the distinctions described in the nomenclature, as well as some of the imaging changes one encounters over time in the natural history of disk herniations.

Spinal cord pathology is given in-depth coverage in the sections on “Tumors” and “Infectious and Inflammatory Disease.”

A highlight of the book is the division of the “The Postoperative Spine” section not only into chapters detailing the early and late postoperative imaging findings but also with fairly comprehensive discussions, by neurosurgeons, on their most current surgical procedures. A chapter on “Discectomy and Herniectomy” includes discussion of the minimally invasive



procedures such as percutaneous disk decompression using coblation (nucleoplasty) and disk replacement with prosthetic disk nucleus devices. Many radiology textbooks fail to catalogue the various decompression and fusion strategies or the various instrumentation hardware used by our referring neurosurgical and orthopedic colleagues. However, the more advanced spinal imager will seek this out to attain the highest interpretative skill in the context of complicated postoperative cases, as well as to bolster rapport and credibility in consultation with our surgical colleagues. Without going into the depth of a dedicated surgical textbook, the concise and informative chapters in this text will be useful for the radiologists wishing to attain greater understanding of surgical technique or needing a reference for identification of a particular type of hardware.

Given the welcome inclusion of much surgical perspective, there is a relative paucity of material on the invasive spinal techniques developed and practiced by radiologists. For example, although the features distinguishing benign from malig-

nant insufficiency fractures are well covered in the chapter on osteoporosis, there is no real discussion of the relevant preprocedural and postprocedural imaging considerations for vertebral augmentation procedures, such as vertebroplasty and kyphoplasty. Vascular pathology of the spinal cord is also only briefly addressed, with no mention of diagnostic procedures, such as conventional-catheter spinal angiography, or interventional procedures, such as embolization of spinal cord arteriovenous malformations.

Nevertheless, this book will be of great use for its intended audience of practicing radiologists requiring a well-organized and handy source for day-to-day reference when performing all of the modalities of diagnostic spinal imaging, as well as for radiologists in training looking for a comprehensive but not overwhelming approach to this broad and complex subject. I also believe that neurosurgeons, neurologists, and rheumatologists will find the quality of the discussions and illustrations of spinal disease most useful as well.

DOI 10.3174/ajnr.A0984