



Discover Generics

Cost-Effective CT & MRI Contrast Agents



FRESENIUS
KABI

WATCH VIDEO

AJNR

3D Angiographic Atlas of Neurovascular Anatomy and Pathology

AJNR Am J Neuroradiol 2008, 29 (8) e74-e75

doi: <https://doi.org/10.3174/ajnr.A0987>

<http://www.ajnr.org/content/29/8/e74>

This information is current as
of June 23, 2025.

3D Angiographic Atlas of Neurovascular Anatomy and Pathology

N.M. Borden. New York: Cambridge University Press; 2007, 273 pages, 593 illustrations, \$124.47.

This sleek, 8.5 × 11-inch, 273-page *3D Angiographic Atlas of Neurovascular Anatomy and Pathology*, constructed by Neil M. Borden, is exactly what it portends to be: the only dedicated compendium of 3D radiographic neurovascular anatomy and pathology. Dr Borden is first introduced in the forward by Dr. Robert F. Spetzler to be a neurointerventional neuroradiologist with immense experience who, as a resident, had “gained the reputation of being a walking radiology encyclopedia and a sponge for knowledge.” Dr. Borden, having spent time in private practice, returned to academia for further neurointerventional training at the Barrow Neurologic Institute in Phoenix, Ariz. Dr. Borden describes this book as the culmination of “8 years of archiving and cataloging angiographic images.” In the introduction, the author asserts his belief that 3D rotational angiography (3DRA) is superior to 2D digital subtraction angiography (2D DSA); however, it remains more useful as an adjunct rather than as a replacement. His desire to author this book stems from his belief that the ability to better perceive normal and pathologic anatomy leads one to “the most appropriate recommendations regarding prognosis and potential interventions,” whether they be “conservative management, traditional surgery, and/or endovascular surgery.”

Each chapter begins with its own short introduction and then progresses rapidly to the stunning comparison of 2D DSA and 3DRA images. This mini-atlas starts first with the aortic arch, progressing to the cervical carotids, transitioning to the intracranial internal carotid arteries, leading to the circle of Willis, the major tributaries of the anterior intracranial arterial system, and then depicts the posterior arterial system in exquisite fashion. It then finishes with several revealing illustrations that exhibit the intracranial venous system as it drains from the cerebral veins, into the sinuses, and out through the jugular foramina. Dr. Borden, overall, exhibits a multitude of both normal and pathologic neurovascular examples in a step-wise fashion that flows logically.

Dr. Borden succinctly introduces the concept and technique of 3D rotational angiography and demonstrates how, in many ways, it is superior to 2D conventional angiography. The patient is positioned on the angiographic table, and a trial run is first initiated to ensure that the patient is within the isocenter of the imaging apparatus. He goes on to describe how the C-arm rotates approximately 220° during a typical 15-mL contrast injection, allowing

acquisition of all of the necessary images in only 5 seconds. These images may be obtained during either the arterial or venous phase. The delay for these image acquisitions is planned based on estimation from previous 2D DSA angiographic sequences. The data are sent to a 3D workstation and constructed into 512 × 512 matrix images with the desired number of reconstruction algorithms.

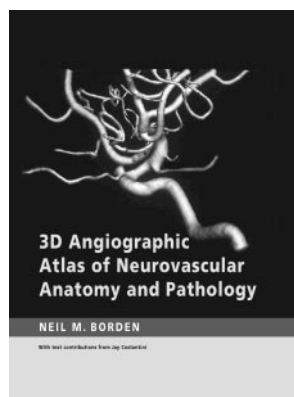
Dr. Borden included a section on anatomic illustrations in chapter 2, rendering the vascular system of the head and neck. These were provided as reprints from the Cleveland Clinic Foundation. These illustrations provide an excellent background and review before interpretation of subsequent 3DRA images in the following chapters. The numbering system for labeling of the neurovascular anatomy chosen for the figures does not flow particularly well, which may represent an underlying theme from the Cleveland Clinic Foundation’s anatomic collection that is not retained in the text. The selections, however, serve their purpose to prepare the reader for the upcoming 3DRA cases.

Chapter 3 presents the aortic arch in a cursory fashion; however, it may have been included for the sake of completeness. Although this is a neurovascular atlas, an expanded section here would assist the neurointerventionalist in preparing for a few of the common anatomic variants and pathologic entities often encountered during the access phase of neuroangiographic procedures. Expansion of this chapter is anticipated to be included in the second edition.

Dr. Borden does an excellent job in chapter 4 of elegantly detailing normal and abnormal common carotid, carotid bifurcation, cervical internal carotid artery, external carotid artery (ECA), ECA ramifications, and vertebral arteries. He accomplishes this by comparing 3DRAs with multiple 2DSA acquisitions, with which the typical reader has more experience. His approach is superb, as he presents just enough redundancy for adequate learning with a thorough and sensibly numbered labeling system. He presents stenosis, occlusion, fibromuscular dysplasia, arteriovenous fistula, plaque, ulceration, glomus tumor, and aneurysm, along with other examples.

Chapter 5 is yet another thorough composite of 3DRAs compared with 2D DSA images. Dr. Borden depicts the intracranial anterior circulation in an engaging fashion, enough to interest even a seasoned neurointerventionalist, while also thoroughly educating the budding neuroradiologist. The anatomic detail is splendid, and the methodical labeling ensures seamless correlation. This section presents anatomic variants such as hypoplastic anomalous vessels, A1 segments, early bifurcations of the middle cerebral artery, and infundibula. He also demonstrates a plethora of subtle, obvious, and multiple aneurysms in various anterior intracranial locations, including the carotid siphon, ophthalmic, circle of Willis berry, saccular, giant, and lobulated locations. Examples of coiled and clipped aneurysms are also exhibited. Arteriovenous malformations are displayed as well and include arterial conduits, nidus, and draining veins.

Chapter 6 begins with a refresher text, followed by excellent case examples that convey the superiority of 3DRA to 2D DSA, while at the same time demonstrating how the studies complement each other. He first shows normal anatomy and then transitions to normal variants, such as dominance, persistent



fetal circulation, duplicated arteries, hypoplasia, and fenestrations. He then transcends into pathology such as anterior inferior cerebellar artery aneurysms, arteriovenous malformations, atherosclerotic disease, arteriosclerotic disease, ulcerated plaques, and stenoses.

Chapter 7 proceeds with a brief background on the intracranial venous system and then compares several 3DRA acquisitions to 2D conventional DSAs. Dr. Borden emphasizes the regular variance in venous anatomy, particularly of the posterior cranial fossa. He then presents examples of venous pathology, including cavernous malformations and developmental venous anomalies.

The circle of Willis is introduced in the eighth chapter with text, though no images are included, leaving the reader for want of closure. One may simply page back to chapter 5, however, to gain a 3DRA appreciation for this portion of the anterior circulation.

The index is a welcome and useful adjunct to the book, because it allows the reader to quickly refer to anatomy of

interest during a particularly difficult “read out” or simply to refresh the reader on important neurovascular anatomy. This section will obviously become extremely valuable for reference to specific examples after one has completed a first read of the book.

After being presented with this multitude of cases illuminating normal neurovascular anatomy, anatomic variants, and examples of pathology, the reader is not only more confident with future interpretation and procedural acumen using 3DRA but is genuinely excited to initiate a scan as soon as possible. This *3D Angiographic Atlas of Neurovascular Anatomy and Pathology* is not only an excellent learning tool for the resident and fellow, refresher for general radiologists, and reference for the astute neurovascular imager and neurointerventionalist, it is, more importantly, the only complete dedicated book in its class. This book will serve you and your colleagues well and is recommended as the best 3DRA neurovascular source available.

DOI 10.3174/ajnr.A0987