



Ethanol Embolization of Auricular Arteriovenous Malformations: Preliminary Results of 17 Cases

L.Z. Zheng, X.D. Fan, J.W. Zheng and L.X. Su

AJNR Am J Neuroradiol 2009, 30 (9) 1679-1684

doi: <https://doi.org/10.3174/ajnr.A1687>

<http://www.ajnr.org/content/30/9/1679>

This information is current as
of July 3, 2025.

L.Z. Zheng
X.D. Fan
J.W. Zheng
L.X. Su

Ethanol Embolization of Auricular Arteriovenous Malformations: Preliminary Results of 17 Cases

BACKGROUND AND PURPOSE: Because of the relatively rare and extremely varied clinical presentations, arteriovenous malformations (AVMs) involving the auriculae are technically challenging clinical entities to diagnose and, ultimately, manage. The purpose of our study was to present our initial experience of ethanol embolization in a series of 17 patients with auricular AVMs and assess the interim therapeutic outcomes of this method.

MATERIALS AND METHODS: Our study group consisted of 17 patients. Transcatheter arterial embolization and/or direct percutaneous puncture embolization were performed. Pure or diluted ethanol was manually injected. Follow-up evaluation was obtained on the basis of physical examination and angiography at 3- to 4-month intervals and telephone questionnaire at 1-month intervals in all patients.

RESULTS: During the 29 ethanol embolization procedures, the amount of ethanol used ranged from 4 to 65 mL. The obliteration of ulceration, hemorrhage, pain, infection, pulsation, and bruit in most of the patients was obtained. The reduction of redness, swelling, and warmth was achieved in all of the patients, and 15 of the patients achieved downstaging of the Schobinger status. According to the angiographic findings, AVMs were devascularized 100% in 3 patients, 76% to 99% in 5 patients, 50% to 75% in 6 patients, and less than 50% in 3 patients. The most common complications were reversible necrosis and blister.

CONCLUSIONS: Ethanol embolization has proved efficacious and safe in the treatment of auricular AVMs and has the potential to be accepted as the primary mode of therapy in the management of these lesions.

Arteriovenous malformations (AVMs) involving the auriculae are technically challenging clinical entities to diagnose and, ultimately, manage. Because of the relatively rare and extremely varied clinical presentations, which can range from an asymptomatic birthmark to a life-threatening condition, it is difficult to develop sufficient experience for a learning curve of diagnosis and optimal treatment of the lesions.¹⁻⁵

At present, it is widely accepted that, for symptomatic auricular AVMs, complete excision with previous embolization is the treatment of choice.^{1-3,6-9} Total amputation, which requires a wide-field resection of all of the involved tissue, is necessary to prevent recurrence, but the cosmetic and functional issues might limit the extent to which tissue can be removed.¹⁰ As the discipline of interventional radiology develops, embolotherapy plays an ever-increasing role in the management of AVMs. However, in the management of auricular AVMs, embolization with the conventional mechanical occlusive embolic agents (*n*-butyl-2-cyanoacrylate [*n*-BCA], polyvinyl alcohol [PVA], and so on), with no subsequent surgery, is just performed in a palliative fashion in children or in patients who are not psychologically prepared for amputation.¹ The ethanol embolization of AVMs has good clinical and radiologic implications, even in the management of brain AVMs.^{4,11} In June 2007, W.F. Yakes was invited to present his clinical experience in the management of craniofacial AVMs with absolute ethanol at the Chinese National

Conference on Oral and Maxillofacial Vascular Anomalies held in Hangzhou, Zhejiang Province.¹² On the basis of the reported experience of Dr. Yakes, we began to embolize auricular AVM cases with ethanol. The purpose of our study was to present our initial experience of ethanol embolization in a series of 17 patients with auricular AVMs.

Materials and Methods

Patients


We obtained approval from the institutional review board of our hospital for a retrospective review of patient medical and imaging records. We also obtained written consent for the procedure from all patients after a discussion about the advantages and risks of the procedure. All cases of auricular AVMs embolized with ethanol at our hospital from July 2007 to October 2008 were reviewed. The study group consisted of 17 patients (11 male, 6 female) with a mean age of 25.4 years (age range, 3–47 years) at the time of treatment. Ten patients had previously undergone ligation of the proximal supplying arteries, incomplete surgical resection, and/or embolization and had their lesions deteriorate. In the remaining 7 patients, ethanol embolization was decided as the primary treatment method after full review of findings from clinical and imaging examinations of the patients.

The lesions of all the patients were first assessed at a thorough physical examination, and the patients showed multiple clinical presentations that brought them to therapy. All of the patients recalled that the lesions were present at birth, with a vascular birthmark of the ear, and gradually expanded. The patients often had more than 1 symptom and sign. The most common symptoms and signs were macrotia or swelling (all 17 patients), redness (all 17 patients), warmth (all 17 patients), pulsation/thrill (all 17 patients), and bruit (15/17 patients). Nine patients (53%) had ulceration and hemorrhage; 5 patients (29%) had pain and infection of the lesions. The obvious dilation of the external jugular vein could be found in 10

Received February 25, 2009; accepted after revision April 19.

From the Departments of Radiology (L.Z.Z., X.D.F.) and Oral & Maxillofacial Surgery (J.W.Z., L.X.S.), Ninth People's Hospital, Shanghai Jiao Tong University, Shanghai, P.R. China.

Please address correspondence to Xin Dong Fan, MD, Department of Radiology, Ninth People's Hospital, Shanghai Jiao Tong University, No. 639 Zhi Zao Ju Rd, Shanghai 200011, P.R. China; e-mail: fanxindong@yahoo.com.cn

 Indicates article with supplemental on-line table.

DOI 10.3174/ajnr.A1687

patients (59%). In 15 patients (88%), the tissue adjacent to the lesion was erythematous and edematous. Results of audiologic assessment and facial nerve function of all patients were normal and symmetric. None of the patients had vertigo, tinnitus, or conductive hearing loss. The stage of the AVMs was evaluated according to the clinical staging system described by Schobinger: stage I (quiescence): cutaneous blush/warmth; stage II (expansion): bruit, audible pulsations, expanding lesions; stage III (destruction): pain, ulceration, bleeding, infection; and stage IV (decompensation): cardiac failure.^{10,13}

To determine subsequent treatment, we performed angiography to obtain detailed anatomic and hemodynamic information about the AVMs. Selective and superselective angiography, which was performed in the same procedure as embolization, was required to accurately define the feeding arteries, draining veins, and nidus of the AVMs. The AVMs in the contiguous soft tissues were analyzed on the basis of the clinical and imaging examinations.

Embolization Technique

All procedures were performed by 2 experienced interventional radiologists (X.D.F. and L.Z.Z., with 20 and 4 years' experience in interventional radiology, respectively). Thirteen patients with 20 embolization procedures received general anesthesia with nasal intubation, and 6 patients with 9 embolization procedures received local anesthesia. The blood pressure, electrocardiogram, oxygen saturation, and end-tidal carbon dioxide levels were constantly monitored during the procedure performed with the 13 patients under general anesthesia. Also, during the procedure performed with the 6 patients under local anesthesia, the blood pressure and electrocardiogram of the patients were constantly monitored. For the patients who received general anesthesia, a Foley catheter was inserted after induction of anesthesia to monitor the state of hydration and the possible presence of hemoglobinuria.

Arteriograms of both the external carotid artery and the internal carotid artery were performed. For the patients whose external carotid artery was ligated in the previous therapies, angiograms of the common carotid artery, the vertebral artery, and the thyrocervical trunk on the ipsilateral side of the lesions, as well as the external carotid artery on the opposite side were carried out instead. To determine the detailed angioarchitecture of the AVMs, we then performed selective angiographies of the posterior auricular artery, the occipital artery, and the superficial temporal artery. The major compartments of the AVMs and endovascular accesses to those compartments were delineated.

Once the routes of endovascular access to the lesions were identified, a microcatheter (Powler10; Cordis Endovascular, Miami Lakes, Fla) was introduced into the nidus coaxially. At times, even these complex maneuvers fail, and direct puncture of the nidus may be required. The area of percutaneous puncture was prepped and draped. The 21-gauge needles were advanced by contrast injections. Superselective placement of the catheter tip or the needle tip was a requirement; only then could ethanol be injected into the nidus and all normal vascular structures spared.

Ethanol was manually injected after several arteriograms were performed to determine an appropriate volume and rate of ethanol injection on the basis of the exact flow characteristics of the AVMs. Arteriography was performed 5 to 10 minutes after each ethanol injection to determine whether thrombosis occurred. Meticulous repetition of the previously described technique was required until complete embolization of at least 1 compartment of the AVMs was achieved.¹⁴ For the AVMs with a true nidus ($n = 15$), absolute ethanol

was indicated to induce immediate thrombosis. However, in fine infiltrative microfistular AVMs ($n = 7$), diluted ethanol (50%–83%, according to the flow characteristics of the AVMs) with nonionic contrast medium was injected to achieve greater control. During direct puncture embolization, if the injected contrast was noted to leak out of the vascular nidus and form a residual stain into the surrounding healthy tissue, no more ethanol would be injected to avoid possible necrosis.

Before the procedure, all patients received an intravenous injection of dexamethasone (usually 10 mg for adults and 3–10 mg for children, depending on body weight) to control swelling and accompanying pain. For patients who received local anesthesia, block anesthesia was performed, and diluted lidocaine was given through the catheter or needle before ethanol injection to control pain. The total amount of absolute ethanol used per session was less than 1 mL/kg of body weight.^{4,5}

Postoperative management consisted of dexamethasone and intravenous infusion of fluids. Patients with gastrointestinal tract sensitivity to steroids could also be given ranitidine to protect against the development of a gastric or duodenal ulcer. Patients were usually observed in the intensive care unit overnight. The following medications usually included a tapering dose of steroids for 7 days and ranitidine management to prevent ulcer development, if required. Before patients were discharged, clinical outcome of symptoms and signs, as well as the complications, were evaluated.

Evaluation of Clinical Data and Follow-up Results

Follow-up evaluation was obtained on the basis of physical examination at 3- to 4-month intervals and telephone questionnaire at 1-month intervals in all patients (follow-up range, 1–16 months; mean, 6.5 months) after the initial procedure. Angiograms were performed in 10 patients, as required. Additional embolization was recommended if the symptoms and signs remained or if the AVMs were still present at follow-up imaging. Two radiologists (X.D.F. and L.Z.Z.) analyzed by consensus the therapeutic responses to ethanol embolization by comparing the degree of devascularization of the AVMs (ie, 100%, 76%–99%, 50%–75%, or < 50%) between baseline and final angiography results. Two oral and maxillofacial surgeons (L.X.S. and J.W.Z., with 12 and 21 years' experience in oral and maxillofacial surgery, respectively) and 1 interventional radiologist (X.D.F.) evaluated by consensus the clinical outcome of symptoms and signs, as well as the complications. When complications were observed, we reviewed the angiograms again to detect the possible cause of the complications.

Results

According to the signs and symptoms found from clinical examinations, the Schobinger stage at initial presentation was stage II in 8 patients (47%) and stage III in 9 patients (53%). The superselective angiography demonstrated that the superficial temporal artery ($n = 11$), the posterior auricular artery ($n = 8$), and the occipital artery ($n = 3$) on the ipsilateral side of the lesions were the main feeders of the AVMs. When the AVMs were large and complicated, the principal feeders also included the facial artery ($n = 2$) and the maxillary artery ($n = 1$). For patients who underwent previous ligation or embolization of the external carotid artery, the AVMs worsened with the feeders from branches of the internal carotid artery ($n = 6$), the vertebral artery ($n = 5$), the thyrocervical trunk ($n = 5$), the external carotid artery on the ipsilateral side ($n = 2$), or the

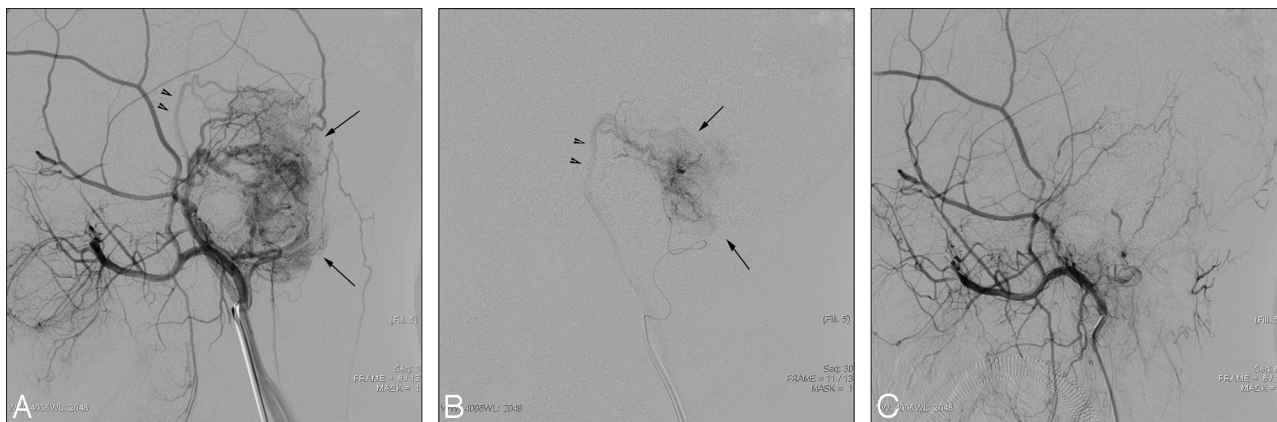


Fig 1. Patient 2, an 8-year-old girl who presented with a red pulsating mass at the right ear. *A*, Lateral DSA image shows AVMs (arrows) with dilated outflow veins (arrowheads) at the right ear. *B*, Lateral DSA image obtained before embolization, with microcatheter wedged in the nidus of the AVMs, demonstrates nidus involving concha (arrows) and immediate shunt into dilated draining vein (arrowheads). *C*, Lateral DSA image obtained 15 minutes after injection of 7.5-mL absolute ethanol reveals complete obliteration of the AVMs.

external carotid artery on the opposite side ($n = 2$). The AVMs of the superior helices were commonly supplied by the superficial temporal artery. Also, the AVMs of the central and inferior portions of the ears (ie, the concha and lobule) were mainly fed by the posterior auricular artery. For the AVMs of the posterior side of the concha and the retroauricular region, the inflow artery usually was the occipital artery. Clinical and imaging examinations revealed that the AVMs of the contiguous soft tissues were often located in the retroauricular skin ($n = 12$), cheek/parotid glands ($n = 8$), neck ($n = 9$), temporal scalp ($n = 3$), and occipital scalp ($n = 1$). In all patients, no evidence showed involvement of the mandible, the external auditory canal, or the middle and inner ear.

During the 29 ethanol embolization procedures (range, 1–4; mean, 1.7 procedures) performed in 17 patients, the amount of ethanol used ranged from 4 to 65 mL, which did not exceed 1 mL/kg of body weight in a single embolization session. Five patients with 5 embolization procedures underwent transcatheter arterial embolization only, and 12 patients with 16 embolization procedures underwent direct puncture embolization only. In the other 8 embolization procedures, 7 patients received both embolization modalities. For 1 patient (patient 8), who underwent previous ligation of the external carotid artery, transcatheter ethanol embolization was performed through the feeding branch of the vertebral artery. Transient hemoglobinuria occurred in 11 (65%) of 17 patients in a total of 19 procedures (66%) and disappeared approximately 5 to 6 hours after continuous infusion of Ringer's lactate intravenously. Seventeen patients (100%) with 29 procedures (100%) exhibited focal swelling in the area of the AVMs after the procedures, which resolved within 2 weeks.

In regard to the clinical outcome, the obliteration of ulceration (9/9 patients), hemorrhage (9/9 patients), pain (5/5 patients), infection (5/5 patients), pulsation (7/17 patients), and bruit (5/15 patients) was obtained after ethanol embolization. The alleviation of redness, swelling, and warmth was achieved in all patients. In 9 patients with Schobinger stage III lesions at initial presentation, postoperative assessment showed that 1 patient (11%) was improved to stage I and 8 patients (89%) improved to stage II. Meanwhile, 6 patients (75%) with preoperative stage II disease were improved to stage I after ethanol embolization, and the other 2 (25%) patients with preop-

erative stage II disease remained stable. According to the angiographic findings, AVMs were devascularized 100% in 3 patients (18%) (Fig 1), 76% to 99% in 5 patients (29%) (Fig 2), 50% to 75% in 6 patients (35%), and less than 50% in 3 patients (18%).

Nine (53%) of the 17 patients had 13 complications occurring in 9 procedures (31%). Four patients (24%) in 4 procedures (14%) had necrosis; 4 patients (24%) in 4 procedures (14%) had a blister; and 1 patient (6%) in 1 procedure (3%) had ulceration, which healed with wound dressing, and skin graft was not required. Singultus (hiccups) occurred in 3 patients (18%) with 3 procedures (10%); these patients recovered by the third or fourth day. The results of postoperative clinical assessment and facial nerve function revealed decreased hearing in 1 patient (6%) (on-line Table). None of the patients had vertigo or tinnitus after ethanol embolization. Renal impairment as a result of hemoglobinuria did not occur during the hospital stay. According to the retrospective study of the angiograms, when complications occurred, we found that the 4 cases with necrosis were potentially related to non-target embolization or significant swelling of the focal areas secondary to an overaggressive embolization (Fig 3).

Discussion

AVMs are congenital structural anomalies resulting from arrest in the development of or the failure of orderly resorption of primitive embryologic vascular elements.^{4,15} The central and significant feature of an AVM is the presence of a primitive vascular nidus that rapidly empties into dilated tortuous outflow veins without the presence of a normal capillary bed.⁵ In AVMs, the endothelial cells demonstrate a normal rate of cellular division and do not regress at the histologic level.^{3,15,16} The external ear is the second most common site for extracranial AVMs in the head and neck.¹ Auricular AVMs are lesions that present at birth and grow commensurately with the child. It can expand rapidly secondary to traumatic injury; surgery; and hormonal influences caused by birth control pills, puberty, or pregnancy.¹

Surgeons first treated these lesions with ligation of the proximal feeding arteries or auricular resection. Total resection of small AVMs can be achieved. However, for large and complex AVMs, complete extirpation proves very difficult,

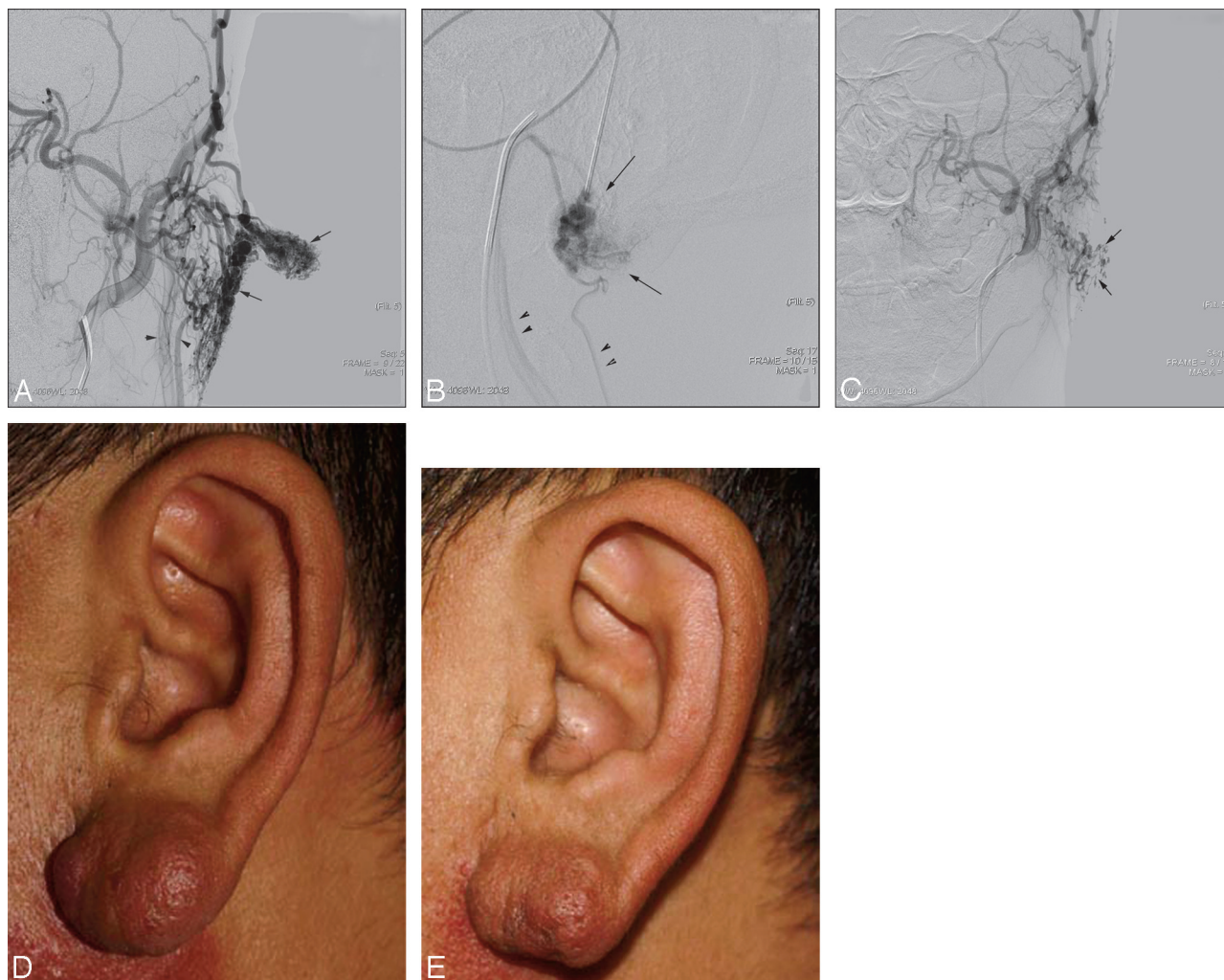

Fig 2. Patient 6, who presented with AVMs at the left ear lobule and contiguous cheek. *A*, AP arteriogram image obtained before embolization shows vascular nidus (*arrows*) around the left ear lobule and contiguous cheek, and a dilated outflow vein (*arrowheads*). *B*, Lateral DSA image obtained after direct percutaneous puncture but before embolization demonstrates filling of vascular nidus (*arrows*) and draining veins (*arrowheads*). There was 16 mL of 66% ethanol embolization that was performed at this point. *C*, Late-phase AP image obtained 7 months after the ethanol embolization shows obliteration of the AVMs around the lobule and persistent vascular hyperemia around the cheek (*arrows*); however, no arteriovenous shunt or draining veins are present. *D*, The lateral view of the left ear before treatment shows swelling and redness of the left ear lobule. *E*, The lateral view of the left ear 7 months later after treatment shows shrinkage of the swelling and darkening of redness of the left ear lobule.

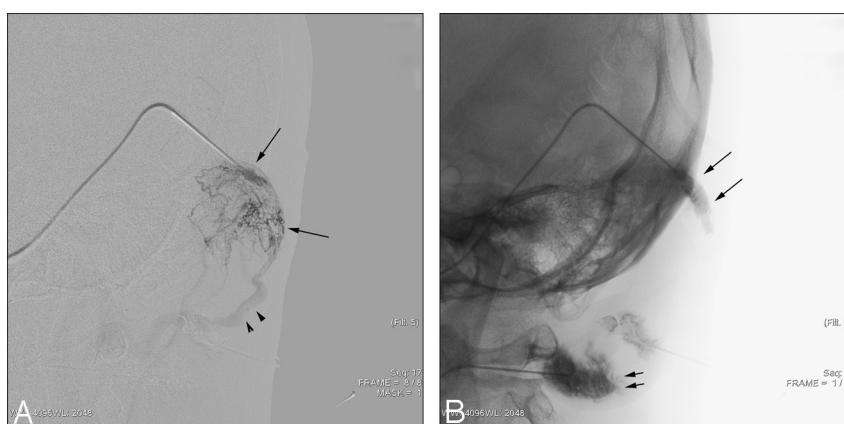

Fig 3. Patient 3, a 30-year-old man with left auricular AVMs causing ulceration and bleeding. The patient had a history of ligation of the left external carotid artery and deterioration of the lesion. Direct puncture embolization was performed to treat the AVMs, and necrosis occurred. *A*, Lateral DSA image obtained after direct percutaneous puncture demonstrates filling of vascular nidus (*arrows*) and draining veins (*arrowheads*). There was 5 mL of absolute ethanol that was injected at this point. *B*, The fluoroscopy image on the retrospective study revealed a fine residual stain of former injected contrast medium (*long arrows*) in the tissue of the superior helix under fluoroscopy performed 13 s after the angiogram showed above. The obvious residual stain of contrast in the lobule (*short arrows*) is found, ethanol injection is terminated, and no necrosis developed in the lobule.

ending in many suboptimal partial resections. However, when ligation of the proximal feeding arteries or partial resection is performed, with time, recurrent symptoms equal to or worse than the patient's primary problem can be observed because the remaining abnormal vascular elements become very aggressive.^{3-5,14,17} Although a "total resection" is achieved, a 5-year follow-up is necessary before reconstruction is performed to make certain there is no evidence of recurrence.¹

With improved catheter technology, superselective techniques, and improved embolic agents, embolotherapy now plays a significant role in the treatment of AVMs.¹⁵ The conventional mechanical occlusive embolic agents used to treat auricular AVMs are *n*-BCA, PVA, Gelfoam particles (Phadia, Uppsala, Sweden), and fibered platinum coils with gelatin sponge particles.^{1-3,6-9} Long-term follow-up has demonstrated some degree of recanalization, even when the nidus of the AVMs is completely embolized with both transcatheter arterial and direct puncture embolization techniques.¹ The main reason for recanalization and neovascular recruitment phenomenon occurring in the management of AVMs is that all of the embolic agents mentioned above do not completely destroy the endothelial cells of the AVMs, which may sense decreased oxygen tension, send out the angiogenesis factors that stimulate neovascular formation, and the chemotactic matters that cause a cellular infiltration to carry debris from the vascular channels.⁵ In the traditional sense, in the management of auricular AVMs, embolization is used only as a preoperative devascularization measure to provide a dry operative field or as palliative treatment in patients who have no indications for an auricular amputation.¹

Ethanol embolotherapy has proved to be curative, even in complex AVMs, by a combination of a direct toxic effect on the vascular wall and clumping of damaged erythrocytes and denatured proteins, which result in the complete obliteration of the vessel lumen.^{4,18,19} Injecting ethanol into the nidus of the AVMs denatures blood proteins, dehydrates vascular endothelial cells and precipitates their cytoplasm, denudes the vascular wall totally of endothelial cells, and segmentally fractures the vascular wall to the level of the internal elastic lamina.^{5,19-22} In addition, acute thrombus formation is promoted by vascular spasm and perivascular necrosis.²³ Compared with other embolic agents, ethanol has many attractive properties for use in AVM management. First, as a liquid long-acting embolic material, ethanol can pass to and occlude the primitive vascular nidus. Second, it is inexpensive and easy to administer.^{15,24} Moreover, ethanol is a sclerosing agent whose metabolism and excretion in humans is well known.^{5,22,25} Because ethanol completely destroys the endothelial cells, the phenomena of recanalization and neovascular recruitment are noticeably absent. The therapeutic goal of ethanol embolotherapy is to ablate all or part of an AVM until the desired clinical result is achieved.¹⁴

Ethanol treatment of auricular AVMs requires significant experience with the agent, as well as extreme caution and a complete understanding of the pathophysiology of the lesion being treated. During an embolization procedure, ethanol is directed against the abnormal vascular nidus, not the inflow artery or outflow vein, to prevent complications of inadvertent nontarget embolization.^{14,15} The internal carotid artery, which supplies the external auditory canal and tympanic

membrane, communicates with the external carotid artery along the walls of the auditory canal.⁶ These potential communications are of clinical importance in that they may open and lead to nontarget embolization when vascular occlusion techniques, which change the normal hemodynamics of the AVMs, are performed. In the management of small and localized AVMs, a single embolization procedure may be sufficient. However, large and complex lesions should usually be treated in a multistage procedure to reduce the risk for too extensive an embolization in a single session.^{14,15}

Ethanol embolization of auricular AVMs is, we believe, now the preferred technique for the management of these extremely complex and challenging lesions. It has shown promise in the obliteration or alleviation of the symptoms associated with the auricular AVMs, such as ulceration, hemorrhage, pain, infection, pulsation, bruit, redness, swelling, warmth, and so on. In the treatment of auricular AVMs, ethanol embolization has demonstrated its curative potential and avoids disfigurement caused by surgical auricular amputation. Because ethanol is successfully used as an embolic agent to treat auricular AVMs, the value of surgical auricular ablation should be reassessed.

The injudicious or inappropriate use of ethanol is most hazardous because the agent necessary to produce a cure can also produce severe complications.¹¹ Currently, in our series, the overall complication rate of auricular AVM ethanol embolization was 31%, and the most common complications were necrosis, ulceration, blister, singultus (hiccups), and decreased hearing, with most of these complications being self-limited and reversible. In our study, all complications were observed within 1 week after embolization, and no additional complications were detected during the follow-up. Complications of ethanol embolization mainly result from local tissue injuries related to nontarget embolization of normal capillary beds and the systemic effect related to the increase of serum ethanol levels caused by ethanol contamination.^{4,20,22} In most institutions, the maximal volume of ethanol used in treating patients with AVMs is 1.0 mL/kg body weight on the basis of clinical experience.^{4,5,20,21,23,26} However, the safety of this dose has not been confirmed. It was reported that idiosyncratic reactions may occur with the use of as little as 1.0 mL of ethanol.²⁷ In selected cases, a pulmonary artery catheter is recommended to constantly monitor pulmonary artery pressure during injection of ethanol. However, a pulmonary artery catheter was not used in our study group because of its invasiveness and high cost. To control pain, sedation or general anesthesia is usually performed and selective injection of an anesthetic (lidocaine) into the vascular territory to be embolized has also proved to be helpful. Sometimes, necrosis may be observed related to significant swelling of the focal areas secondary to overaggressive embolization. Good immediate postoperative care, including appropriate use of medication to reduce sequelae of any adverse effects, is necessary.

Conclusions

Our preliminary results of ethanol embolization in 17 patients with auricular AVMs illustrates that when it is performed according to strict techniques, ethanol embolotherapy has proved to be efficacious and safe in the treatment of auricular AVMs and avoids disfigurement caused by auricular amputa-

tion. Ethanol embolization has the potential to be accepted as the primary mode of therapy in the management of auricular AVMs. Additional follow-up is necessary to evaluate the long-term efficacy and safety of this treatment technique.

References

1. Wu JK, Bisdorff A, Gelbert F, et al. **Auricular arteriovenous malformation: evaluation, management, and outcome.** *Plast Reconstr Surg* 2005;115:985–95
2. Shinohara K, Yamashita M, Sugimoto K, et al. **Transcatheter arterial embolization of auricular arteriovenous malformation.** *Otolaryngol Head Neck Surg* 2005;132:345–46
3. Pham TH, Wong BJ, Allison G. **A large arteriovenous malformation of the external ear in an adult: report of a case and approach to management.** *Laryngoscope* 2001;111:1390–94
4. Do YS, Yakes WF, Shin SW, et al. **Ethanol embolization of arteriovenous malformations: interim results.** *Radiology* 2005;235:674–82
5. Yakes WF, Rossi P, Odink H. **How I do it. Arteriovenous malformation management.** *Cardiovasc Intervent Radiol* 1996;19:65–71
6. Bapuraj JR, Bilwani R, Khandelwal N, et al. **Pre-operative embolization of auricular arteriovenous fistula.** *J Laryngol Otol* 2002;116:42–45
7. Ashinoff R, Berenstein A, Geronemus RG. **Arteriovenous malformation treated with embolization and laser therapy.** *Arch Dermatol* 1991;127:1642–44
8. Aslan S, Yavuz H, Cagici AC, et al. **Embolisation of an extensive arteriovenous malformation of the temporal region as an alternate treatment: case report.** *J Laryngol Otol* 2008;122:737–40
9. Woo HJ, Song SY, Kim YD, et al. **Arteriovenous malformation of the external ear: a case report.** *Auris Nasus Larynx* 2008;35:556–58
10. Meher R, Varshney S, Pant HC. **Arteriovenous malformation related to the pinna.** *Hong Kong Med J* 2008;14:157–59
11. Yakes WF, Krauth L, Ecklund J, et al. **Ethanol endovascular management of brain arteriovenous malformations: initial results.** *Neurosurgery* 1997;40:1145–54
12. Yakes WF. **Endovascular management of high-flow arteriovenous malformations.** *Chinese J Stomatol* 2008;43:327–32
13. Kohout MP, Hansen M, Pribaz JJ, et al. **Arteriovenous malformations of the head and neck: natural history and management.** *Plast Reconstr Surg* 1998;102:643–54
14. Yakes WF, Luetbke JM, Parker SH, et al. **Ethanol embolization of vascular malformations.** *Radiographics* 1990;10:787–96
15. Yakes WF, Haas DK, Parker SH, et al. **Symptomatic vascular malformations: ethanol embolotherapy.** *Radiology* 1989;170:1059–66
16. Mulliken JB, Glowacki J. **Hemangiomas and vascular malformations in infants and children: a classification based on endothelial characteristics.** *Plast Reconstr Surg* 1982;69:412–22
17. Kojima Y, Kano Y. **Arteriovenous malformation with auricular hypertrophy.** *ORL J Otorhinolaryngol Relat Spec* 1995;57:224–27
18. Yakes WF, Pevsner P, Reed M, et al. **Serial embolization of an extremity arteriovenous malformation with alcohol via direct percutaneous puncture.** *Am J Roentgenol* 1986;146:1038–40
19. Buchta K, Sands J, Rosenkrantz H, et al. **Early mechanism of action of arterially infused alcohol U.S.P. in renal devitalization.** *Radiology* 1982;145:45–48
20. Hammer FD, Boon LM, Mathurin P, et al. **Ethanol sclerotherapy of venous malformations: evaluation of systemic ethanol contamination.** *J Vasc Interv Radiol* 2001;12:595–600
21. Mason KP, Michna E, Zurakowski D, et al. **Serum ethanol levels in children and adults after ethanol embolization or sclerotherapy for vascular anomalies.** *Radiology* 2000;217:127–32
22. Takebayashi S, Hosaka M, Kubota Y, et al. **Transarterial embolization and ablation of renal arteriovenous malformations: efficacy and damages in 30 patients with long-term follow-up.** *J Urol* 1998;159:696–701
23. Lee JJ, Do YS, Kim JA. **Serum ethanol levels after alcohol sclerotherapy of arteriovenous malformations.** *J Korean Med Sci* 2004;19:51–54
24. Takebayashi S, Hosaka M, Ishizuka E, et al. **Arteriovenous malformations of the kidneys: ablation with alcohol.** *Am J Roentgenol* 1988;150:587–90
25. Huang MS, Lin Q, Jiang ZB, et al. **Comparison of long-term effects between intra-arterially delivered ethanol and Gelfoam for the treatment of severe arterioportal shunt in patients with hepatocellular carcinoma.** *World J Gastroenterol* 2004;10:825–29
26. Shin BS, Do YS, Lee BB, et al. **Multistage ethanol sclerotherapy of soft-tissue arteriovenous malformations: effect on pulmonary arterial pressure.** *Radiology* 2005;235:1072–77
27. Stefanutto TB, Halbach V. **Bronchospasm precipitated by ethanol injection in arteriovenous malformation.** *AJNR Am J Neuroradiol* 2003;24:2050–51