



Discover Generics

Cost-Effective CT & MRI Contrast Agents



WATCH VIDEO

AJNR

Intervention versus Aggressive Medical Therapy for Cognition in Severe Asymptomatic Carotid Stenosis

C.-J. Lin, F.-C. Chang, K.-H. Chou, P.-C. Tu, Y.-H. Lee, C.-P. Lin, P.-N. Wang and I.-H. Lee

This information is current as of June 5, 2025.

AJNR Am J Neuroradiol 2016, 37 (10) 1889-1897

doi: <https://doi.org/10.3174/ajnr.A4798>

<http://www.ajnr.org/content/37/10/1889>

Intervention versus Aggressive Medical Therapy for Cognition in Severe Asymptomatic Carotid Stenosis

C.-J. Lin, F.-C. Chang, K.-H. Chou, P.-C. Tu, Y.-H. Lee, C.-P. Lin, P.-N. Wang, and I.-H. Lee



ABSTRACT

BACKGROUND AND PURPOSE: Asymptomatic carotid stenosis of $\geq 70\%$ increases the incidence of microembolism and/or chronic hypoperfusion, which may consequently impair neurocognition and brain connections. We sought controlled evidence for any cognitive benefit of aggressive medical therapy and combined carotid revascularization.

MATERIALS AND METHODS: Patients with asymptomatic, unilateral, $\geq 70\%$ stenosis of the extracranial ICA chose either aggressive medical therapy alone or in combination with carotid artery stent placement in this nonrandomized controlled study. They were examined with a battery of neuropsychological tests, structural MR imaging, DTI, and resting-state fMRI before and 3 months after treatment.

RESULTS: Forty patients were included with 15 in the medical group and 25 in the stent-placement group. Among them, 13 and 21 in the respective groups completed neuroimaging follow-up. The baseline characteristics and the changes in cognitive performance during 3 months showed no differences between treatment groups. Nevertheless, compared with the medical group, the stent-placement group showed subjective dizziness alleviation ($P = .045$) and a small increase in fractional anisotropy at the splenium of the corpus callosum and the posterior periventricular white matter ipsilateral to carotid artery stent placement. Moreover, only the stent-placement group showed interval improvement in immediate memory and visuospatial performance, which was accompanied by an increase of functional connectivity at the insular cortex of the dorsal attention network and the medial prefrontal cortex of the default mode network.

CONCLUSIONS: Both aggressive medical therapy alone and combined carotid revascularization in $\geq 70\%$ asymptomatic carotid stenosis similarly preserved cognition during 3-month follow-up, though the latter had the potential for dizziness alleviation and cognitive and connectivity enhancement.

ABBREVIATIONS: CAS = carotid artery stent placement; FA = fractional anisotropy; Fc = functional connectivity; MCI = mild cognitive impairment; VCIND = vascular cognitive impairment no dementia

Interventional revascularization for $\geq 60\%$ asymptomatic ICA stenosis has long been debated, given the decreasing annual risk of ipsilateral ischemic stroke in these patients from 2.3% to 0.5% with the development of contemporary optimal medical treatment.^{1–4} However, some of these patients carry a higher risk of

stroke than others despite optimal medical treatment. Patients with detectable embolic signals by transcranial Doppler have a high annual risk (7%) of stroke.⁵ Stenotic degree of $\geq 90\%$, poor collaterals, and echolucent plaque texture could also stratify patients into groups with varying high stroke risk to $>4\%$ annually.^{6,7} Thus, interventional revascularization should be considered in such patients. Recently, long-term randomized trials, the Asymptomatic Carotid Trial⁸ and the Carotid Revascularization Endarterectomy versus Stenting Trial (CREST)⁹ demonstrated that there was no difference in the rate of late ipsilateral stroke after carotid endarterectomy or carotid artery stent placement (CAS) in asymptomatic and symptomatic patients. Of asymptomatic patients, the 5-year cumulative rate of stroke-free survival was 93.1% in the CAS group and 94.7% in the carotid endarterectomy group.⁸

Hence, asymptomatic carotid stenosis has been viewed from a changing perspective from stroke risk to cognitive susceptibility.^{10,11} We previously demonstrated that patients with unilateral asymptomatic carotid stenosis of $\geq 70\%$ had more dizziness/

Received October 16, 2015; accepted after revision March 10, 2016.

From the Departments of Neurology (C.-J.L., P.-N.W., I.-H.L.), Radiology (F.-C.C.), and Medical Education and Research (P.-C.T.), Taipei Veterans General Hospital, Taipei, Taiwan; and Institute of Brain Science (C.-J.L., P.-C.T., I.-H.L.), Institute of Neuroscience (K.-H.C., C.-P.L.), Department and Institute of Physiology (Y.-H.L.), and School of Medicine (P.-N.W.), National Yang-Ming University, Taipei, Taiwan.

This work was sponsored by Taiwan Ministry of Science and Technology (MOST 103-2320-B-075-002, MOST 103-2314-B-075-008, MOST 104-2320-B-075-001) and the Taipei Veterans General Hospital (V103C-171, V104C-059, V105B-029) in Taiwan.

Please address correspondence to I-Hui Lee, MD, PhD, Department of Neurology, Taipei Veterans General Hospital, 201, Section 2, Shipai Rd, Beitou District, Taipei, Taiwan; e-mail: ihlee@vghtpe.gov.tw

Indicates open access to non-subscribers at www.ajnr.org

<http://dx.doi.org/10.3174/ajnr.A4798>

unsteadiness and poorer verbal memory, executive function, and visuospatial perception than the healthy controls, accompanied by extensive widespread disruption of long-range structural and functional connectivity.^{12,13} The mechanisms are likely attributed to microemboli from unstable carotid plaques⁵ and/or chronic hypoperfusion.^{14,15} Single-arm studies of carotid revascularization accomplished by either carotid endarterectomy or CAS reported the controversial results of cognitive enhancement in patients with asymptomatic carotid stenosis.¹⁵⁻²⁰ However, there is a lack of medical-controlled evidence reflecting contemporary medical improvement and risk-benefit balance of interventions for cognitive preservation. Here, we investigate the impact of aggressive medical treatment with or without combined carotid revascularization on neurocognitive and connectivity outcomes at 3 months after treatment in patients with $\geq 70\%$ asymptomatic carotid stenosis.

MATERIALS AND METHODS

Subjects, Treatment, and Neuropsychological Tests

We enrolled patients with asymptomatic, unilateral severe stenosis of the extracranial ICA at our dizziness outpatient clinic of Taipei Veterans General Hospital between March 2010 and July 2015. The inclusion criteria were between 20 and 80 years of age and ICA stenotic degree of $\geq 70\%$ identified by both duplex ultrasonography²¹ and gadolinium-enhanced MR angiography (North American Symptomatic Carotid Endarterectomy trial criteria).²² The exclusion criteria included transient ischemic attack or stroke, functional disability (modified Rankin Scale score of ≥ 3), carotid dissection, and the presence of contralateral ICA stenosis of $\geq 50\%$ and comorbidities of dementia, major depression (based on the *Diagnostic and Statistical Manual of Mental Disorders-IV*), Parkinsonism, multiple sclerosis, brain tumor, congestive heart failure (left ventricular ejection fraction $< 40\%$), chronic obstructive pulmonary disease, cirrhosis, renal failure (estimated glomerular filtration rate < 30 mL/min/1.73 m²), and malignancy. The medications of all subjects were recorded. Written informed consent was obtained from each participant before enrollment. This study was approved by the ethics committee of the Taipei Veterans General Hospital (VGHIRB No. 2012-01-016AC).

All patients received aggressive medical treatment (dual antiplatelets if tolerated or at least 1 antiplatelet, statin therapy goal of low-density lipoprotein of < 100 mg/dL, diabetes treatment goal of glycated hemoglobin level of $< 7\%$, hypertension treatment goal of systolic blood pressure of < 140 mm Hg, smoking cessation) with or without carotid revascularization treatment in a nonrandomized fashion tailored for the individual procedure and preference. For CAS, conventional angiography of the supra-aortic arteries and branches was performed by using a transfemoral arterial approach. An embolic protection device (FilterWire EX or EZ; Boston Scientific, Natick, Massachusetts) was carefully navigated through the stenotic lesion and placed in the distal cervical ICA. Then a self-expandable stent (Wallstent, Boston Scientific; or Precise; Cordis, Fremont, California) was introduced and adjusted to the dimension of the stenotic artery, followed by postdilation with a balloon of 5–6 mm in diameter. Angiography was repeated for the ICA and its intracranial branches to ensure the residual stenosis of the target site was $< 50\%$ and absence of endovascular complications.

All subjects were evaluated with a battery of neuropsychological tests before and 3 months after treatment by a blinded trained examiner, including the Dizziness Handicap Inventory,²³ the Mini-Mental State Examination, memory tests (verbal selective reminding test; an auditory verbal learning test, including total immediate recall and 15-minute delayed recall of 12 items),²⁴ executive tests (the Modified Trail-Making Test A and B²⁵; the Stroop Color and Word Test²⁶), an attention test (the Symbol Digit modalities Test),²⁷ and complex visuospatial perception tests (the Modified Complex Figure Test with Copy and Recall).

MR Imaging Acquisition

Before and 3 months after the treatment, patients were subjected to MR imaging and instructed to hold still, keep their eyes open, and think of nothing in a 3.0 Discovery 750 (GE Healthcare, Milwaukee, Wisconsin) MR imaging scanner. All images were acquired along the anteroposterior commissural plane, according to multiplanar T1-weighted BRAVO anatomical images (http://www3.gehealthcare.com/en/Products/Categories/Magnetic_Resonance_Imaging/Neuro_Imaging/BRAVO) (TR = 12.2 ms; TE = 5.2 ms; flip angle = 12°; voxel size = 1 × 1 × 1 mm; FOV = 256 × 256 mm). A series of fluid-attenuated inversion recovery sequences was acquired to rate leukoaraiosis severity. The stent-placement group received additional diffusion-weighted imaging and apparent diffusion coefficient imaging within 3 days after the procedure to exclude any periprocedural insult. For DTI, a single-shot diffusion spin-echo echo-planar imaging sequence (TR/TE = 9500/85.6 ms; thickness = 2 mm; matrix = 128 × 128; FOV = 256 × 256 mm; 30 directions) was adopted. For resting-state fMRI, the blood oxygen level-dependent signals from a task-free run (124 time points/372 seconds) of a gradient-echo echo-planar imaging sequence (TR/TE = 3000/30 ms; flip angle = 90°; FOV = 222 × 222 mm; thickness = 3 mm) were recorded.

MR Imaging Processing and Analysis

A blinded neurologist and a neuroradiologist reviewed all images. The severity of leukoaraiosis was assessed by the semiquantitative Scheltens rating scale.²⁸ The hemisphere ipsilateral to the ICA stenosis was flipped to the right side along the midsagittal plane. We analyzed T1-weighted anatomic images and manually outlined the bilateral hippocampi to calculate the hippocampal volumes of each patient^{29,30} and brain volume by using the voxel-based morphometry approach.³¹ Statistical Parametric Mapping software (SPM8; <http://www.fil.ion.ucl.ac.uk/spm/software/spm12>) was used to segment the gray and white matter intensities and normalize them to Montreal Neurological Institute space. The gray and white matter volumes were compared within each group by paired *t* tests with a threshold of $P < .05$. For DTI, voxelwise fractional anisotropy (FA) was analyzed after applying preprocessing with Tract-Based Spatial Statistics from the FMRIB Software Library (TBSS; <http://fsl.fmrib.ox.ac.uk/fsl/fslwiki/TBSS>), as previously described.¹² We performed a paired *t* test for within-group interval changes of the FA maps and then a 2-sample *t* test for between-group comparison of the interval changes with a significance set at $P < .05$ with family-wise error rate correction for multiple comparisons (random permutations, $n = 5000$).

The mean FA values of the whole brain or each hemisphere, as

Table 1: Baseline characteristics

	Med	Med+CAS	P Value
Age (yr)	68.8 ± 8.8	71.4 ± 7.8	.348
Male sex (%)	11 (73)	21 (84)	.687
Education (yr)	12 (7.5–12)	10 (7–12)	.602
Stenotic degree (%)	81.3 ± 12.0	81.0 ± 9.8	.928
Total occlusion (No.) (%)	3 (20)	0 (0)	.543
Hypertension (No.) (%)	12 (80)	20 (80)	.611
Mean BP (mm Hg)	95.1 ± 9.5	95.3 ± 10.2	.887
Diabetes mellitus (No.) (%)	7 (47)	9 (36)	.268
HbA1c (%)	6.6 ± 1.2	6.4 ± 0.4	.254
Hypercholesterolemia (No.) (%)	9 (60)	17 (68)	.444
LDL (mg/dL)	85.3 ± 20.1	89.1 ± 14.7	.851
Smoking (No.) (%)	5 (33)	9 (36)	.542
Atrial fibrillation (No.) (%)	1 (6.6)	0 (0)	.118
Double antiplatelets (No.) (%)	8 (53)	18 (72)	.345
Statins (No.) (%)	8 (53)	15 (60)	.488
Dizziness Handicap Inventory	14.7 ± 19.5	18.3 ± 13.8	.541
Mini-Mental State Examination	28.4 ± 1.2	28.2 ± 1.8	.641
Verbal memory tests			
Total immediate recall	38.3 ± 10.5	46.1 ± 7.9	.086
Delayed recall	7.3 ± 2.3	8.1 ± 2.3	.571
Attention tests			
Symbol Digit Modalities Test	45.5 ± 16.3	41.9 ± 20.1	.559
Executive function tests			
Modified Trail-Making Test A	16.4 ± 8.6	22.4 ± 15.1	.214
Modified Trail-Making Test B	43.6 ± 28.9	53.1 ± 31.1	.455
Stroop Color and Word Test	33. ± 13.4	32.9 ± 14.6	.819
Complex visuospatial perception			
Complex Figure Test (Copy)	16.4 ± 1.2	15.5 ± 1.8	.109
Complex Figure Test (Recall)	10.4 ± 4.5	9.7 ± 4.2	.631
MCI/VCIND (No.) (%)	6 (40%)	7 (28%)	.318
Scheltens leukoariosis score	5.2 ± 2.7	5.4 ± 3.1	.889
Hippocampal volume (mL)	3.3 ± 0.3	3.2 ± 0.2	.533
Ipsilateral hemispheric FA	0.50 ± 0.01	0.49 ± 0.01	.471
Contralateral hemispheric FA	0.51 ± 0.01	0.50 ± 0.01	.375

Note:—Med indicates medical therapy alone; Med+CAS, medical therapy combined with carotid artery stent placement; BP, blood pressure; LDL, low-density lipoprotein; HbA1c, hemoglobin A1c test.

well as of the focal clusters with significant interval changes, were extracted in each patient for statistical analysis. For resting-state-fMRI, preprocessing and analytic procedures were performed as previously described.¹³ ROIs with 4-mm radii were defined in the hemisphere ipsilateral to ICA stenosis (flipped to the right), representing the seed regions for 6 resting-state networks, including the posterior cingulate cortex (0, −50, 22) and the medial prefrontal cortex (1, 48, −4) for the default mode network, right frontal eye field (26, 6, 48) for the dorsal attention network, the middle frontal gyrus (45, 29, 32) for the frontoparietal network, the primary motor cortex (41, −20, 62) for the sensorimotor network, the dorsal anterior cingulate cortex (1, 10, 46) for the salience network, and, last, the primary visual cortex (4, 81, −10) for the visual network as a control supplied by the vertebrobasilar circulation.¹³

The temporal correlations between the blood oxygen level-dependent signals from each ROI and brain-wise voxels were calculated and presented as Pearson correlation coefficients (r), followed by a Fisher r - z transformation. Z values from a single ROI in each network were defined as functional connectivity (Fc) and were computed with 1-sample t tests by using SPM8 to generate the Fc map in both groups. For within-group analysis, the Fc interval changes in each group were obtained by a paired t test, followed by false discovery rate correction with a significance defined as $q < .05$.

Statistical Analyses of Demographic/Neuropsychological Variables and Multivariate Regression Models

SPSS software (Version 18.0; IBM, Armonk, New York) was used for the statistical analyses. Categorical variables between groups were compared by using χ^2 or Fisher exact tests if the expected number was ≤ 5 . The baseline dizziness, neuropsychological tests, leukoariosis scores, hippocampal volumes, and the mean FA values were compared by 2-sample t tests between groups. The within-group interval changes of parameters were compared by paired t tests. The between-group interval changes of each value were then compared by using 2-sample t tests.

Significance was defined as $P < .05$. The significance of 9 neuropsychological measures was corrected by the Bonferroni method ($P < .0056$). The changes of the dizziness scale and neuropsychological scores were classified as improvement from the baseline (>0), no change ($=0$), or decline (<0), and the percentages of each condition were compared between groups by using χ^2 or Fisher exact tests. To investigate the relationship between the connectivity measures (ie, FA or Fc) and the neuropsychological changes after treatments, we used a multivariate regression model

adjusted for age, sex, years of education, treatment group, the stenotic degree, the baseline presence of mild cognitive impairment (MCI), and vascular risk factors. We defined MCI or vascular cognitive impairment no dementia (MCI/VCIND) with a delayed verbal recall score of <8 (ie, 1.5 SDs below the mean of the healthy controls according to the previous literature).^{13,32}

RESULTS

Ischemic Events and the Neurocognitive Changes after Treatment

Forty-seven subjects were consecutively enrolled, with 5 being excluded due to the presence of $\geq 50\%$ stenosis in the bilateral ICA and 2 being lost to follow-up. Therefore, 40 subjects, 15 in the medical group and 25 in the stent-placement group, completed the neuropsychological follow-up; 34 of them also completed the neuroimaging follow-up (13 and 21 in respective groups). The baseline characteristics, scores on the Dizziness Handicap Inventory and neuropsychological tests, percentage of MCI/VCIND, Scheltens leukoariosis score, hippocampal volumes, and hemispheric mean FA values between groups were not different (Table 1). Six of 15 patients in the medical group (40%) and 7 of 25 in the stent-placement group (28%) were considered to have MCI/VCIND ($P = .318$). The stent-placement group had 100% suc-

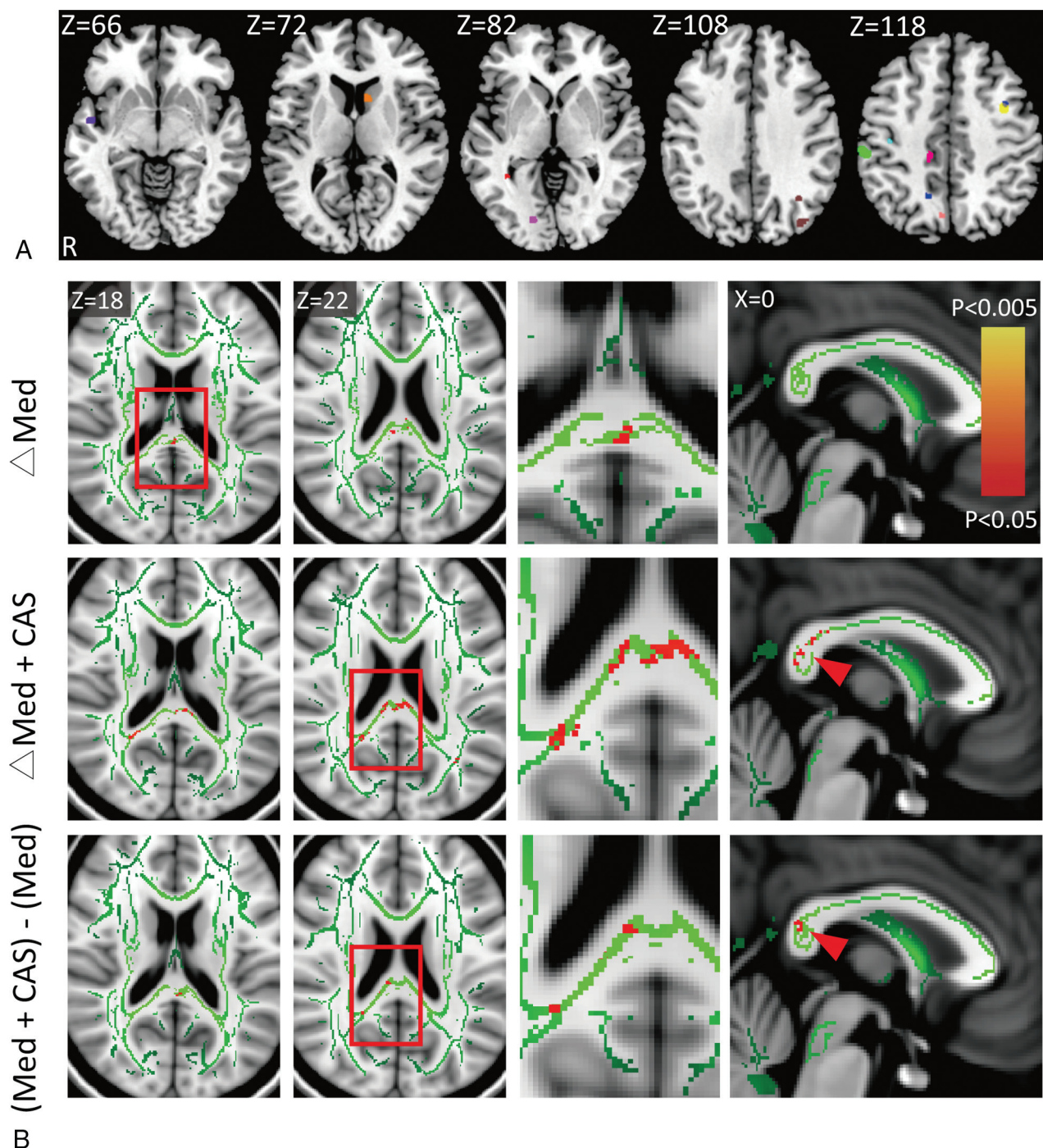


FIG 1. A, Procedure-related microemboli based on the diffusion-weighted images are overlaid on a standard Montreal Neurological Institute template from 12 of 25 patients in the stent-placement group, indicated by different colors. B, The increases (red-yellow) of fractional anisotropy (the white matter skeleton is shown in green) at 3 months after aggressive medical therapy alone (Med, upper row) or combined carotid artery stent placement (Med+CAS, middle row) and the between-group comparisons (lower row). The carotid stenotic side was set to the right in all subjects. The third column from the left represents the high-power views of the insets. Note significant FA increases at the posterior corpus callosum (arrowheads) and the posterior periventricular white matter ipsilateral to the CAS in the stent-placement group.

cessful carotid revascularization with residual stenosis of <50% and no periprocedural events, though 12 patients (48%) had asymptomatic tiny cerebral emboli after the procedure according to MR imaging (Fig 1A).

At 3 months after treatment, there were no vascular events among all subjects. There was no between-group difference in the changes of neurocognitive function, except that the stent-place-

ment group showed subjectively better dizziness alleviation ($P = .045$) compared with the medical group. However, the stent-placement group, but not the medical group, had notable within-group improvement in the total immediate recall of verbal memory ($P = .001$, uncorrected; with $P < .0056$ as significant) and the visuospatial performance (Complex Figure Test [Copy], $P = .001$, uncorrected) (Table 2). In the total immediate recall test, 21

Table 2: Interval changes within and between groups

Δ Changes	Med	Med+CAS	P Value
Dizziness Handicap Inventory	-2.7 ± 4.8	-6.7 ± 7.1^a	.045 ^a
Neuropsychological tests			
Mini-Mental State Examination	-0.2 ± 1.7	0.1 ± 1.0	.525
Total immediate recall	2.2 ± 5.6	4.2 ± 5.6^a	.296
Delayed recall	-0.3 ± 1.2	0.6 ± 1.7	.050
Symbol Digit Modalities Test	1.7 ± 5.2	2.3 ± 4.4	.710
Modified Trail-Making Test A	-0.1 ± 8.1	-2.6 ± 4.5	.309
Modified Trail-Making Test B	1.7 ± 31.9	-4.9 ± 13.1	.405
Stroop Color and Word Test	1.7 ± 5.8	2.9 ± 6.4	.545
Complex Figure Test (Copy)	0.2 ± 1.4	1.1 ± 1.4^a	.064
Complex Figure Test (Recall)	0.1 ± 3.1	1.7 ± 3.7	.157
Scheltens leukoaraiosis score	0.1 ± 0.3	0.2 ± 0.5	.561
Ipsilateral hemispheric FA	0.002 ± 0.04	0.009 ± 0.004	.447
Contralateral hemispheric FA	0.002 ± 0.05	0.004 ± 0.005	.681

Note:—Med indicates medical therapy alone.

^a For dizziness and imaging measures, $P < .05$ was defined as significant. For the 9 neuropsychological tests, $P < .0056$ was defined as significant with the Bonferroni correction.

of 25 in the stent-placement group (84%) and 9 of 15 in the medical group (60%) showed improvement after treatment ($P = .057$), while 3 in the stent-placement group (12%) and 3 in the medical group (20%) performed worse ($P = .199$).

Changes of Structural and Functional Connectivity by Treatment

Most interesting, both groups showed localized FA increases at the posterior corpus callosum after treatment. The between-group comparison of the FA changes showed that the stent-placement group had small-but-significant FA increments at the posterior corpus callosum and the posterior periventricular white matter ipsilateral to the stenosis/CAS compared with the medical group (Fig 1B). Neither the leukoaraiosis score nor the hemispheric mean FA showed notable changes in both groups (Table 2). On the examined functional networks, we noted within-group, but no between-group, enhancement of Fc strength in the stent-placement group, but not in the medical group, between the posterior cingulate cortex and the medial prefrontal cortex contralateral to the stenosis/CAS in the default mode network as well as between the frontal eye field and the insular cortex contralateral to the stenosis/CAS in the dorsal attention network (Fig 2A, -B).

Correlation between Neurocognitive Changes and Connectivity Measures

Using a multivariate regression model, we found that the baseline whole-brain mean FA ($P = .002$) and the treatment technique (stent-placement better, $P = .034$) correlated with the decreases in dizziness (Dizziness Handicap Inventory) ($R^2 = 0.411$) after adjusting for age, sex, years of education, stenotic degree, presence of MCI, and vascular risk factors. Figure 3A shows a reverse linear relationship between the whole-brain mean FA and decreases in the Dizziness Handicap Inventory in both groups, suggesting the lower mean connectivity of the patients at baseline and more dizziness alleviation felt after treatment. With regard to the variables affecting the total immediate recall scores, age ($P = .021$) and interval changes of focal FA at the posterior corpus callosum ($P = .040$) correlated with the changes of the total immediate recall performance ($R^2 = 0.331$) in the stent-placement group, but not in the medical group (Fig 3B). Neither the baseline status

of MCI/VCIND (Fig 3C) nor the baseline stenotic degree predicted the changes of either total immediate recall scores or complex figure recall scores (Fig 3D).

DISCUSSION

This was a nonrandomized controlled study of revascularization plus aggressive medical therapy for severe asymptomatic carotid stenosis with respect to the possibility of cognitive and connectivity enhancement. We found that combined revascularization and aggressive medical treatment significantly alleviated subjective dizziness but did not enhance cognitive performance after 3 months compared with the aggressive

medical treatments alone. The above findings were accompanied by greater increases of microstructural connectivity at the splenium of the corpus callosum and the posterior periventricular white matter ipsilateral to the stenosis/CAS. The baseline whole-brain mean FA was inversely correlated with the dizziness alleviation. Moreover, only the stent-placement group showed interval improvement in the short-term verbal memory and visuospatial performance after 3 months. Most interesting, the higher the FA increase at the posterior corpus callosum after CAS, the greater was the improvement in short-term verbal memory, suggesting that augmented microstructural connectivity of the posterior white matter might mediate revascularization-related cognitive changes. The stent-placement group also had focal increases of Fc at the medial prefrontal cortex in the default mode network and at the insula in the dorsal attention network contralateral to the stenosis/CAS, which we previously disclosed as susceptible regions in unilateral severe asymptomatic carotid stenosis patients.¹³ These Fc changes were not significantly different between groups but might implicate partial reversibility by a combined revascularization therapy. Thus, it is important to identify those asymptomatic patients at risk and offer timely treatment.

A previous uncontrolled case series of uncomplicated carotid endarterectomy in symptomatic ($n = 50$) and asymptomatic ($n = 30$) patients with $>70\%$ carotid stenosis showed an increase of the hemispheric mean FA ipsilateral to the surgery site after 1 month in association with posttreatment cognitive improvement.³³ In contrast, others reported postoperative memory decline in a portion of patients with symptomatic or asymptomatic carotid stenosis 1 month after undergoing carotid endarterectomy or CAS. The multivariate regression analysis showed that memory decline was associated with periprocedural microemboli ($11/21 = 52\%$) and baseline neurologic deficits.³⁴ In our study, a similar proportion (48%) in the stent-placement group was found to have procedure-related silent microemboli. Nevertheless, we found a modest memory enhancement instead of decline in the stent-placement group and no correlation between the microemboli and cognitive changes at 3 months. The focal FA at the watershed posterior corpus callosum and the posterior periventricular region, rather than the hemispheric mean FA, increased, particu-

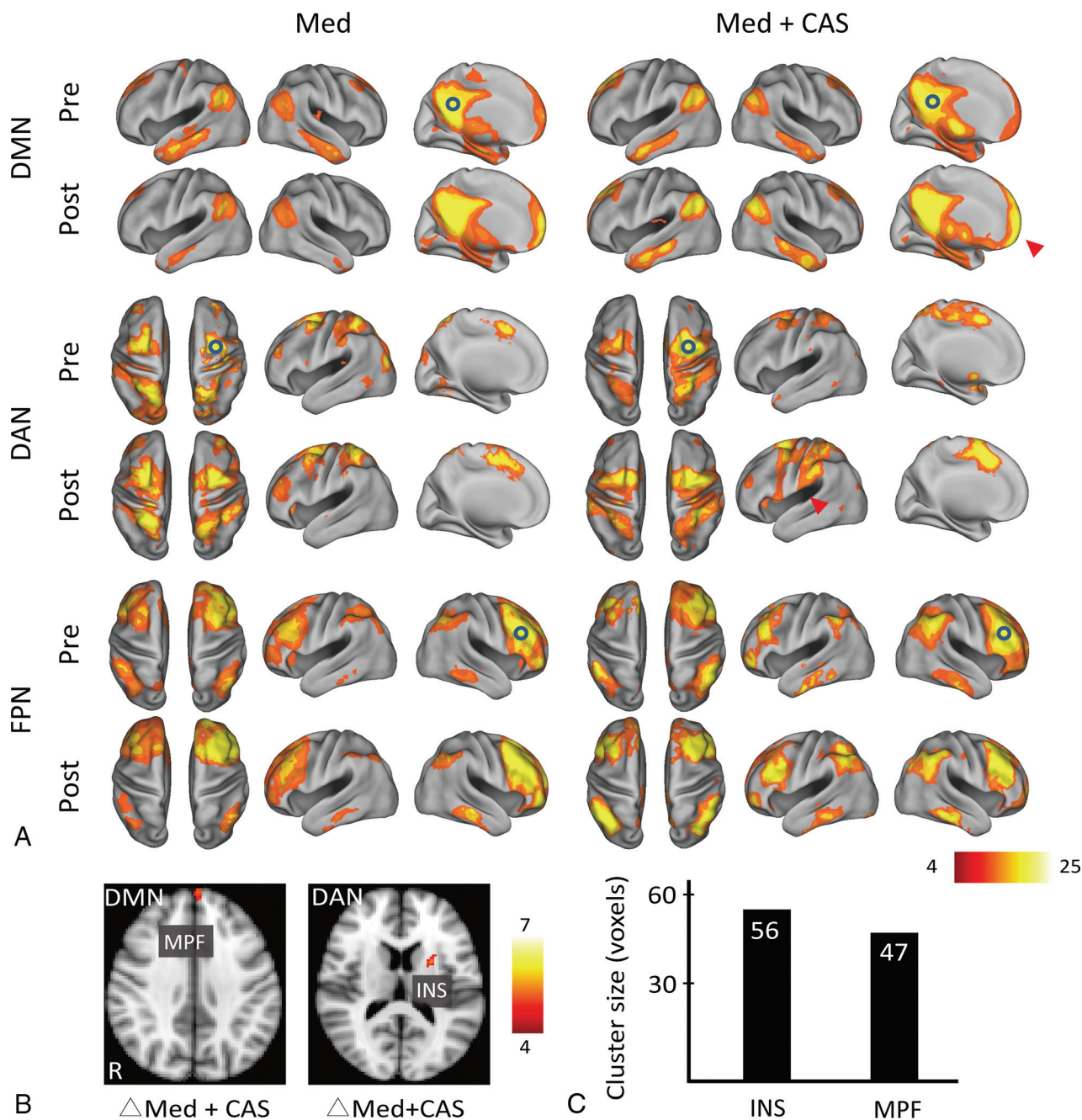


FIG 2. A and B, The functional connectivity correlation maps of both groups (Med indicates medical group; Med + CAS, stent placement group) before (pre) and 3 months after treatment (post). The carotid stenotic side was set to the right. *Hollow circles* indicate the predefined ROIs for individual networks at the right brain. Color bars represent T values. Q indicates the false discovery rate–corrected *P* value. The stent-placement group, not the medical group, showed within-group enhancement of Fc at the medial prefrontal cortex (MPF, $T = 5.27$, cluster size = 47, $Q = .027$) of the default mode network (DMN) and at the insular cortex (INS; $T = 5.35$, cluster size = 56, $Q = .040$) of the dorsal attention network (DAN) (arrowheads). C, The bar chart of the aforementioned cluster sizes with increased Fc is shown. FPN indicates frontoparietal network.

larly in the stent-placement group. The posterior corpus callosum (ie, the splenium) is supplied by both the anterior cerebral artery and the posterior cerebral artery,³⁵ perfusion of which can be augmented by revascularization therapy. The nearby retrosplenial cortex is structurally connected with the medial prefrontal cortex and medial temporal regions and involved in memory processing³⁶ with the precuneus, posterior cingulate cortex, and hippocampus.³⁷ Lesions in the splenium or the retrosplenial cortex have been reported to result in verbal and visual memory deficits.^{38,39} The cellular components of the observed FA or Fc in-

creases are still unknown. They can be attributed to increased vasodilation and blood flow, improved neurovascular reactivity,⁴⁰ neural plasticity,⁴¹ and/or remyelination⁴² as suggested by MR spectroscopic studies.

This study has limitations. The nonrandomized controlled design was due to the interventional limitations (eg, medical therapy alone suited patients with total ICA occlusion or those older than 70 years of age with tortuous vessels) and personal hesitation for intervention. Therefore, currently ongoing large-scale randomized controlled trials such as CREST-2 are warranted to determine

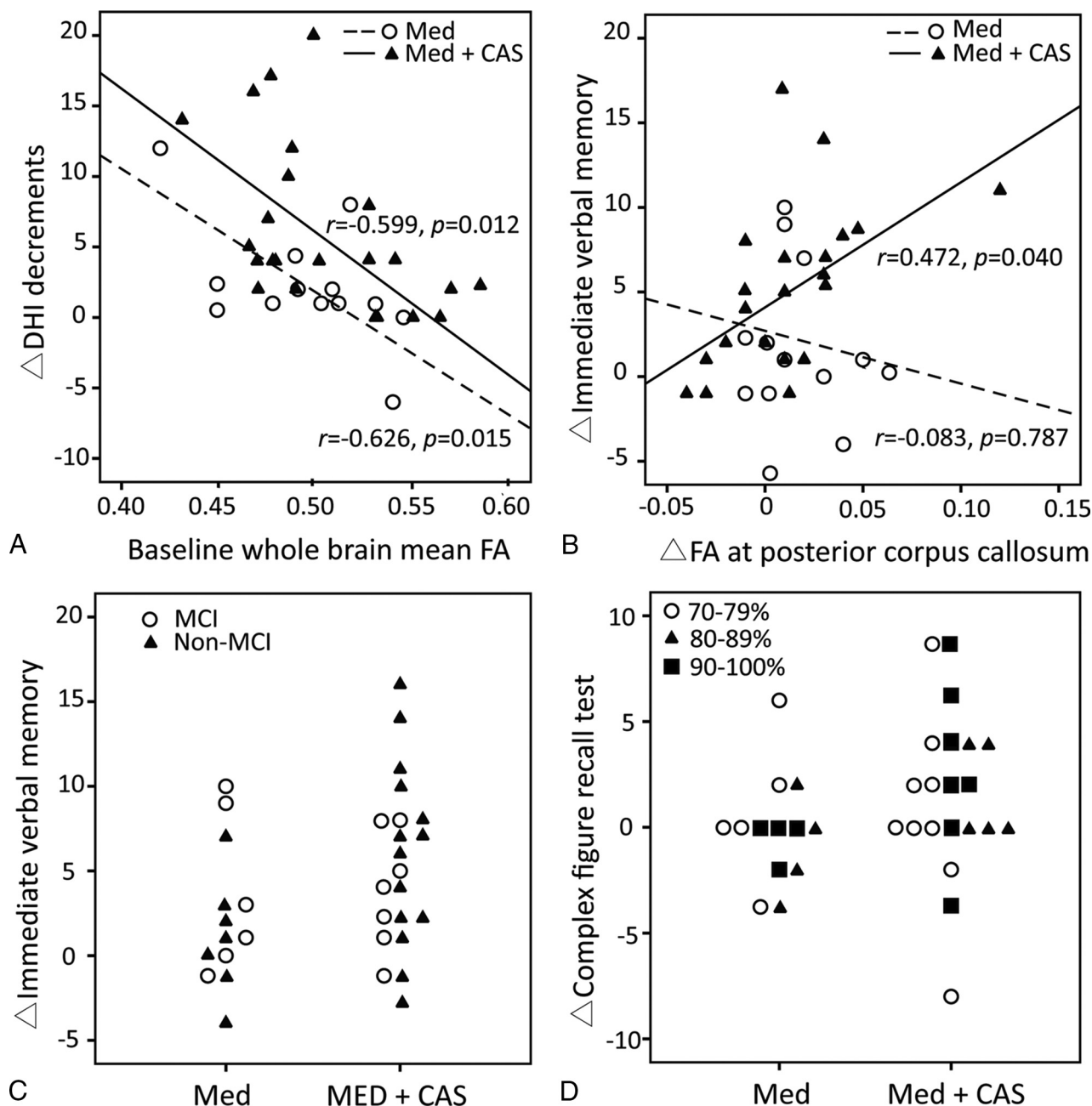


FIG 3. Scatterplots of the correlation analyses in the medical (Med) and the stent placement group (Med+CAS). *A*, The baseline whole-brain mean fractional anisotropy negatively correlates with dizziness alleviation (decreases in Dizziness Handicap Inventory [DHI]) in both groups. *B*, The focal FA increases in the posterior corpus callosum positively correlate with the improvement of immediate verbal memory only in the stent-placement group. *C*, The relationship is shown between the baseline presence of mild cognitive impairment/vascular cognitive impairment no dementia and the improvement of immediate verbal memory in the 2 groups. *D*, The baseline stenotic degree is not related to the changes of Complex Figure Test (Recall) scores.

long-term differences in efficacy between optimal medical therapy alone and combined revascularization therapy for stroke prevention (primary outcome) and cognitive preservation (secondary outcome) in patients with asymptomatic severe carotid stenosis. However, this small single-center trial provides new evidence of the benefit-risk balance for revascularization therapy and proposes a possible connectivity target for treating cognitive dysfunction in these patients. Furthermore, we did not assess the plaque-related microemboli and cerebrovascular reperfusion. Successful restoration of cerebral hypoperfusion was shown to

correspond to the cognitive improvement after CAS.¹⁷ Additional transcranial emboli detection and perfusion imaging may help to elucidate the therapeutic mechanisms underlying cognitive and/or connectivity changes. Last, we cannot exclude the short-term placebo effects of subjective dizziness alleviation in the stent-placement group or a superimposed vestibular component in these patients.

CONCLUSIONS

Patients with severe asymptomatic carotid stenosis showed subjective dizziness alleviation in association with greater increases in

microstructural connectivity at the posterior corpus callosum and periventricular white matter by aggressive medical therapy plus successful revascularization compared with aggressive medical therapy alone. However, the cognitive benefit was insignificant between groups at 3 months after treatment in our study. Unlike neurodegenerative causes of cognitive impairment, vascular damage is preventable and treatable. Our results suggest the feasibility of combined medical and revascularization treatment in severe asymptomatic carotid stenosis for limiting cognitive decline, possibly through ancillary connectivity enhancement. Large long-term controlled studies are warranted to provide a risk-benefit assessment for prophylactic carotid revascularization.

ACKNOWLEDGMENTS

We gratefully acknowledge Wen-Yung Sheng for providing statistical advice. We also thank the Clinical Research Core Laboratory of Taipei Veterans General Hospital for providing experimental space and facilities.

Disclosures: Chun-Jen Lin—*RELATED: Grant:* Taipei Veterans General Hospital, Taiwan (V103C-171, V104C-059, V105B-029).* I-Hui Lee—*RELATED: Grant:* Ministry of Science and Technology, Taiwan (MOST103-2320-B-075-002, MOST103-2314-B-075-008, MOST104-2320-B-075-001), Taipei Veterans General Hospital, Taiwan (V103C-171, V104C-059, V105B-029)*; *Support for Travel to Meetings for the Study or Other Purposes:* Ministry of Science and Technology, Taiwan.* *Money paid to the institution.

REFERENCES

- Executive Committee for the Asymptomatic Carotid Atherosclerosis Study. **Endarterectomy for asymptomatic carotid artery stenosis.** *JAMA* 1995;273:1421–28 CrossRef Medline
- Halliday A, Mansfield A, Marro J, et al; MRC Asymptomatic Carotid Surgery Trial (ACST) Collaborative Group. **Prevention of disabling and fatal strokes by successful carotid endarterectomy in patients without recent neurological symptoms: randomised controlled trial.** *Lancet* 2004;363:1491–502 CrossRef Medline
- Marquardt L, Geraghty OC, Mehta Z, et al. **Low risk of ipsilateral stroke in patients with asymptomatic carotid stenosis on best medical treatment: a prospective, population-based study.** *Stroke* 2010; 41:e11–17 CrossRef Medline
- den Hartog AG, Achterberg S, Moll FL, et al; SMART Study Group. **Asymptomatic carotid artery stenosis and the risk of ischemic stroke according to subtype in patients with clinical manifest arterial disease.** *Stroke* 2013;44:1002–07 CrossRef Medline
- Markus HS, King A, Shipley M, et al. **Asymptomatic embolisation for prediction of stroke in the Asymptomatic Carotid Emboli Study (ACES): a prospective observational study.** *Lancet Neurol* 2010;9: 663–71 CrossRef Medline
- Nicolaides AN, Kakkos SK, Kyriacou E, et al. **Asymptomatic internal carotid artery stenosis and cerebrovascular risk stratification.** *J Vasc Surg* 2010;52: 1486–1496.e1–5 CrossRef Medline
- Gupta A, Chazen JL, Hartman M, et al. **Cerebrovascular reserve and stroke risk in patients with carotid stenosis or occlusion: a systematic review and meta-analysis.** *Stroke* 2012;43:2884–91 CrossRef Medline
- Rosenfield K, Matsumura JS, Chaturvedi S, et al. **Randomized trial of stent versus surgery for asymptomatic carotid stenosis.** *N Engl J Med* 2016;374:1011–20 CrossRef Medline
- Brott TG, Howard G, Roubin GS, et al; CREST Investigators. **Long-term results of stenting versus endarterectomy for carotid-artery stenosis.** *N Engl J Med* 2016;374:1021–31 CrossRef Medline
- Johnston SC, O'Meara ES, Manolio TA, et al. **Cognitive impairment and decline are associated with carotid artery disease in patients without clinically evident cerebrovascular disease.** *Ann Intern Med* 2004;140:237–47 CrossRef Medline
- Popovic IM, Lovrencic-Huzjan A, Simundic AM, et al. **Cognitive performance in asymptomatic patients with advanced carotid disease.** *Cogn Behav Neurol* 2011;24:145–51 CrossRef Medline
- Cheng HL, Lin CJ, Soong BW, et al. **Impairments in cognitive function and brain connectivity in severe asymptomatic carotid stenosis.** *Stroke* 2012;43:2567–73 CrossRef Medline
- Lin CJ, Tu PC, Chern CM, et al. **Connectivity features for identifying cognitive impairment in presymptomatic carotid stenosis.** *PLoS One* 2014;9:e85441 CrossRef Medline
- Silvestrini M, Paolino I, Vernieri F, et al. **Cerebral hemodynamics and cognitive performance in patients with asymptomatic carotid stenosis.** *Neurology* 2009;72:1062–68 CrossRef Medline
- Ortega G, Alvarez B, Quintana M, et al. **Asymptomatic carotid stenosis and cognitive improvement using transcervical stenting with protective flow reversal technique.** *Eur J Vasc Endovasc Surg* 2014;47: 585–92 CrossRef Medline
- Grunwald IQ, Papanagiotou P, Reith W, et al. **Influence of carotid artery stenting on cognitive function.** *Neuroradiology* 2010;52: 61–66 CrossRef Medline
- Chen YH, Lin MS, Lee JK, et al. **Carotid stenting improves cognitive function in asymptomatic cerebral ischemia.** *Int J Cardiol* 2012;157: 104–07 CrossRef Medline
- Antonopoulos CN, Kakisis JD, Sfyroeras GS, et al. **The impact of carotid artery stenting on cognitive function in patients with extracranial carotid artery stenosis.** *Ann Vasc Surg* 2015;29:457–69 CrossRef Medline
- Yoon BA, Sohn SW, Cheon SM, et al. **Effect of carotid artery stenting on cognitive function in patients with carotid artery stenosis: a prospective, 3-month-follow-up study.** *J Clin Neurol* 2015;11:149–56 CrossRef Medline
- Mendiz OA, Sposato LA, Fabbro N, et al. **Improvement in executive function after unilateral carotid artery stenting for severe asymptomatic stenosis.** *J Neurosurg* 2012;116:179–84 CrossRef Medline
- Grant EG, Benson CB, Moneta GL, et al. **Carotid artery stenosis: gray-scale and Doppler US diagnosis—Society of Radiologists in Ultrasound Consensus Conference.** *Radiology* 2003;229:340–46 CrossRef Medline
- North American Symptomatic Carotid Endarterectomy Trial Collaborators. **Beneficial effect of carotid endarterectomy in symptomatic patients with high-grade carotid stenosis.** *N Engl J Med* 1991;325: 445–53 CrossRef Medline
- Jacobson GP, Newman CW. **The development of the Dizziness Handicap Inventory.** *Arch Otolaryngol Head Neck Surg* 1990;116: 424–27 CrossRef Medline
- Hannay HJ, Levin HS. **Selective reminding test: an examination of the equivalence of four forms.** *J Clin Exp Neuropsychol* 1985;7: 251–63 CrossRef Medline
- Tombaugh TN. **Trail Making Test A and B: normative data stratified by age and education.** *Arch Clin Neuropsychol* 2004;19:203–14 CrossRef Medline
- Jensen AR, Rohwer WD Jr. **The Stroop color-word test: a review.** *Acta Psychol (Amst)* 1966;25:36–93 CrossRef Medline
- Erber JT, Botwinick J, Storandt M. **The impact of memory on age differences in digit symbol performance.** *J Gerontol* 1981;36:586–90 CrossRef Medline
- Scheltens P, Barkhof F, Leys D, et al. **A semiquantitative rating scale for the assessment of signal hyperintensities on magnetic resonance imaging.** *J Neurol Sci* 1993;114:7–12 CrossRef Medline
- Lehéricy S, Baulac M, Chiras J, et al. **Amygdalohippocampal MR volume measurements in the early stages of Alzheimer disease.** *AJNR Am J Neuroradiol* 1994;15:929–37 Medline
- Wang PN, Lirng JF, Lin KN, et al. **Prediction of Alzheimer's disease in mild cognitive impairment: a prospective study in Taiwan.** *Neurobiol Aging* 2006;27:1797–806 CrossRef Medline
- Ashburner J, Friston KJ. **Voxel-based morphometry: the methods.** *Neuroimage* 2000;11:805–21 CrossRef Medline

32. Larrabee GJ, Trahan DE, Levin HS. **Normative data for a six-trial administration of the Verbal Selective Reminding Test.** *Clin Neuropsychol* 2000;14:110–18 [CrossRef Medline](#)
33. Sato Y, Ito K, Ogasawara K, et al. **Postoperative increase in cerebral white matter fractional anisotropy on diffusion tensor magnetic resonance imaging is associated with cognitive improvement after uncomplicated carotid endarterectomy: tract-based spatial statistics analysis.** *Neurosurgery* 2013;73:592–98; discussion 598–99 [CrossRef Medline](#)
34. Zhou W, Hitchner E, Gillis K, et al. **Prospective neurocognitive evaluation of patients undergoing carotid interventions.** *J Vasc Surg* 2012;56:1571–78 [CrossRef Medline](#)
35. Kahilogullari G, Comert A, Ozdemir M, et al. **Arterial vascularization patterns of the splenium: an anatomical study.** *Clin Anat* 2013;26:675–81 [CrossRef Medline](#)
36. Vann SD, Aggleton JP, Maguire EA. **What does the retrosplenial cortex do?** *Nat Rev Neurosci* 2009;10:792–802 [CrossRef Medline](#)
37. Wang L, Laviolette P, O'Keefe K, et al. **Intrinsic connectivity between the hippocampus and posteromedial cortex predicts memory performance in cognitively intact older individuals.** *Neuroimage* 2010;51:910–17 [CrossRef Medline](#)
38. Kim JH, Park KY, Seo SW, et al. **Reversible verbal and visual memory deficits after left retrosplenial infarction.** *J Clin Neurol* 2007;3:62–66 [CrossRef Medline](#)
39. Jeong SH, Lee JH, Lee AY. **Reversible visual memory in transient splenial lesion.** *Neurology* 2009;73:647 [CrossRef Medline](#)
40. Schaaf M, Mommertz G, Ludolph A, et al. **Functional MR imaging in patients with carotid artery stenosis before and after revascularization.** *AJNR Am J Neuroradiol* 2010;31:1791–98 [CrossRef Medline](#)
41. Saito H, Ogasawara K, Nishimoto H, et al. **Postoperative changes in cerebral metabolites associated with cognitive improvement and impairment after carotid endarterectomy: a 3T proton MR spectroscopy study.** *AJNR Am J Neuroradiol* 2013;34:976–82 [CrossRef Medline](#)
42. Kim GE, Lee JH, Cho YP. **Can carotid endarterectomy improve metabolic status in patients with asymptomatic internal carotid artery flow lesion? Studies with localized in vivo proton magnetic resonance spectroscopy.** *J Vasc Surg* 2002;36:559–64 [CrossRef Medline](#)