



Discover Generics

Cost-Effective CT & MRI Contrast Agents



WATCH VIDEO

AJNR

Ataxia Severity Correlates with White Matter Degeneration in Spinocerebellar Ataxia Type 7

C.R. Hernandez-Castillo, I. Vaca-Palomares, F. Barrios, L. Martinez, M.-C. Boll and J. Fernandez-Ruiz

This information is current as of June 1, 2025.

AJNR Am J Neuroradiol 2016, 37 (11) 2050-2054

doi: <https://doi.org/10.3174/ajnr.A4903>

<http://www.ajnr.org/content/37/11/2050>

Ataxia Severity Correlates with White Matter Degeneration in Spinocerebellar Ataxia Type 7

 C.R. Hernandez-Castillo,  I. Vaca-Palomares,  F. Barrios,  L. Martinez,  M.-C. Boll, and  J. Fernandez-Ruiz



ABSTRACT

BACKGROUND AND PURPOSE: There is a scarcity of information on the effect of white matter degeneration in patients with spinocerebellar ataxia type 7. Therefore, we investigated the WM integrity in a large group of patients with spinocerebellar ataxia type 7 by using Tract-Based Spatial Statistics.

MATERIALS AND METHODS: Thirty-three patients with a molecular diagnosis of spinocerebellar ataxia type 7 and their age- and sex-matched healthy controls participated in this study. The patients' ataxia severity was evaluated with the Scale for the Assessment and Rating of Ataxia. Voxelwise analyses of diffusion metrics, including fractional anisotropy and mean diffusivity, were performed with Tract-Based Spatial Statistics. The correlation between WM abnormalities and ataxia severity was then calculated.

RESULTS: Tract-Based Spatial Statistics analysis revealed WM abnormalities in the cerebellum and the cerebellar peduncles, as well as in other major cortical and subcortical pathways. Further analysis between the Scale for the Assessment and Rating of Ataxia score and WM mean diffusivity showed significant associations only in key areas related to motor control and visuospatial processing, including the cerebellar WM, the middle occipital WM, the superior cerebellar peduncle, and bilateral anterior thalamic radiation. No significant associations between fractional anisotropy and the Scale for the Assessment and Rating of Ataxia were found.

CONCLUSIONS: These results suggest a significant contribution of local cerebellar and cerebellar-midbrain connections to ataxic impairment in spinocerebellar ataxia type 7. The results also suggest an involvement of cortical WM abnormalities including tracts within the occipital and frontal cortices. These findings contribute to a more comprehensive view of the clinical impact of the white matter degeneration in spinocerebellar ataxia type 7.

ABBREVIATIONS: FA = fractional anisotropy; MD = mean diffusivity; SARA = Scale for the Assessment and Rating of Ataxia; SCA = spinocerebellar ataxia; SCA7 = spinocerebellar ataxia type 7; TBSS = Tract-Based Spatial Statistics

Spinocerebellar ataxia type 7 (SCA7) is an autosomal dominant cerebellar ataxia caused by a mutation consisting in the expansion of the cytosine-adenine-guanine trinucleotide in the codon region of the chromosome 3p21, encoding the protein ataxin 7.¹

SCA7 is considered one of the rarest forms of genetic autosomal dominant cerebellar ataxia.² Clinically, SCA7 is characterized by a combination of cerebellar ataxia and macular degeneration and is the only spinocerebellar ataxia that manifests in permanent blindness.^{3,4} Furthermore, patients may eventually develop other neurologic deficits, including loss of manual dexterity, speech dysarthria, dysphagia, and eye movement abnormalities.² A number of neuropathologic studies have documented the anatomic consequences of the neurodegenerative process. These include severe degeneration of the cerebellar cortex and other cortical regions.^{5,6}

MR imaging techniques such as diffusion tensor imaging can produce high-resolution structural images of white matter tracts. On the basis of the measurement of water diffusion properties, DTI allows quantifying the tissue microstructure and inferring its integrity.⁷ This MR imaging technique also enables mapping of white matter tract changes across the life span and alterations in neurologic disorders, becoming an important tool in the study of neurodegenerative diseases.^{8,9} Diffusion properties include mean

Received March 28, 2016; accepted after revision May 26.

From the Consejo Nacional de Ciencia y Tecnología-Instituto de Neuroetología (C.R.H.-C.), Universidad Veracruzana, Veracruz, Mexico; Departamento de Fisiología (I.V.-P., J.F.-R.), Facultad de Medicina, and Instituto de Neurobiología (F.B.), Universidad Nacional Autónoma de México, Mexico City, Mexico; and Departamento de Neurogenética y Biología Molecular (L.M.) and Laboratorio de Investigación Clínica (M.-C.B.), Instituto Nacional de Neurología y Neurocirugía, "Manuel Velasco Suárez," Mexico City, México.

This work was supported by Consejo Nacional de Ciencia y Tecnología grant 220871 and Universidad Nacional Autónoma de México grant PAPIIT IN214716 to J.F.-R.

Please address correspondence to Juan Fernandez-Ruiz, PhD, Departamento de Fisiología, Facultad de Medicina, Universidad Nacional Autónoma de México, UNAM, Av. Universidad 3000, Coyoacán, Distrito Federal, México, 04510; e-mail: jfr@unam.mx

 Indicates open access to non-subscribers at www.ajnr.org

<http://dx.doi.org/10.3174/ajnr.A4903>

diffusivity (MD) (also referred to as apparent diffusion coefficient) and fractional anisotropy (FA). In neurodegenerative diseases including spinocerebellar ataxias (SCAs), both MD and FA have gained widespread acceptance as sensitive indicators for quantifying microstructural damage to white matter, showing the

associations between the white matter integrity and behavioral impairment in some cases.^{6,10–13} Among several studies using diffusion measurements, only a preliminary study has explored the white matter integrity in a small group of patients with SCA7,⁶ reporting significant FA decreases that correlate with the number of years passed from the onset of symptoms. However, the contribution of the degeneration of projection fibers to the patients' impairments was not explored, possibly due to the small number of subjects. To test this hypothesis, we explored the relationship between ataxia severity and WM metrics that result from the statistical analysis of diffusion tensor imaging in a larger cohort of patients with SCA7.

Table 1: Demographic information of the SCA7 group

ID	Sex	Age (yr)	Years from Onset	MMSE	MoCA	SARA
P01	F	21	1	26	NC	4
P02	M	20	1	29	NC	4
P03	F	68	1	24	NC	6
P04	F	18	4	27	NC	7
P05	F	35	6	26	NC	8.5
P06	F	44	6	26	16	9
P07	F	64	13	28	12	9.5
P08	M	44	4	24	18	11
P09	F	22	2	26	NC	11
P10	M	52	7	26	16	12
P11	F	45	7	26	21	12
P12	M	23	3	24	27	12.5
P13	M	47	6	26	14	13
P14	M	25	4	26	13	14
P15	M	64	10	26	15	14.5
P16	M	38	13	27	18	14.5
P17	F	43	21	26	NC	15
P18	M	35	14	26	9	16
P19	M	60	6	26	13	16
P20	M	30	6	25	12	16
P21	M	34	10	28	NC	17
P22	M	30	5	26	NC	17
P23	F	32	6	27	NC	19
P24	M	18	8	26	16	19.5
P25	F	40	13	25	NC	23
P26	M	54	6	25	NC	24
P27	M	61	7	22	NC	25
P28	M	29	7	21	17	25
P29	F	40	21	22	18	27
P30	F	39	23	25	18	27
P31	F	42	17	23	15	29.5
P32	M	19	7	22	10	29.5
P33	F	51	8	26	18	30

Note:—MMSE indicates Mini-Mental State Examination; MoCA, Montreal Cognitive Assessment; NC, not completed; ID, identification.

MATERIALS AND METHODS

Subjects

Thirty-three patients with a molecular diagnosis of SCA7 were invited to participate in this study (15 right-handed women; mean age, 39.0 ± 14.6 years). The Scale for the Assessment and Rating of Ataxia (SARA)¹⁴ was used as a semiquantitative valuation of movement impairment, comprising 8 items related to gait, stance, sitting, speech, finger-chase test, nose-finger test, fast alternating movements, and the heel-shin test.¹⁵ Extended information about the SCA7 group can be found in Table 1. Thirty-three age- and sex-matched controls (15 right-handed women; mean age, 41.7 ± 13.8 years) participated in the study. The control group declared that they did not have any history of neurologic or psychiatric disorders. All procedures were in accordance with the ethical standards of the Declaration of Helsinki of 1975 and the applicable revisions at the time of the investigation. Therefore, the committees on human experimentation of the Universidad Nacional Autónoma de México specifically approved this study. All participants gave their written informed consent before entering the study.

Image Acquisition

Images were acquired by using a 3T Achieva MR imaging scanner (Philips Healthcare, Best, the Netherlands). The study included the acquisition of a structural high-resolution volume and diffu-

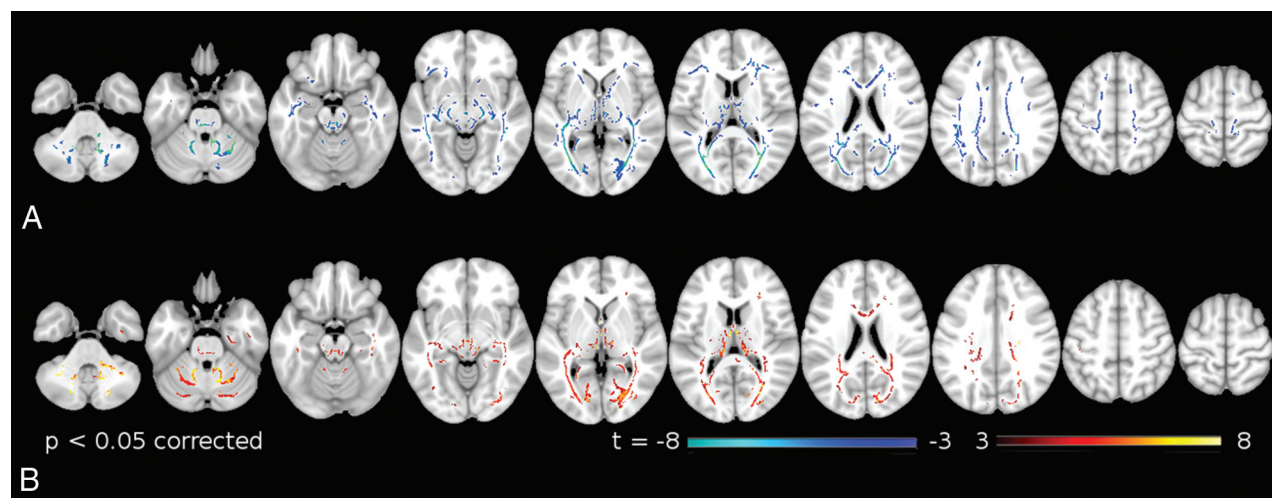


FIG 1. TBSS significant differences in diffusion measurements between patients with SCA7 and healthy controls. A, Fractional anisotropy. B, Mean diffusivity. Warm and cold colors indicate an increase and decrease in these measures in patients with SCA7, respectively.

Table 2: Significant group differences in fractional anisotropy between patients with SCA7 and healthy controls^a

Anatomic Region	Voxels	T-Value	X	Y	Z
Right superior cerebellar peduncle	1797	18.9	7	-47	-28
Left corticospinal tract	1009	11	-13	-56	-28
Left anterior corona radiata	733	6.86	-26	31	11
Body of corpus callosum	327	4.04	-6	13	22
Right corticospinal tract	262	11	13	-50	-43
Left uncinate fasciculus	253	6.27	-21	18	-12
Left superior longitudinal fasciculus	180	5.08	-10	27	49
Left inferior longitudinal fasciculus	177	5.75	-40	-47	-13
Right superior longitudinal fasciculus	162	4.53	36	-13	34
Left anterior limb of the internal capsule	134	5.07	-20	17	5
Left cingulate WM	131	6.36	-6	3	34
Left inferior fronto-occipital fasciculus	121	4.89	-16	35	33
Left superior longitudinal fasciculus	114	4.75	-44	-41	13
Right superior longitudinal fasciculus	112	4.22	51	-7	23

^a Coordinates are in millimeters in Montreal Neurological Institute space. Labels are from the Johns Hopkins University white matter atlas.

Table 3: Significant group differences in mean diffusivity between patients with SCA7 and healthy controls^a

Anatomic Region	Voxels	T-Value	X	Y	Z
Right middle cerebellar peduncle	2712	11.1	26	-51	-37
Left middle cerebellar peduncle	2047	12.6	-26	-48	-38
Left anterior thalamic radiation	911	5.12	-3	-11	11
Right inferior fronto-occipital fasciculus	855	5.19	19	-83	16
Left inferior longitudinal fasciculus	628	4.21	-14	-81	2
Left posterior thalamic radiation	350	3.23	-35	-44	8
Right inferior longitudinal fasciculus	182	4.39	37	-74	2
Right cingulate WM	141	3.59	27	-45	-2
Right posterior corona radiata	112	5.22	29	-34	19
Right anterior thalamic radiation	108	4.16	1	-20	-10
Splenium of corpus callosum	104	4.91	19	-50	22
Left cingulate WM	101	3.58	-28	-50	-1
Left inferior longitudinal fasciculus	100	3.38	-17	-77	15

^a Coordinates are in millimeters in Montreal Neurological Institute space. Labels are from the Johns Hopkins University white matter atlas.

sion tensor imaging. For detailed acquisition parameters, please see Hernandez-Castillo et al.¹¹

Diffusion Tensor Preprocessing

The FSL software (<http://www.fmrib.ox.ac.uk/fsl>) was used to process and analyze the raw DTI data.¹⁶ First, we corrected the eddy current effects; second, the eddy-corrected diffusion-weighted images were spatially normalized by using a rigid-body transformation. Last, the diffusion tensor model was adjusted to generate the fractional anisotropy maps for each participant.

Tract-Based Spatial Statistics

The statistical analysis was performed in a voxelwise manner by using the standard Tract-Based Spatial Statistics (TBSS; <http://fsl.fmrib.ox.ac.uk/fsl/fslwiki/TBSS>) methodology reported elsewhere.¹⁷ The TBSS procedure had the following steps: All subjects' FA data were aligned into a 1-mm isotropic FA target image in standard space (FMRIB58_FA standard space image; http://fsl.fmrib.ox.ac.uk/fsl/fslwiki/FMRIB58_FA) by using the FMRIB Nonlinear Registration Tool (FNIRT; <http://fsl.fmrib.ox.ac.uk/fsl/fslwiki/FNIRT>).¹⁸ Next, the mean FA image was calculated and thinned to create a mean FA skeleton, which represented the centers of all tracts common to the group. This process had 2 steps: 1) averaging the warped FA images, and then 2) thresholding at FA > 0.2. Each subject's aligned FA data were then projected onto

this skeleton. Using the same nonlinear registration derived from the FA analysis, we projected MD data onto the skeleton before voxelwise statistical analysis across subjects.¹⁷

Differences in DTI (FA, MD) parameters between patients with SCA7 and healthy controls were assessed by using a permutation-based nonparametric independent 2-sample *t* test (FSL Randomize tool; <http://fsl.fmrib.ox.ac.uk/fsl/fslwiki/Randomise/>).¹⁹ Age was included in the design matrix as a covariate of no interest. Correction for multiple comparisons was assessed by using threshold-free cluster enhancement.²⁰ We generated 5000 permutations of the data, producing uncorrected and family-wise error-corrected statistical maps. Only those voxels surviving this correction at a *P* value < .05 showed a significant group difference. In a second analysis, we explored the correlation between the ataxia severity and WM measurements (FA and MD). We performed a 1-sample *t* test of the SCA7 group for FA and MD independently, which included the SARA score in the design matrix.

RESULTS

TBSS group comparison revealed significant FA decreases in patients with SCA7 (Fig 1A and Table 2) in the white matter

tracts, including the inferior/middle/superior cerebellar peduncles, the bilateral internal/external capsule, the bilateral corona radiata, the bilateral optical radiation, and the occipital/temporal/frontal white matter.

TBSS group comparison revealed significant MD increases in patients with SCA7 (Fig 1B and Table 3) in the cerebellar WM, including the medial lemniscus, the middle cerebellar peduncle, the optical radiations, the bilateral corona radiata, the posterior limbs of internal capsule, and the corticospinal tract.

We found associations between the patients' SARA scores and mean diffusivity in several abnormal WM tracts. Specifically, we found SARA associations with MD in the right middle occipital WM, stria terminalis, superior cerebellar peduncle, anterior cerebellar WM, superior longitudinal fasciculus, and the anterior thalamic radiation (Fig 2 and Table 4). No significant association was found between the SARA scores and FA.

DISCUSSION

In this study, we used Tract-Based Spatial Statistics to assess the white matter abnormalities in a group of patients with SCA7 compared with matched healthy controls and the relationship between the white matter integrity and the ataxia severity in the patient group. Our results showed significant differences in FA

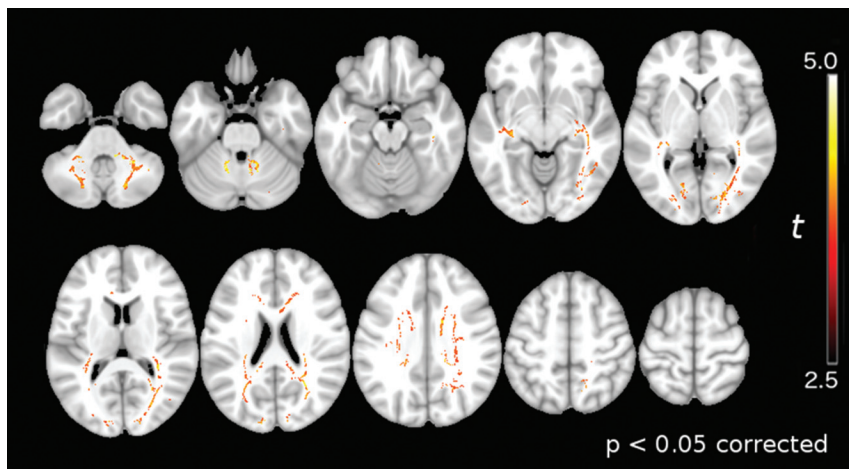


FIG 2. White matter regions where MD correlates with the SARA score in the SCA7 group. Warm colors indicate significant correlations between MD values and SARA scores.

Table 4: White matter regions showing significant correlation between MD and the SARA score in the SCA7 group^a

Anatomic Region	Voxels	T-Value	X	Y	Z
Right inferior longitudinal fasciculus	6428	6.74	40	-74	6
Right superior cerebellar peduncle	1420	9.16	7	-43	-23
Left cerebellum anterior lobule	1014	7.03	-14	-53	-28
Left inferior fronto-occipital fasciculus	684	7.89	-19	-86	-9
Right anterior thalamic radiation	239	5.92	14	-60	49
Right superior longitudinal fasciculus	158	5.54	44	-34	34
Left anterior thalamic radiation	148	10.1	-3	-9	12

^a Coordinates are in millimeters in Montreal Neurological Institute space. Labels are from the Johns Hopkins University white matter atlas.

and MD when comparing patients with SCA7 with healthy controls and a correlation between the ataxia severity and MD changes in the patient group.

Previous neuropathologic reports have shown loss of myelinated fibers in the cerebellar white matter, corpus callosum, red nucleus capsule, oculomotor nerve, lateral lemniscus, mesencephalic trigeminal tract, abducens nerve, trapezoid body, pontocerebellar fibers, pyramidal tract, internal arcuate and olivocerebellar fibers, cuneate, and gracile fascicles, as well as the spinocerebellar tracts.^{5,6} Our results support those findings but also extend them by showing abnormalities in the occipital WM, the stria terminalis, and the thalamic radiations not previously reported. As expected, the cerebellar WM and the cerebellar peduncles showed a decrease in FA and an increase of MD, implying SCA7-related microstructural changes in the afferent and efferent projections of the cerebellum. The combination of white matter degeneration and gray matter loss in the cerebellum results in a variety of clinical motor impairments, including ataxia and extrapyramidal signs.²¹ In the same way, the degeneration of the thalamic radiations affects the information flow between the cerebellum and the motor and frontal cortices, which might result in the loss of coordination and dexterity in this set of patients.

The most relevant finding of this study is the association of the white matter mean diffusivity and the ataxia severity in this group of patients. The higher correlation between MD and SARA was found in the white matter of the middle occipital gyrus, which is

involved in visual and spatial processing.^{22,23} Similarly, the superior longitudinal fasciculus showed significant correlation, which suggests a malfunction in the projections between the occipital-to-frontal cortices, including the pre-motor areas. A failure of these pathways could affect the planning and action of visuospatial tasks, especially in this disease because it has been reported to show decreases in the functional connectivity between the occipital and motor cortices.^{24,25} Future studies, including neuropsychological evaluation focused on visuospatial performance combined with ophthalmologic data, should be helpful in corroborating this hypothesis.

Other white matter regions showing significant correlation between the MD and SARA score were the superior cerebellar peduncles and the white matter in the anterior cerebellum. On the basis of the distribution of the neuropathologic changes in SCA7, this result was expected.^{5,6} Several reports have shown that lesions in these regions can lead to motor incoordination and loss of movement dexterity.²⁶ Both the cerebellar peduncles and the anterior cerebellum have been reported as degenerated in previous MR imaging studies in SCA2.^{6,24} However, in previous studies, no significant correlations were found between the changes in the water diffusion properties and SARA scores, probably due to the small number of participants recruited.⁶

No significant correlations between FA and SARA were found. FA and MD are not equivalent measurements^{27,28}; and as expected in our group comparison, FA and MD maps led to different results (Fig 1). In addition to MD and FA, other water diffusion properties such as axial diffusivity and radial diffusivity have been reported in previous studies, including SCA1, SCA2, and Friedreich ataxia.^{10,29} In this work, we focused on the analyses of FA and MD because the other measurements are subcomponents of the apparent diffusion coefficient. Furthermore, several studies of patients with neurodegenerative diseases have suggested that MD is more useful and sensitive to neurodegeneration than the other measurements.^{8,9,30}

No significant correlations between FA and SARA were found. FA and MD are not equivalent measurements^{27,28}; and as expected in our group comparison, FA and MD maps led to different results (Fig 1). In addition to MD and FA, other water diffusion properties such as axial diffusivity and radial diffusivity have been reported in previous studies, including SCA1, SCA2, and Friedreich ataxia.^{10,29} In this work, we focused on the analyses of FA and MD because the other measurements are subcomponents of the apparent diffusion coefficient. Furthermore, several studies of patients with neurodegenerative diseases have suggested that MD is more useful and sensitive to neurodegeneration than the other measurements.^{8,9,30}

CONCLUSIONS

Our results show that specific changes in the diffusion properties of white matter resulting from the SCA7 mutation are associated with the severity of the ataxia. The distribution of the mean diffusivity abnormalities and its association with SARA scores suggest a disruption of information flow between motor-, visual-, and sensory-integration areas. Overall, these findings contribute to a better understanding of the neural basis of the symptomatology of patients with SCA7.

REFERENCES

- Garden GA, La Spada AR. **Molecular pathogenesis and cellular pathology of spinocerebellar ataxia type 7 neurodegeneration.** *Cerebellum* 2008;7:138–49 CrossRef Medline
- Hugosson T, Gränse L, Ponjavic V, et al. **Macular dysfunction and morphology in spinocerebellar ataxia type 7 (SCA 7).** *Ophthalmic Genet* 2009;30:1–6 CrossRef Medline
- Miller RC, Tewari A, Miller JA, et al. **Neuro-ophthalmologic features of spinocerebellar ataxia type 7.** *J Neuroophthalmol* 2009;29:180–86 CrossRef Medline
- Michalik A, Martin JJ, Van Broeckhoven C. **Spinocerebellar ataxia type 7 associated with pigmentary retinal dystrophy.** *Eur J Hum Genet* 2004;12:2–15 CrossRef Medline
- Masciullo M, Modoni A, Pomponi MG, et al. **Evidence of white matter involvement in SCA 7.** *J Neurol* 2007;254:536–38 CrossRef Medline
- Alcauter S, Barrios FA, Diaz R, et al. **Gray and white matter alterations in spinocerebellar ataxia type 7: an in vivo DTI and VBM study.** *Neuroimage* 2011;55:1–7 CrossRef Medline
- Mori S, Zhang J. **Principles of diffusion tensor imaging and its applications to basic neuroscience research.** *Neuron* 2006;51:527–39 CrossRef Medline
- Acosta-Cabronero J, Williams GB, Pengas G, et al. **Absolute diffusivities define the landscape of white matter degeneration in Alzheimer's disease.** *Brain* 2010;133:529–39 CrossRef Medline
- Della Nave R, Ginestroni A, Tessa C, et al. **Regional distribution and clinical correlates of white matter structural damage in Huntington disease: a tract-based spatial statistics study.** *AJNR Am J Neuroradiol* 2010;31:1675–81 CrossRef Medline
- Della Nave R, Ginestroni A, Tessa C, et al. **Brain white matter damage in SCA1 and SCA2: an in vivo study using voxel-based morphometry, histogram analysis of mean diffusivity and tract-based spatial statistics.** *Neuroimage* 2008;43:10–19 CrossRef Medline
- Hernandez-Castillo CR, Galvez V, Mercadillo R, et al. **Extensive white matter alterations and its correlations with ataxia severity in SCA 2 patients.** *PLoS One* 2015;10:e0135449 CrossRef Medline
- Hernandez-Castillo CR, Vaca-Palomares I, Galvez V, et al. **Cognitive deficits correlate with white matter deterioration in spinocerebellar ataxia type 2.** *J Int Neuropsychol Soc* 2016;22:486–91 CrossRef Medline
- Li H, Ma J, Zhang X. **Diffusion tensor imaging of spinocerebellar ataxia type 12.** *Med Sci Monit* 2014;20:1783–91 CrossRef Medline
- Schmitz-Hübsch T, du Montcel ST, Baliko L, et al. **Scale for the assessment and rating of ataxia: development of a new clinical scale.** *Neurology* 2006;66:1717–20 CrossRef Medline
- Weyer A, Abele M, Schmitz-Hübsch T, et al. **Reliability and validity of the scale for the assessment and rating of ataxia: a study in 64 ataxia patients.** *Mov Disord* 2007;22:1633–37 CrossRef Medline
- Smith SM, Jenkinson M, Woolrich MW, et al. **Advances in functional and structural MR image analysis and implementation as FSL.** *Neuroimage* 2004;23:S208–19 CrossRef Medline
- Smith SM, Jenkinson M, Johansen-Berg H, et al. **Tract-based spatial statistics: voxelwise analysis of multi-subject diffusion data.** *Neuroimage* 2006;31:1487–505 CrossRef Medline
- Jenkinson M, Bannister P, Brady M, et al. **Improved optimization for the robust and accurate linear registration and motion correction of brain images.** *Neuroimage* 2002;17:825–41 CrossRef Medline
- Nichols TE, Holmes AP. **Nonparametric permutation tests for functional neuroimaging: a primer with examples.** *Hum Brain Mapp* 2002;15:1–25 CrossRef Medline
- Winkler AM, Ridgway GR, Webster MA, et al. **Permutation inference for the general linear model.** *Neuroimage* 2014;92:381–97 CrossRef Medline
- Hernandez-Castillo CR, Galvez V, Diaz R, et al. **Specific cerebellar and cortical degeneration correlates with ataxia severity in spinocerebellar ataxia type 7.** *Brain Imaging Behav* 2016;10:252–57 CrossRef Medline
- Renier LA, Anurova I, De Volder AG, et al. **Preserved functional specialization for spatial processing in the middle occipital gyrus of the early blind.** *Neuron* 2010;68:138–48 CrossRef Medline
- Martínez A, Anllo-Vento L, Sereno MI, et al. **Involvement of striate and extrastriate visual cortical areas in spatial attention.** *Nat Neurosci* 1999;2:364–69 CrossRef Medline
- Hernandez-Castillo CR, Alcauter S, Galvez V, et al. **Disruption of visual and motor connectivity in spinocerebellar ataxia type 7.** *Mov Disord* 2013;28:1708–16 CrossRef Medline
- Hernandez-Castillo CR, Galvez V, Morgado-Valle C, et al. **Whole-brain connectivity analysis and classification of spinocerebellar ataxia type 7 by functional MRI.** *Cerebellum Ataxias* 2014;1:2 CrossRef Medline
- Schmahmann JD. **Disorders of the cerebellum: ataxia, dysmetria of thought, and the cerebellar cognitive affective syndrome.** *J Neuropsychiatry Clin Neurosci* 2004;16:367–78 CrossRef Medline
- Cosottini M, Giannelli M, Siciliano G, et al. **Diffusion-tensor MR imaging of corticospinal tract in amyotrophic lateral sclerosis and progressive muscular atrophy.** *Radiology* 2005;237:258–64 CrossRef Medline
- Pierpaoli C, Barnett A, Pajevic S, et al. **Water diffusion changes in Wallerian degeneration and their dependence on white matter architecture.** *Neuroimage* 2001;13(6 pt 1):1174–85 CrossRef Medline
- Mandelli ML, De Simone T, Minati L, et al. **Diffusion tensor imaging of spinocerebellar ataxias types 1 and 2.** *AJNR Am J Neuroradiol* 2007;28:1996–2000 CrossRef Medline
- Vos SB, Jones DK, Jeurissen B, et al. **The influence of complex white matter architecture on the mean diffusivity in diffusion tensor MRI of the human brain.** *Neuroimage* 2012;59:2208–16 CrossRef Medline