



## Get Clarity On Generics

Cost-Effective CT & MRI Contrast Agents



FRESENIUS  
KABI

WATCH VIDEO

# AJNR

## Transient motor aphasia following metrizamide myelography.

J C Masdeu, G G Glista, F A Rubino, J M Martinez-Lage and E Maravi

*AJNR Am J Neuroradiol* 1983, 4 (2) 200-202

<http://www.ajnr.org/content/4/2/200.citation>

This information is current as  
of August 13, 2025.

## Transient Motor Aphasia following Metrizamide Myelography

Joseph C. Masdeu,<sup>1,2,4</sup> Glen G. Glista,<sup>1,2</sup> Frank A. Rubino,<sup>1,2</sup> J. Manuel Martinez-Lage,<sup>3</sup> Elias Maravi<sup>3</sup>

Metrizamide, a water-soluble iodinated contrast agent for myelography, has been widely used in the United States for more than 4 years. Although acute generalized encephalopathy with confusion has been recognized as a complication of metrizamide myelography, aphasia, with the connotation of focality that it entails, has seldom been reported [1, 2]. We describe two patients with a transient motor aphasia clearly related to metrizamide myelography.

### Case Reports

#### Case 1

A 56-year-old, right-handed house painter complained of intermittent low back and leg pain. He had mild coronary artery disease and hypertension, treated for 8 years with alpha-methyldopa and hydrochlorothiazide.

After premedication with 50 mg of meperidine, lumbar myelography with metrizamide (15 ml of 190 mg I/ml) was performed without difficulty. After the myelogram he was kept flat in bed. About 6–8 hr later he complained of decreased hearing and light-headedness. He then became nauseated, vomited, and perspired heavily for 1 hr. At this time his language became abnormal. He followed verbal commands well, but his speech was nonfluent. He had considerable anomia to confrontation, verbal perseveration, and impaired repetition. Motor and sensory examinations were normal. Blood pressure readings were unremarkable. The entire episode resolved over 24–30 hr. Afterward he vividly remembered having had difficulty thinking of the words he wanted to say.

The episode was misinterpreted as a focal transient ischemic attack of the left hemisphere. Pancerebral angiography revealed a 30% stenosis of the origin of the left internal carotid artery. Mild stenotic changes were also noted in the right carotid siphon, proximal portion of the angular branch of the left middle cerebral artery, and perimesencephalic portion of the left posterior cerebral artery. Contrast clearance in the left frontoparietal operculum was slightly delayed. Subsequently, an atheromatous plaque was removed through a left carotid endarterectomy, and the patient was discharged.

His original back pain and left leg pain persisted 9 months after the first myelogram, and he was readmitted to the orthopedic service. It was elected to repeat a metrizamide lumbar myelogram,

this time without premedication. Again the myelogram was obtained without complication; afterward he lay flat in bed. About 8 hr postmyelography a sequence of events identical to the one described above occurred, of about the same duration.

Computed tomography (CT) and electroencephalography (EEG) performed after the patient made a complete recovery were normal. Regional cerebral blood flow, studied by the xenon-133 inhalation method (Novo Cerebrograph), was abnormal. Gray-matter blood flow averaged 55.1 ml/min/100 g in both hemispheres. The distribution pattern showed two areas of relative hypoperfusion, one in the right frontal region and one along the left sylvian region. Within these two regions, perfusion was 40–53 ml/min/100 g (fig. 1). Blood flow in the left sylvian region was 10%–22% lower than measured in the corresponding region of the right hemisphere.

#### Case 2

A 57-year-old woman complained of progressive gait disturbance for about 5 months. Neurological examination revealed mild spastic paraparesis. Cervical myelography was performed using 10 ml of metrizamide (290 mg I/ml) injected in the lumbar region. During the procedure, metrizamide entered the cranial cavity; radiography showed slight opacification of the basal cisterns. The cervical myelogram was normal. Headache developed 7 hr after myelography, and she vomited several times. When examined 15 hr after myelography, she had a severe nonfluent aphasia with marked anomia, but she followed instructions readily. In addition, she had a left supranuclear facial palsy, with impairment of voluntary facial movements; automatic facial movements were spared. EEG showed bilateral slowing of the background rhythm, with episodic bursts of delta activity, most pronounced over the left perisylvian region. She gradually improved, and by 24 hr after myelography her language had reverted to normal and the left facial weakness had disappeared. Repeated EEG was normal.

### Discussion

The most frequently reported complications of metrizamide myelography are headache and other meningeal symptoms [3–5]. Transient memory loss and depression [6], as well as long-lasting confusion related to hydrocephalus [7],

Received January 14, 1982; accepted after revision October 18, 1982.

This work was supported by the Medical Research Service of the Veterans Administration.

<sup>1</sup> Neurology Service (127), Hines Veterans Administration Hospital, Hines, IL 60141. Address reprint requests to F. A. Rubino.

<sup>2</sup> Departments of Neurology and Pathology, Loyola University of Chicago, Stritch School of Medicine, Maywood, IL 60153.

<sup>3</sup> Department of Neurology, University of Navarre, Pamplona, Spain.

<sup>4</sup> Present address: Department of Neurology, Montefiore Hospital and Medical Center, Bronx, NY 10467.

**AJNR 4:200–202, March/April 1983** 0195–6108/83/0402–0200 \$00.00 © American Roentgen Ray Society



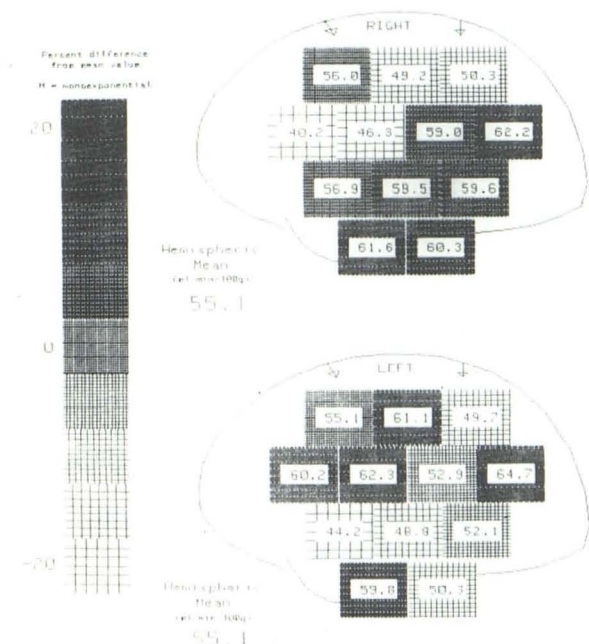


Fig. 1.—Case 1. Gray matter blood flow (fg or fl) in right and left hemispheres. Detectors on left sylvian region recorded values 10%–20% lower than recorded by homologous detectors over right hemisphere. On left side, detector 6 recorded absolute value of 44.2 ml/min/100 g of tissue and detector 10 recorded value of 48.8 ml/min/100 g.

have also been described. Occasionally metrizamide causes an acute encephalopathy, which in most cases can be easily recognized as generalized [8–11]. However, as illustrated by our cases, it may present with signs suggestive of focal dysfunction.

Both patients developed an aphasic syndrome, which was time-related to metrizamide myelography. Several mechanisms can be postulated to explain these episodes. Intrathecal metrizamide has been shown to induce seizures in experimental animals [12]. EEG changes, including slowing and, less often, epileptiform activity, have been detected in 16%–35% of patients after metrizamide myelography [13–15]. Although no focal symptoms were reported, in a small number of these patients the EEG changes were lateralized. Concomitant with altered mental status, the EEG of three recently reported patients became markedly abnormal [9, 11]. In addition to generalized slowing, the EEG of our Case 2 showed focal dysfunction on the left sylvian region. Direct neurotoxicity of metrizamide may explain the aphasic syndrome in both of our patients. Brain swelling and a high cortical content of metrizamide within 24 hr after metrizamide myelography have been reported [16]. The symptomatology of our patients peaked with a similar timing after myelography. In the first case, failing to keep the head elevated after lumbar myelography probably contributed to the development of this complication by rapidly increasing the intracranial concentration of metrizamide [9, 17].

Our cases bear striking resemblance to the two cases reported by Böker et al [1]. As the cause of their patient's transient aphasia, they postulated prolonged contact of

metrizamide with a brain already damaged by a vascular abnormality. Neither of their patients, however, was evaluated by angiography or regional cerebral blood flow studies. Of interest, the cerebral blood flow study in our case 1 showed diminished perfusion of the left perisylvian region.

Several studies have documented the reproducibility of cerebral blood flow measurements obtained with equipment similar to that used for the study of case 1 [18–20]. Interhemispheric differences are particularly reproducible. Considering the normative data (71 volunteers aged 15–69; Wilson D, unpublished observations) from the laboratory that determined cerebral blood flow for our first patient, the low perfusion recorded over his left sylvian region is unlikely to be related to chance. In our patient, interhemispheric differences for the sylvian detectors were 12.7 ml/min/100 g for detector 6 (normals, 3 ml; SD, 5) and 10.7 ml/min/100 g for detector 10 (normals, 1.7 ml; SD, 5.6). Clustering of abnormal values to a group of detectors enhances the reliability of this finding. Although the cerebral blood flow measurements were performed after the patient had already had myelography, it is most likely that the same situation of decreased perfusion of the left perisylvian region was present before myelography. Thus, this case seems to support the view of Böker et al.

There is a controversy about the action of iodinated contrast materials upon the vasculature of the brain. Foltz et al. [21] reported transient severe vasospasm of the pial arterioles in monkeys after the intracarotid injection of contrast material [21]. Their technique involved direct visualization of the cortex, but as Hilal [22] noted, systemic blood pressure during the procedure was not recorded. Other authors were unable to duplicate their findings. [23, 24]. In a recent study arteriolar constriction was observed in the rabbit omentum 5 min after the intravenous injection of methylglucamine diatrizoate 60% [25]. Although no similar studies are available after the intrathecal injection of metrizamide, it could be postulated that the contrast material, in contact with the adventitia of the pial vessels, may cause transient vasospasm. In our case 1, the left perisylvian region, with a diminished basal cerebral blood flow due to focal atheromatous disease of intracranial arteries, might have been affected more than the rest of the brain by such a process. An alternate explanation need not postulate vasospasm. Position emission tomography has shown that viable areas of the brain may have impaired blood flow but normal oxygen metabolism [26]. Such ischemic, but essentially metabolically normal areas may be rendered functionally incompetent by an increased metabolic load. Water-soluble contrast materials are known to enhance the evoked corticospinal responses [12]. Hypersynchrony and spikes observed in the EEG of patients after metrizamide myelography would also suggest transiently increased neuronal activity [9, 15]. Moreover, metrizamide in high concentration competes with glucose for hexokinase [27]. An area taxed by relative ischemia may not be able to meet these increased metabolic demands, and focal neurologic signs ensue.

Systemic hypotension might be postulated to explain a transient neurologic deficit related to myelography. Nevertheless, systemic hypotension has seldom been reported after metrizamide myelography [5, 28, 29]. In our cases,



blood pressure remained normal during the postmyelography episodes.

Although metrizamide is the best tolerated water-soluble contrast material available for myelography, it may cause an acute encephalopathy. Occasionally metrizamide encephalopathy may present with signs suggestive of a focal lesion, as exemplified by our cases.

## REFERENCES

1. Böker DK, Sartor K, Winkler D. Motorische Aphasie nach zervikaler Myelographie mit Metrizamid. *ROFO* 1980;133:204-207
2. Picard L, Vespignani H, Vieux-Rochat P, et al. Complications neurologiques graves des myélographies au métrizamide. *J Neuroradiol* 1979;6:3-14
3. Gelmers HJ. Adverse side effects of metrizamide in myelography. *Neuroradiology* 1979;18:119-123
4. Gonsette RE. Advance in ventriculography and myelography with the non-ionic contrast medium metrizamide. *Acta Radiol [Suppl]* (Stockh) 1975;347:467-476
5. Kieffer SA, Binet EF, Esquerre JV, et al. Contrast agents for myelography: clinical and radiological evaluation of Amipaque and Pantopaque. *Radiology* 1978;129:695-705
6. Richert S, Sartor K, Holl B. Subclinical organic psychosyndromes on intrathecal injection of metrizamide for lumbar myelography. *Neuroradiology* 1979;18:177-184
7. Kelley RE, Daroff RB, Sheremata WA, McCormick JR. Unusual effects of metrizamide lumbar myelography. *Arch Neurol* 1980;37:588-589
8. Rubin B, Horowitz G, Katz RI. Asterix following metrizamide myelography. *Arch Neurol* 1980;37:522
9. Russell D, Anke IM, Nyberg-Hansen R, Slettness O, Sortland O, Veger T. Complex partial status epilepticus following myelography with metrizamide. *Ann Neurol* 1980;8:325-327
10. Schmidt RC. Mental disorders after myelography with metrizamide and other water-soluble contrast media. *Neuroradiology* 1980;19:153-157
11. Vincent FM, Zimmerman JE. Metrizamide encephalopathy. *Ann Neurol* 1980;7:494
12. Hilal SK, Dauth GW, Hess KH, Gilman S. Development and evaluation of a new water-soluble iodinated myelographic contrast medium with markedly reduced convulsive effects. *Radiology* 1978;126:417-422
13. Ahlgren P. Amipaque myelography. The side effects compared with Dimer-X. *Neuroradiology* 1975;9:197-202
14. Kaada B. Transient EEG abnormalities following lumbar myelography with metrizamide. *Acta Radiol [Suppl]* (Stockh) 1973;335:380-385
15. Ropper AH, Chiappa KH, Young RR. The effect of metrizamide on the electroencephalogram: a prospective study in 61 patients. *Ann Neurol* 1979;6:222-226
16. Cala LA. Cerebral absorption of metrizamide. *Lancet* 1981;2:922-923
17. Gulati AN, Guadagnoli DA, Quigley JM. Relationship of side effects to patient position during and after metrizamide lumbar myelography. *Radiology* 1981;141:113-116
18. Blauenstein UW, Halsey Jr. JH, Wilson EM, Wills EL, Risberg J. Xenon inhalation method. *Stroke* 1977;8:92-102
19. Prohovnik I, Hakansson K, Risberg J. Observations on the functional significance of regional cerebral blood flow in "resting" normal subjects. *Neuropsychologia* 1980;18:203-217
20. Risberg J. Regional cerebral blood flow measurements by <sup>133</sup>Xe inhalation: methodology and applications in neuropsychology and psychiatry. *Brain Lang* 1980;9:9-34
21. Foltz EL, Thomas LB, Ward Jr AA. The effects of intracarotid diodrast. *J Neurosurg* 1952;9:68-82
22. Hilal SK. Hemodynamic changes associated with the intra-arterial injection of contrast media. *Radiology* 1966;86:615-633
23. Margolis G, Griffin AF, Kenan PD, Tindall GT, Riggins R, Fort L. Contrast medium injury to spinal cord. *J Neurosurg* 1959;16:390-406
24. Schmidt HW. The behaviour of the pial vessels during and after the intracarotid injection of roentgen contrast media. *Acta Radiol [Suppl]* (Stockh) 1955;44:101-108
25. Endrich B, Ring J, Intaglietta M. Effects of radiopaque contrast media on the microcirculation of the rabbit omentum. *Radiology* 1979;132:331-339
26. Ackerman RH, Correia JA, Alpert NM, et al. Positron imaging in ischemic stroke disease using compounds labeled with oxygen 15. *Arch Neurol* 1981;38:537-543
27. Bertoni JM, Schwartzman RJ, Van Horn G, Partin J. Asterix and encephalopathy following metrizamide myelography: investigations into possible mechanisms and review of the literature. *Ann Neurol* 1981;9:366-370
28. Sortland O, Lundervold A, Svar A, Hauglie-Hanssen E. Metrizamide in radiography of the central nervous system. *Acta Radiol [Suppl]* (Stockh) 1975;347:477-487
29. Sackett JF, Strother CM, Quaglieri CE, Javid MJ, Levin AB, Duff TA. Metrizamide-CSF contrast medium. *Radiology* 1977;123:779-782