

Generic Contrast Agents

Our portfolio is growing to serve you better. Now you have a *choice*.



[VIEW CATALOG](#)

AJNR

This information is current as of May 21, 2025.

Neck Location on the Outer Convexity is a Predictor of Incomplete Occlusion in Treatment with the Pipeline Embolization Device: Clinical and Angiographic Outcomes

T. Sunohara, H. Imamura, M. Goto, R. Fukumitsu, S. Matsumoto, N. Fukui, Y. Oomura, T. Akiyama, T. Fukuda, K. Go, S. Kajiura, M. Shigeyasu, K. Asakura, R. Horii, C. Sakai and N. Sakai

AJNR Am J Neuroradiol 2021, 42 (1) 119-125

doi: <https://doi.org/10.3174/ajnr.A6859>

<http://www.ajnr.org/content/42/1/119>

Neck Location on the Outer Convexity is a Predictor of Incomplete Occlusion in Treatment with the Pipeline Embolization Device: Clinical and Angiographic Outcomes

T. Sunohara, H. Imamura, M. Goto, R. Fukumitsu, S. Matsumoto, N. Fukui, Y. Oomura, T. Akiyama, T. Fukuda, K. Go, S. Kajiura, M. Shigeyasu, K. Asakura, R. Horii, C. Sakai, and N. Sakai



ABSTRACT

BACKGROUND AND PURPOSE: With the increasing use of the Pipeline Embolization Device for the treatment of aneurysms, predictors of clinical and angiographic outcomes are needed. This study aimed to identify predictors of incomplete occlusion at last angiographic follow-up.

MATERIALS AND METHODS: In our retrospective, single-center cohort study, 105 ICA aneurysms in 89 subjects were treated with Pipeline Embolization Devices. Patients were followed per standardized protocol. Clinical and angiographic outcomes were analyzed. We introduced a new morphologic classification based on the included angle of the parent artery against the neck location: outer convexity type (included angle, $<160^\circ$), inner convexity type (included angle, $>200^\circ$), and lateral wall type ($160^\circ \leq$ included angle $\leq 200^\circ$). This classification reflects the metal coverage rate and flow dynamics.

RESULTS: Imaging data were acquired in 95.3% of aneurysms persistent at 6 months. Complete occlusion was achieved in 70.5%, and incomplete occlusion, in 29.5% at last follow-up. Multivariable regression analysis revealed that 60 years of age or older (OR, 5.70; $P = .001$), aneurysms with the branching artery from the dome (OR, 10.56; $P = .002$), fusiform aneurysms (OR, 10.2; $P = .009$), and outer convexity-type saccular aneurysms (versus inner convexity type: OR, 30.3; $P < .001$; versus lateral wall type: OR, 9.71; $P = .001$) were independently associated with a higher rate of incomplete occlusion at the last follow-up. No permanent neurologic deficits or rupture were observed in the follow-up period.

CONCLUSIONS: The aneurysm neck located on the outer convexity is a new, incomplete occlusion predictor, joining older age, fusiform aneurysms, and aneurysms with the branching artery from the dome. No permanent neurologic deficits or rupture was observed in the follow-up, even with incomplete occlusion.

ABBREVIATIONS: MCR = metal coverage ratio; PED = Pipeline Embolization Device

Flow-diversion stents with the Pipeline Embolization Device (PED; Medtronic) were first reported in 2008.¹ Since then, multiple trials^{2–6} and retrospective studies^{3,7,8} have reported the safety and efficacy of the PED in the treatment of intracranial aneurysms. Long-term follow-up data showed a 95.2% occlusion rate at 5 years after treatment^{3,8} and no evidence of recanalization of previously occluded aneurysms.³ Angiographic and clinical long-term follow-up data are important because incomplete occlusion leads to retreatment or rerupture in coil embolization.⁹

Several factors such as age, sex, smoking, fusiform-type aneurysms, small aspect ratios, and dome-neck ratios have been reported


to be predictors of incomplete or complete occlusion.^{10–17} However, there is debate about outcomes when using these factors because of limited analysis of the confounding factors. Moreover, the follow-up imaging rate of incomplete occlusion is sometimes insufficient (around 50% at 6 months).¹ Additionally, the same morphologic indices used in coil embolization were used in previous PED studies, even though the 2 methods are different in their treatment mechanism for aneurysms. The metal coverage ratio (MCR)^{18–20} is an important metric of PED treatment.

Although the MCR correlates with the occlusion rate,¹⁹ it is calculated after treatment and additional work-up is needed to acquire it. Therefore, in this study, we introduced a new classification based on the included angle of the parent artery against the neck location for the aneurysm, which can be measured before the PED treatment and complements the MCR: outer convexity type, inner convexity type, and lateral wall type. In addition, we clarified factors, including our new classification, affecting incomplete occlusion and clinical

Received June 10, 2020; accepted after revision August 11.

From the Department of Neurosurgery, Kobe City Medical Center General Hospital, Kobe, Japan.

Please address correspondence to Tadashi Sunohara, MD, PhD, Kobe City Medical Center General Hospital, Department of Neurosurgery, 2-1-1 Minami-cho, Minatojima, Chuo-ku, Kobe, 650-0047, Japan; e-mail: tadashi_sunohara@kcho.jp

 Indicates article with supplemental online tables.

<http://dx.doi.org/10.3174/ajnr.A6859>

outcome in PED treatment, on the basis of data with a high follow-up rate.

MATERIALS AND METHODS

Study Design

A retrospective analysis of consecutive aneurysms treated with PED placement between July 2015 and July 2019 at a single institution was performed. The inclusion criteria consisted of all adult patients with intracranial unruptured aneurysms treated with the PED who had undergone angiographic follow-up. All aneurysm morphologies (ie, saccular, fusiform, and so forth) and intracranial locations were included. Institutional review board approval was obtained at the center before commencement of the study. Informed consent was obtained in the form of an opt-out on the Web site. Those who opted out were excluded from the study (0 patients). We collected the following information: patient demographics, aneurysm and PED characteristics, procedural complications, and angiographic and functional outcomes.

Procedural Details

Patients received aspirin, 100 mg, and clopidogrel, 75 mg daily, for 10–14 days before the intervention. Platelet function testing was routinely performed with the VerifyNow P2Y12 assay and the VerifyNow Aspirin assay (Accumetrics) on the day before the procedure. Clopidogrel nonresponders were identified on the basis of established cutoff values of >220 , and aspirin nonresponders, of >550 . If a patient was identified as a clopidogrel responder, the clopidogrel was continued. If a patient was identified as a clopidogrel nonresponder, the treatment was switched to prasugrel, 3.5 mg daily, with a 1-time loading dose of 20 mg administered 24 hours before the procedure. If a patient was identified as an aspirin nonresponder, the daily dose of aspirin was increased to 200 mg. Dual-antiplatelet therapy was continued for at least 6 months after the procedure, and single-antiplatelet therapy was continued indefinitely thereafter.

Patients were under general anesthesia, and all patients were anticoagulated with heparin throughout the procedure. The 8F guiding catheter, 5F Navien (Medtronic) distal-access catheter, and a Marksman (Medtronic) microcatheter were used in a coaxial system as a standard combination at the institute.

Angiographic Outcome

Angiographic outcome was assessed with DSA or MRA on the basis of the follow-up protocol. At 6 months after the procedure, all patients and aneurysms were assessed with DSA. If aneurysms were completely occluded at DSA, a follow-up assessment was performed with MRA 6–12 months thereafter. In the case of partial occlusion at DSA, follow-up DSA was performed 3–6 months later. In the case of nearly complete occlusion at DSA, follow-up DSA or MRA was performed 3–6 months later at the discretion of the operator.

Aneurysm occlusion on the follow-up DSA was assessed by trained interventionalists. Follow-up MRA was assessed by a radiologist blinded to the clinical history and a trained interventionalist. Occlusion was categorized as complete occlusion (100%), near-complete occlusion (90%–99%), and partial occlusion ($<90\%$) at DSA or MRA. Both near-complete and partial occlusion were collectively defined as incomplete occlusion.

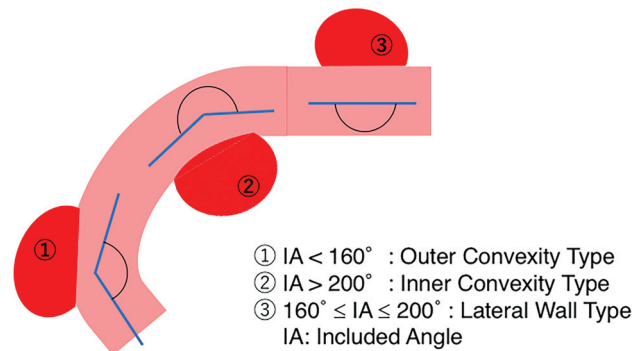


FIGURE. Classification of saccular aneurysms.

Classification of Saccular Aneurysms

Saccular aneurysms were classified into 3 subtypes based on the included angle of the parent artery against the neck location. The included angle is the angle formed by the arc of the internal carotid artery against the aneurysm neck location. The angle was measured by 2 workstations (Xtra Vision R1.3.2, Philips Healthcare, and SYNAPSE VINCENT V5.2, Fujifilm), and the aneurysm was categorized as outer convexity (included angle, $<160^\circ$), inner convexity (included angle, $>200^\circ$), or lateral wall ($160^\circ \leq$ included angle $\leq 200^\circ$) (Figure).

Clinical Outcome

Functional outcome was assessed with the mRS at each follow-up by the neurosurgeon and interventionalist.

Statistical Analysis

Statistical analysis was performed with JMP software, Version 10 (SAS Institute). In the univariable analysis, variables were compared among groups with the nonparametric test for continuous variables and the χ^2 test for categorical variables to identify predictors of incomplete occlusion and bad neurologic outcome. Statistical significance was defined as $P < .05$. Multivariable logistic regression was performed on candidate predictor variables to identify variables independently associated with incomplete occlusion and clinical outcome at the last angiographic follow-up after controlling for potential confounders.

Baseline and Aneurysm Characteristics

A total of 108 sequential aneurysms treated with PED placement at a single institution were identified. Of these, 105 (97.2%) aneurysms treated by 91 PED procedures in 89 patients (median age, 58 years; female/male ratio, 4.9:1) had angiographic follow-up and were included in this study. All treatments were for unruptured aneurysms. Aneurysms were along the ICA. The locations and measurements are shown in Table 1. Aneurysms including the branching artery from the dome were present in 15.2%. The morphologic types of saccular aneurysms were composed of the outer convexity type in 35.7%, inner convexity type in 29.6%, and lateral wall type in 34.7%. Among patients, 28.6% exhibited symptoms from cranial nerve compression before treatment (Table 1).

Table 1: Baseline characteristics of aneurysms and patient demographics

	Value
Patients (<i>n</i> = 89)	
Age (yr)	
Median (range)	58 (20–88)
Sex	
Female	74 (83.1%)
Male	15 (16.9%)
Current smoking	30 (28.6%)
Pretreatment mRS	
0–2	89 (100%)
3–5	0 (0%)
Symptomatic cranial nerve compression	26 (28.6%)
Aneurysms (<i>n</i> = 105)	
Measurements (mm)	
Median (range)	
Maximum diameter	10.5 (2–33)
Neck size of saccular aneurysms	6.4 (2–14)
Height of saccular aneurysms	6.0 (0.9–28)
Aneurysm type	
Saccular	98 (93.3%)
Fusiform	7 (6.7%)
Aneurysm location	
ICA petrous	4 (3.8%)
ICA cavernous	31 (29.5%)
ICA paraclinoid	58 (55.2%)
ICA C1 segment	12 (11.4%)
Branching artery from dome	16 (15.2%)
Multiple aneurysms	13 (14.3%)
Morphologic types of saccular aneurysm	
Outer convexity	35 (35.7%)
Inner convexity	29 (29.6%)
Lateral wall	34 (34.7%)
Procedures (<i>n</i> = 91)	
No. of Pipelines	
1	90 (98.9%)
2	1 (1.1%)

Treatment Outcome

The median length of the angiographic follow-up was 27 months (range, 9–60 months). All patients (89 patients, 105 aneurysms) had 6-month angiographic follow-up. Table 2 shows the occlusion rate at 6-months after treatment and at the last follow-up. The long-term imaging follow-up rate of patients with incomplete occlusion at 6-month DSA was 95.3% (41/43). The median length of the angiographic follow-up of patients with incomplete occlusion at 6-month DSA was 27.5 months (range, 10–54 months). An adjunctive coil was used in 33.3% of aneurysms, most of which were intradural aneurysms. Retreatment was performed in 5.5% of aneurysms and was exclusively endovascular. The mRS scores just after PED placement were 0–2 in 94.4% of procedures and 3–5 in 5.6% because of ischemic stroke or the worsening of cranial nerve compression. At the last follow-up, the mRS scores were improved in 18.0% of patients. Improvement included pre-existing cranial nerve compression symptoms or postprocedural symptomatic stroke. Symptomatic neurologic complications appeared in 7.7% of procedures. Symptomatic thromboembolic complications were encountered in 6.6% of procedures, and symptomatic hemorrhagic complications, in 0%. In 1 case, a symptom of cranial nerve compression appeared after treatment because of a thrombosing aneurysm. In 37.0%, cranial nerve compression was improved in the

Table 2: Outcome measures

	Value
Platelet function test	
Yes	89 (100%)
No	0 (0%)
Clopidogrel responder	
Yes	66 (74.2%)
No	23 (25.8%)
Angiographic outcome	
Imaging follow-up	
Median (range) (mo)	27 (9–60)
Data availability	89/92 (96.7%)
Long-term imaging follow-up rate with aneurysm persistent at 6 mo	41/43 (95.3%)
Occlusion rate at 6 mo	
Complete (100%)	62 (59.0%)
Near-complete (90%–99%)	20 (19.0%)
Partial (<90%)	23 (22.0%)
Occlusion rate at last follow-up	
Complete (100%)	74 (70.5%)
Near-complete (90%–99%)	17 (16.2%)
Partial (<90%)	14 (13.3%)
Adjunctive coil	35 (33.3%)
Retreatment	5 (5.5%)
Clinical outcome	
Posttreatment mRS	
0–2	84 (94.4%)
3–5	5 (5.6%)
6 (death)	0 (0%)
mRS at last follow-up	
Improved	16 (18.0%)
No change	73 (82.0%)
Worsened	0 (0%)
Neurologic complications	
Thromboembolic	40 (44.0%)
Symptomatic	6 (6.6%)
Hemorrhagic	3 (3.3%)
Symptomatic	0 (0%)
Symptomatic cranial nerve compression	1 (1.1%)
Long-term outcome	
Rupture of aneurysm at follow-up	0 (0%)
Compression improved at follow-up	10 (37.0%)
Permanent neurologic complication	0 (0%)
Permanent neurologic death	0 (0%)

follow-up period. The mortality rate was 0%, the postprocedural morbidity rate was 7.7%, and the permanent morbidity rate was 0% (Table 2).

Predictor of Incomplete Occlusion

The following factors were tested as predictors of aneurysm occlusion: age, sex, current smoker/nonsmoker, aneurysm type (saccular or fusiform), complications, maximum dome diameter of the aneurysm, neck diameter, aneurysm height, dome/neck ratio, ASPECTS ratio, adjunctive coil usage, presence of aneurysms with the branching artery from the dome, and the classification of the saccular aneurysm. By means of a univariable analysis, age (older than 60 years, $P = .002$), fusiform aneurysms ($P = .012$), aneurysms with the branching artery from the dome ($P < .001$), and outer convexity type ($P < .001$) were associated with significantly higher rates of incomplete occlusion at the last follow-up (Online Table 1).

Table 3: Multivariable regression analysis of predictors for incomplete occlusion at last follow-up overall^a

	OR	95% CI	P Value
Age (≥ 60 years)	5.70	1.99–19.5	.001
Branching artery from dome	10.56	2.36–63.2	.002
Fusiform	10.23	1.77–86.3	.009
Type			
OC/IC	30.3	4.96–595	<.001
OC/LW	9.71	2.45–52.0	.001
LW/IC	3.12	0.31–70.4	.34

Note:—OC indicates outer convexity-type saccular aneurysm; IC, inner convexity-type saccular aneurysm; LW, lateral wall-type saccular aneurysm.

^a $n = 105$; complete occlusion, 74; incomplete occlusion, 31. Significant predictors of incomplete occlusion include age older than 60 years, aneurysms with the branching artery from the dome, fusiform aneurysm, and outer convexity type.

Table 4: Multivariable regression analysis for incomplete occlusion using outer convexity type and aneurysms with a branching artery

Parameter	OR	95% CI	P Value
Outer convexity type (+) and branch (+)	162	21.5–3587	<.001
Outer convexity type (+) and branch (–)	16.6	4.54–81.2	<.001
Outer convexity type (–) and branch (+)	9	1–73.2	.05
Outer convexity type (–) and branch (–)	1	–	–

Note:—Branch indicates aneurysm with branching artery from dome; –, not applicable..

The significant predictors of incomplete occlusion at the last follow-up in the univariable analysis were further analyzed with a multivariable logistic regression. Age (older than 60 years; OR, 5.70; 95% CI, 1.99–19.5; $P = .001$), aneurysms with the branching artery from the dome (OR, 10.56; 95% CI, 2.36–63.2; $P = .002$), fusiform aneurysms (OR, 10.23; 95% CI, 1.77–86.3; $P = .009$), and outer convexity-type saccular aneurysms (versus inner convexity type: OR, 30.3; 95% CI, 4.96–595; $P < .001$; versus lateral wall type: OR, 9.71; 95% CI, 2.45–52.0; $P = .001$) were independently associated with a higher rate of incomplete occlusion at the last follow-up (Table 3). The number of each occlusion status per aneurysm type is shown in Online Table 2.

Among the 16 aneurysms with a branching artery from the dome, 10 aneurysms were the outer convexity type. Among the 35 outer convexity-type aneurysms, 10 aneurysms had the branching artery from the dome. Although multivariable logistic regression revealed that outer convexity-type and aneurysms with the branching artery from the dome were independent predictors of incomplete occlusion, there is a possible interaction between these 2 factors; therefore, further analysis was performed (Table 4). On the basis of double-negative aneurysms as a reference, aneurysms of the outer convexity type with the branching artery from the dome (OR, 162; 95% CI, 21.5–3587; $P < .001$) were most susceptible to becoming an incomplete occlusion, followed by outer convexity-type aneurysms without the branching artery from the dome (OR, 16.6; 95% CI, 4.54–81.2; $P < .001$) and non-outer convexity-type aneurysms with the branching artery from the dome (OR, 9.0; 95% CI, 1.0–73.2; $P = .05$).

Predictor of Bad Clinical Outcomes

The posttreatment mRS was 0–2 in 94.4% (84/89) of procedures and 3–5 in 5.6% (5/89). The complications of deteriorated mRS

included symptomatic thromboembolic strokes and newly appearing cranial nerve neuropathy due to thrombosing aneurysms. No major thromboembolic strokes occurred, and all patients were improved at 6-month follow-up. The follow-up mRS score was improved in 18% (16/89) and showed no change in 82% (73/89). These improvements included not only symptomatic thromboembolic strokes but also cranial nerve neuropathy caused by compression due to large/giant aneurysms. The mRS at the final follow-up was 0–2 in all patients. The permanent neurologic complication rate was 0%, and the permanent neurologic death was 0%. In the long-term follow-up, no aneurysms were ruptured despite incomplete occlusion (Table 2).

DISCUSSION

In this study, we assessed predictors of incomplete occlusion and clinical outcome on the basis of high-follow-up-rate data. Several factors affecting complete/incomplete occlusion rates were previously reported (Online Table 3).^{10–13,15,16,21–26} However, these previous reports disagree about these predictors due to the limited analysis of confounding factors for each candidate predictor and an insufficient follow-up

rate for incomplete occlusion cases. Additionally, the same morphologic index based on coil embolization was used in these analyses, even though the PED and coil embolization use different mechanisms to treat aneurysms.^{11,17}

In the present study, we included previously reported factors as much as possible to assess the possibility of confounding factors. Additionally, we added the type of saccular aneurysm based on the location of the neck of the aneurysm against the arterial curvature as a morphologic factor. This new classification indirectly reflects the MCR, which is the major index of the occlusion mechanism of PED^{18–20} and was reported to correlate with complete occlusion.^{18,19}

On the basis of our multivariable regression analysis, in addition to age (older than 60 years; OR, 5.70; $P = .001$), fusiform aneurysms (OR, 10.23; $P = .009$), and aneurysms with the branching artery from the dome (OR, 10.56; $P = .002$), outer convexity-type saccular aneurysms (versus inner convexity type: OR, 30.3; $P < .001$; versus lateral wall type: OR, 9.71; $P = .001$) were independently associated with a higher rate of incomplete occlusion at the last follow-up. Further analysis found an interaction between outer convexity-type aneurysms and aneurysms with the branching artery from the dome and that this interaction (OR, 162; $P < .001$) was most susceptible to becoming an incomplete occlusion, followed by outer convexity-type aneurysms without the branching artery from the dome (OR, 16.6; $P < .001$) and non-outer convexity-type aneurysms with the branching artery from the dome (OR, 9.0; $P = .05$).

Our study is based on a single-center consecutive retrospective cohort. Among patients, 96.7% (89/92) had DSA at 6 months after treatment. The long-term imaging follow-up rate for aneurysms with incomplete occlusion at 6 months was 95.3% (41/43), and the median length of imaging follow-up for patients with

incomplete occlusion at 6-month DSA was 27.5 months (range, 10–54 months). Each factor affecting our findings is discussed below.

Predictors of Aneurysm Occlusion

Type of Neck Location Related to Variation in Occlusion Rates. No previous report has proposed our saccular aneurysm classification with regard to the PED. The advantage of this classification is that it is simple and needs minimal, if any, software or calculations.

According to the mechanisms of aneurysm occlusion by PED previously reported,^{18–20,27–29} hemodynamics^{30–36} and endothelialization^{29,37–41} are key factors and MCR and porosity are key indices for successful PED treatment. Our classification based on the curvature of the parent artery indirectly reflects the MCR and flow dynamics around the neck of the aneurysm and relates to the aneurysmal occlusion. MCR and porosity are the major indices of the occlusion mechanism of the PED and inverses of each other.^{18–20,37–39,42} The MCR is the portion of the ostium of the aneurysm covered by the metal of the flow diverter.²⁰ In general, devices with a higher MCR provide a better scaffold for endothelialization.^{39–41}

Two studies^{18,19} reported that the local metal coverage of the stent at the aneurysmal neck correlates with the occlusion of the aneurysm; a 35% metal coverage at the neck predicted >95% angiographic aneurysm occlusion with a specificity of 100% and sensitivity of 53.8%. The PED is designed to have an MCR of 30%. However, the MCR will change with the angle of the PED. Wang and Yuan¹⁸ reported the relationship between the MCR and the bending angle of the PED, showing that the MCR could range from 19% to 63%, depending on the angle. Additionally, the MCR would become lower, and the porosity, higher in the outer convexity compared with their values in the inner concavity of the curvature of the parent artery.^{20,42–44} On the basis of those previous studies, we estimated that the local MCR around the neck of the aneurysm in the outer convexity type is <30%. We estimated the MCR to be >35% for the inner convexity type and lateral wall type, though the MCR tends to be higher for the inner convexity.^{43,44} Therefore, our new classification of saccular aneurysms indirectly reflects the MCR around the aneurysmal neck and has an effect on the occlusion rate.

A neck location with outer convexity is also disadvantageous for PED treatment from the viewpoint of hemodynamics. From a computational fluid dynamics analysis, successful flow diversion depends on the following: 1) the flow resistance force of the flow diverter to decrease the flow velocity magnitude,³⁰ 2) decreased jet flow into the aneurysm,³¹ 3) the aneurysm neck geometry,³¹ and 4) the patient-specific inflow threshold³² and other parameters such as the inflow rate, aneurysmal velocity reduction, and so forth.³³ The flow velocity is faster at the outer convex side of a curved vessel than at the inner concave side, and the flow vector is toward the aneurysm in the outer convexity type.^{34,35} Therefore, the flow velocity magnitude and the jet flow into the aneurysm are higher in the outer convexity type than in other types of saccular aneurysms.

According to a computational fluid dynamics analysis of flow diverters,³⁶ the velocity magnitude of the inflow stream of the aneurysm sac and the inflow volume rate increase as the curvature of the parent artery increases and are higher if the curvature angle is large

after the flow-diverter placement.³⁶ That study provides a theoretic explanation for why the outer convexity type resists complete occlusion compared with inner convexity and lateral wall types.

An overlapped flow-diverter placement was reported to be effective in decreasing the inflow volume rate, to overcome the possibility of incomplete occlusion in the outer convexity type.³⁶ Technical manipulation is also recommended, such as a dynamic push-pull technique over the aneurysm orifice, which enhances the intended flow diversion, to compensate for the low MCR with the outer convexity type.⁴⁵

Age-Related Variation of Occlusion Rates

Our data also showed that older age was one of the predictor of incomplete occlusion, consistent with a previous report.¹⁰

The mechanism of occlusion in PED-treated aneurysms, as mentioned above, could account for why older age was a predictor. The migration of endothelial cells slows with age,⁴⁶ slowing endothelialization of the PED. Furthermore, atherosclerosis, which is also more common in older patients, could also contribute because the irregular shape of the endoluminal surface of the artery could form a gap between the endoluminal surface of the artery and the PED, resulting in an endoleak to the aneurysm through the nonendothelialized area.¹¹

Branch-Related Variations in Occlusion Rates

Aneurysms with the branching artery from the dome being a solid predictor of incomplete occlusion is consistent with several reports.^{22–26} The ophthalmic artery, posterior communicating artery, and anterior choroidal artery were all relevant in our series. In cases of aneurysms with the branching artery from the dome, when the branch has blood demand, blood flow through the PED inhibits endothelialization, resulting in remnant flow to the aneurysm and incomplete occlusion. Notably, this factor was independent from and had interaction with the type of neck location.

Fusiform or Saccular Variation in Occlusion Rates

Our data also showed that fusiform aneurysms were a significant predictor of incomplete occlusion compared with saccular aneurysms, consistent with previous studies.^{11,16,25} The reason could be the occlusion mechanisms of the PED. In the case of fusiform aneurysms, a wider surface area of the PED is exposed to the aneurysm without support by the vessel wall compared with saccular aneurysms. These areas are more likely to be devoid of endothelialization.⁴⁷

Predictor of Clinical Outcome

We also assessed predictors of the clinical outcome; however, no ruptures of aneurysms were observed in the follow-up periods. These findings indicate that aneurysms treated with the PED are clinically safe and stable, even with aneurysm remnants, as reported previously.¹²

Limitations

The limitations of the study include its retrospective design with all the inherent biases associated with such a study design. Although this study is from a single center and thus warranted a unified treatment procedure, antiplatelet regimen, and follow-up imaging protocol, the retrospective nature of this study and

analysis from a single center introduce sampling bias and possibly limit external validity.

Twelve aneurysms with incomplete occlusion had follow-ups of <2 years. The possibility for these aneurysms to occlude thereafter could affect the results because complete aneurysmal occlusion is expected to occur up to 2 years post-PED deployment.⁴⁸

Finally, because some patients had multiple aneurysms, we performed multiple logistic regression using generalized estimating equations to consider inpatient correlations.

CONCLUSIONS

In this study, on the basis of high follow-up data, we analyzed the angiographic and clinical outcomes of unruptured ICA aneurysms after PED treatment. Clinically, ICA aneurysms were safe without rupture in the follow-up period, even with aneurysm remnants. Angiographically, in addition to age, fusiform aneurysms, and aneurysms with the branching artery from the dome, the outer convexity-type of saccular aneurysm was a predictor of incomplete occlusion.

ACKNOWLEDGMENTS

We are grateful to Yuuji Naramoto, MD, Rikuo Nishii, MD, and Yasuhiro Yamamoto, MD, at the Department of Neurosurgery, Kobe City Medical Center General Hospital, Kobe, for collecting some of the data. We thank Dr Peter Karagiannis and Sofia Science Writing for critical reading and proofreading of the manuscript. We are grateful to Chisato Miyakoshi, MD, MSc, at the Department of Pediatrics, Kobe City Medical Center General Hospital, Kobe, for the consultation on statistics analysis.

Disclosures: Nobuyuki Sakai—UNRELATED: Grants/Grants Pending: Medtronic, NeuroVasc, Terumo; Payment for Lectures Including Service on Speakers Bureau: ASAHI INTEC, Biomedical Solutions, Johnson & Johnson, Medtronic, Stryker, Terumo.

REFERENCES

- Fiorella D, Woo HH, Albuquerque FC, et al. **Definitive reconstruction of circumferential, fusiform intracranial aneurysms with the Pipeline Embolization Device.** *Neurosurgery* 2008;62:1115–20; discussion 1120–21 [CrossRef Medline](#)
- Becske T, Kallmes DF, Saatci I, et al. **Pipeline for uncoilable or failed aneurysms: results from a multicenter clinical trial.** *Radiology* 2013;267:858–68 [CrossRef Medline](#)
- Becske T, Brinjikji W, Potts MB, et al. **Long-term clinical and angiographic outcomes following Pipeline Embolization Device treatment of complex internal carotid artery aneurysms: five-year results of the Pipeline for Uncoilable or Failed Aneurysms trial.** *Neurosurgery* 2017;80:40–48 [CrossRef Medline](#)
- Kallmes DF, Hanel R, Lopes D, et al. **International retrospective study of the Pipeline Embolization Device: a multicenter aneurysm treatment study.** *AJNR Am J Neuroradiol* 2015;36:108–15 [CrossRef Medline](#)
- Becske T, Potts MB, Shapiro M, et al. **Pipeline for Uncoilable or Failed Aneurysms: 3-year follow-up results.** *J Neurosurg* 2017;127:81–88 [CrossRef Medline](#)
- Nelson PK, Lylyk P, Szikora I, et al. **The Pipeline Embolization Device for the intracranial treatment of aneurysms trial.** *AJNR Am J Neuroradiol* 2011;32:34–40 [CrossRef](#)
- Lylyk P, Miranda C, Ceratto R, et al. **Curative endovascular reconstruction of cerebral aneurysms with the Pipeline Embolization Device: the Buenos Aires experience.** *Neurosurgery* 2009;64:632–42 [CrossRef Medline](#)
- Kallmes DF, Brinjikji W, Cekirge S, et al. **Safety and efficacy of the Pipeline Embolization Device for treatment of intracranial aneurysms: a pooled analysis of 3 large studies.** *J Neurosurg* 2017;127:775–80 [CrossRef Medline](#)
- Munich SA, Cress MC, Rangel-Castilla L, et al. **Neck remnants and the risk of aneurysm rupture after endovascular treatment with coiling or stent-assisted coiling: much ado about nothing?** *Clin Neurosurg* 2019;84:421–47 [CrossRef Medline](#)
- Adeeb N, Moore JM, Wirtz M, et al. **Predictors of incomplete occlusion following Pipeline embolization of intracranial aneurysms: is it less effective in older patients?** *AJNR Am J Neuroradiol* 2017;38:2295–300 [CrossRef Medline](#)
- Shapiro M, Becske T, Nelson PK. **Learning from failure: persistence of aneurysms following Pipeline embolization.** *J Neurosurg* 2017;126:578–85 [CrossRef Medline](#)
- Madaelil TP, Grossberg JA, Howard BM, et al. **Aneurysm remnants after flow diversion: clinical and angiographic outcomes.** *AJNR Am J Neuroradiol* 2019;40:694–98 [CrossRef Medline](#)
- Liang B, Lesley WS, Robinson TM, et al. **Off-label application of Pipeline Embolization Device for intracranial aneurysms.** *Neurointervention* 2019;14:116–24 [CrossRef Medline](#)
- Zhang Y, Liang F, Zhang Y, et al. **Exploring the feasibility of Pipeline Embolization Device compared with stent-assisted coiling to treat non-saccular, unruptured, intradural vertebral artery aneurysms.** *Front Neurol* 2019;10:275 [CrossRef Medline](#)
- O'Kelly CJ, Spears J, Chow M, et al. **Canadian experience with the Pipeline Embolization Device for repair of unruptured intracranial aneurysms.** *AJNR Am J Neuroradiol* 2013;34:381–87 [CrossRef Medline](#)
- Jabbour P, Chalouhi N, Tjoumakaris S, et al. **The Pipeline Embolization Device: learning curve and predictors of complications and aneurysm obliteration.** *Neurosurgery* 2013;73:113–20 [CrossRef Medline](#)
- Li Y, Kim J, Ahmed A. **Effect of aneurysm morphologic parameters on occlusion rates following Pipeline embolization.** *Clin Neurol Neurosurg* 2019;183:105395 [CrossRef Medline](#)
- Wang K, Yuan S. **Actual metal coverage at the neck is critical for flow-diverting stents in treating intracranial aneurysms.** *AJNR Am J Neuroradiol* 2013;34:31–32 [CrossRef Medline](#)
- Wang K, Huang Q, Hong B, et al. **Correlation of aneurysm occlusion with actual metal coverage at neck after implantation of flow-diverting stent in rabbit models.** *Neuroradiology* 2012;54:607–13 [CrossRef Medline](#)
- Jou LD, Chintalapani G, Mawad ME. **Metal coverage ratio of Pipeline Embolization Device for treatment of unruptured aneurysms: reality check.** *Interv Neuroradiol* 2016;22:42–48 [CrossRef Medline](#)
- Brasiliense LBC, Aguilar-Salinas P, Miller DA, et al. **Analysis of predictors and probability of aneurysm occlusion in the internal carotid artery after treatment with Pipeline Embolization Device.** *World Neurosurg* 2017;107:641–48 [CrossRef Medline](#)
- Puffer RC, Lanzino G, Kallmes D, et al. **Patency of the ophthalmic artery after flow diversion treatment of paraclinoid aneurysms.** *J Neurosurg* 2012;116:892–96 [CrossRef Medline](#)
- Raz E, Shapiro M, Becske T, et al. **Anterior choroidal artery patency and clinical follow-up after coverage with the Pipeline Embolization Device.** *AJNR Am J Neuroradiol* 2015;36:937–42 [CrossRef Medline](#)
- Vedantam A, Rao VY, Shaltoni HM, et al. **Incidence and clinical implications of carotid branch occlusion following treatment of internal carotid artery aneurysms with the Pipeline Embolization Device.** *Neurosurgery* 2015;76:173–78 [CrossRef Medline](#)
- Moshayedi H, Omofoye OA, Yap E, et al. **Factors affecting the obliteration rate of intracranial aneurysms treated with a single Pipeline Embolization Device.** *World Neurosurg* 2017;104:2–5 [CrossRef Medline](#)

26. Volker M, Anastasios M, Jan B, et al. **Treatment of intracranial aneurysms with the Pipeline Embolization Device only: a single center experience.** *Neurointervention* 2018;13:32–40 [CrossRef Medline](#)
27. Chua MM, Silveira L, Moore J, et al. **Flow diversion for treatment of intracranial aneurysms: mechanism and implications.** *Ann Neurol* 2019;85:793–800 [CrossRef Medline](#)
28. Schneiders JJ, VanBavel E, Majoie CB, et al. **A flow-diverting stent is not a pressure-diverting stent.** *AJNR Am J Neuroradiol* 2013;34:1–4 [CrossRef Medline](#)
29. Kadirvel R, Ding YH, Dai D, et al. **Cellular mechanisms of aneurysm occlusion after treatment with a flow diverter.** *Radiology* 2014;270:394–99 [CrossRef Medline](#)
30. Zhang Y, Chong W, Qian Y. **Investigation of intracranial aneurysm hemodynamics following flow diverter stent treatment.** *Med Eng Phys* 2013;35:608–15 [CrossRef Medline](#)
31. Chong W, Zhang Y, Qian Y, et al. **Computational hemodynamics analysis of intracranial aneurysms treated with flow diverters: correlation with clinical outcomes.** *AJNR Am J Neuroradiol* 2014;35:136–42 [CrossRef Medline](#)
32. Berg P, Saalfeld S, Janiga G, et al. **Virtual stenting of intracranial aneurysms: a pilot study for the prediction of treatment success based on hemodynamic simulations.** *Int J Artif Organs* 2018;41:698–705 [CrossRef Medline](#)
33. Paliwal N, Damiano RJ, Davies JM, et al. **Association between hemodynamic modifications and clinical outcome of intracranial aneurysms treated using flow diverters.** *Proc SPIE Int Soc Opt Eng* 2017;10135:101352F [CrossRef Medline](#)
34. Kalpakli A. **Experimental study of turbulent flows through pipe bends.** *KTH Royal Institute of Technology* 2012;6–29
35. van Wyk S, Wittberg LP, Bulusu KV, et al. **Non-Newtonian perspectives on pulsatile blood-analog flows in a 180° curved artery model.** *Physics of Fluids* 2015;27:71901 [CrossRef](#)
36. Xu J, Wu Z, Yu Y, et al. **Combined effects of flow diverting strategies and parent artery curvature on aneurysmal hemodynamics: a CFD study.** *PLoS One* 2015;10:e0138648 [CrossRef Medline](#)
37. Marosfoi M, Langan ET, Strittmatter L, et al. **In situ tissue engineering: endothelial growth patterns as a function of flow diverter design.** *J Neurointerv Surg* 2017;9:994–98 [CrossRef Medline](#)
38. Sadasivan C, Cesar L, Seong J, et al. **An original flow diversion device for the treatment of intracranial aneurysms: evaluation in the rabbit elastase-induced model.** *Stroke* 2009;40:952–58 [CrossRef Medline](#)
39. Panchendrabose K, Muram S, Mitha AP. **Promoting endothelialization of flow-diverting stents: a review.** *J Neurointerv Surg* 2020 June 2. [Epub ahead of print] [CrossRef Medline](#)
40. Raymond J, Darsaut TE, Makoyeva A, et al. **Endovascular treatment with flow diverters may fail to occlude experimental bifurcation aneurysms.** *Neuroradiology* 2013;55:1355–63 [CrossRef Medline](#)
41. Hong B, Wang K, Huang Q, et al. **Effects of metal coverage rate of flow diversion device on neointimal growth at side branch ostium and stented artery: an animal experiment in rabbit abdominal aorta.** *Neuroradiology* 2012;54:849–55 [CrossRef Medline](#)
42. Ma D, Dumont TM, Kosukegawa H, et al. **High-Fidelity Virtual Stenting (HiFiVS) for intracranial aneurysm flow diversion: in vitro and in silico.** *Ann Biomed Eng* 2013;41:2143–56 [CrossRef Medline](#)
43. Bing F, Darsaut TE, Salazkin I, et al. **Stents and flow diverters in the treatment of aneurysms: device deformation in vivo may alter porosity and impact efficacy.** *Neuroradiology* 2013;55:85–92 [CrossRef Medline](#)
44. Aurboonyawat T, Blanc R, Schmidt P, et al. **An in vitro study of Silk stent morphology.** *Neuroradiology* 2011;53:659–67 [CrossRef Medline](#)
45. Ma D, Xiang J, Choi H, et al. **Enhanced aneurysmal flow diversion using a dynamic push-pull technique: an experimental and modeling study.** *AJNR Am J Neuroradiol* 2014;35:1779–85 [CrossRef Medline](#)
46. Lähdevuo J, Rosenzweig A. **Effects of aging on angiogenesis.** *Circ Res* 2012;110:1252–63 [CrossRef Medline](#)
47. Szikora I, Turányi E, Marosfoi M. **Evolution of flow-diverter endothelialization and thrombus organization in giant fusiform aneurysms after flow diversion: a histopathologic study.** *AJNR Am J Neuroradiol* 2015;36:1716–20 [CrossRef Medline](#)
48. Gupta R, Ogilvy CS, Moore JM, et al. **Proposal of a follow-up imaging strategy following Pipeline flow diversion treatment of intracranial aneurysms.** *J Neurosurg* 2018;131:32–39 [CrossRef Medline](#)