



Providing Choice & Value
Generic CT and MRI Contrast Agents

**FRESENIUS
KABI**

CONTACT REP

AJNR

MR imaging of histiocytosis X in the central nervous system.

M Graif and J M Pennock

AJNR Am J Neuroradiol 1986, 7 (1) 21-23

<http://www.ajnr.org/content/7/1/21>

This information is current as
of July 5, 2025.

MR Imaging of Histiocytosis X in the Central Nervous System

M. Graif¹
J. M. Pennock¹

The magnetic resonance imaging features of two cases of histiocytosis X in the hypothalamus and one in the cerebral hemispheres are described. The lesions were best seen with spin-echo technique using a long repetition time (TR = 1580 msec) and long echo time (TE = 80 msec). Sagittal images provided the best anatomicotopographic evaluation of the lesions. Comparison with computed tomography with and without contrast enhancement showed an advantage with magnetic resonance imaging.

Disseminated histiocytosis X is a reticuloendothelial disorder of unknown etiology that often involves the central nervous system. Direct radiologic demonstration of histiocytosis X lesions in the central nervous system was made possible by the introduction of computed tomography (CT) [1, 2]. We demonstrate the use of magnetic resonance (MR) imaging in the evaluation of histiocytosis X lesions in the common hypothalamic location as well as the less common hemispheric site. The MR findings were compared with those of CT.

Materials and Methods

Three patients with histologically confirmed evidence of histiocytosis X were examined with MR imaging. MR imaging was performed with a Picker prototype superconducting magnet operating at 0.15 T (6.5 MHz). Inversion-recovery and spin-echo (SE) pulse sequences were used as described previously [3]. The scanning sequences are given in table 1. Image reconstruction was performed by 2D Fourier transformation onto a 256 × 256 matrix.

Case Reports

Case 1

A 12-year-old boy with a 9-year history of Letterer-Siwe disease (osteolytic skull lesions, petechial rash on the trunk, exophthalmos, diabetes insipidus, and hepatosplenomegaly) had developed over the last 2 years endocrine and neurologic signs of intracranial lesions. CT demonstrated a frontoparietal hypodense mass with surrounding edema (fig. 1A). The lesion displayed a moderate to marked degree of contrast enhancement. MR imaging demonstrated an extensive left frontoparietal area of slightly increased T1 (displayed as a dark area) with a loss of gray-/white-matter contrast. Using an SE pulse sequence with a long repetition time (TR = 1580 msec) and long echo time (TE = 80 msec), the lesion appeared as a focal area of brain intensity surrounded by a brighter area (longer T2) of perifocal edema (fig. 1B). Displacement of the midline and distortion of the left lateral ventricle were present as well as dilatation of the lateral and third ventricles and signs of periventricular edema (thin layer of long T2). A postmortem examination performed 2 months later revealed extensive deposits of histiocytosis X in the brain, orbits, and retroperitoneum. The brain deposit appeared as a large mass in the left frontoparietal region.

Received March 6, 1985; accepted after revision May 21, 1985.

¹Department of Diagnostic Radiology, Royal Postgraduate Medical School, Hammersmith Hospital, Du Cane Rd., London W12 0HS, United Kingdom. Address reprint requests to M. Graif.

AJNR 7:21-23, January/February 1986
0195-6108/86/0701-0021

© American Society of Neuroradiology

Case 2

A 25-year-old woman was admitted with episodes of blindness in both eyes and loss of consciousness. She had a 1-year history of diabetes insipidus, galactorrhea, amenorrhea, high prolactin levels, and lung infiltrates. A lung biopsy revealed histiocytosis X. A CT examination of the brain (fig. 2A) suggested a space-occupying lesion in the pituitary fossa. MR imaging was performed 3 months later. The sagittal SE scan (fig. 2B) showed a long-T2 lesion (bright area) in the suprasellar region involving the hypothalamus extensively. The lesion appeared central on the transverse scan (fig. 2C). On the sagittal scan some invasion of the optic chiasm and the ventral portion of the brain stem could be observed. Images were not obtained in the coronal plane.

Case 3

A 35-year-old woman presented with diabetes insipidus, hypothyroidism, impaired growth-hormone response, and multiple subcutaneous lesions. She was diagnosed as having Hand-Schüller-Christian disease on the basis of biopsies taken from the vulva and scalp. Although highly intelligent (in the top 10% of the normal population), she developed a significant deviation in test scores that suggested a decline in the level of intellectual functioning, particularly in the verbal sphere. CT demonstrated a small mass in the hypothalamus immediately above the dorsum sellae, just to the right of the midline (fig. 3A). MR imaging revealed an area of prolonged T2 in the region of the hypothalamus on the sagittal SE scan (fig. 3B). The lesion was more difficult to assess on the inversion-recovery scan because of low contrast with the surrounding tissue. The transverse SE scan at the level of the hypothalamus showed a small area of prolonged T2 just lateral to the third ventricle on the right.

TABLE 1: Pulse Sequences for MR Imaging of Histiocytosis X

Pulse sequence	Time (msec)		
	TR	TI	TE
Inversion-recovery (IR)	1400	400	...
Spin-echo (SE)	544	...	44
	1580	...	80

Note.—TR = repetition time; TI = inversion time; TE = echo time.

Discussion

Histiocytosis X has several modes of presentation ranging from the mildest solitary eosinophilic granuloma of bone to the most severe forms with disseminated granulomata in bones and soft tissues. These severe forms have been described as Hand-Schüller-Christian disease and Letterer-Siwe disease. Hypothalamic involvement in these disseminated forms is a common complication, and the resultant diabetes insipidus (present in one-third to one-half of the cases) was part of the original triad described by Hand in 1893 (together with exophthalmos and bone defects in the skull). Growth-hormone deficiency may coexist as well. Involvement of the central nervous system outside the hypothalamus is infrequent but may occur in the cerebellum, optic chiasm, and spinal cord, causing neurologic signs that vary according to the exact size and location of the lesion [2, 4–7].

Analysis of the MR imaging features of the histiocytosis X lesions revealed prolonged T1 and T2 values. However, the T1 and T2 values were less prolonged in case 1 than in cases 2 and 3. This difference may be attributable to the chronic nature of the disease in case 1. Histology is known to demonstrate eosinophilic infiltration surrounding a collection of histiocytes in the mild form of the disease, whereas in the chronic disseminated form the cells may become swollen with lipid deposits, mainly cholesterol (foam cells), which tend to become necrotic and replaced by fibrotic tissue [5, 6]. The increase in T1 and T2 of the lesions is by no means specific to histiocytosis X, since most focal brain pathologies show prolonged relaxation times (tumors, both benign and malignant; infarction; multiple sclerosis; infections). The lesions therefore must be considered in the context of their specific location and clinical presentation. In one patient (case 2), MR imaging demonstrated very clearly a lesion that was not obvious on CT (although the CT examination was performed 3 months earlier). The sagittal and coronal sections provide additional topographic dimensions, which are valuable for the assessment of suprasellar and parasellar extent of the tumor and consequently for the planning of the appropriate radiation therapy.

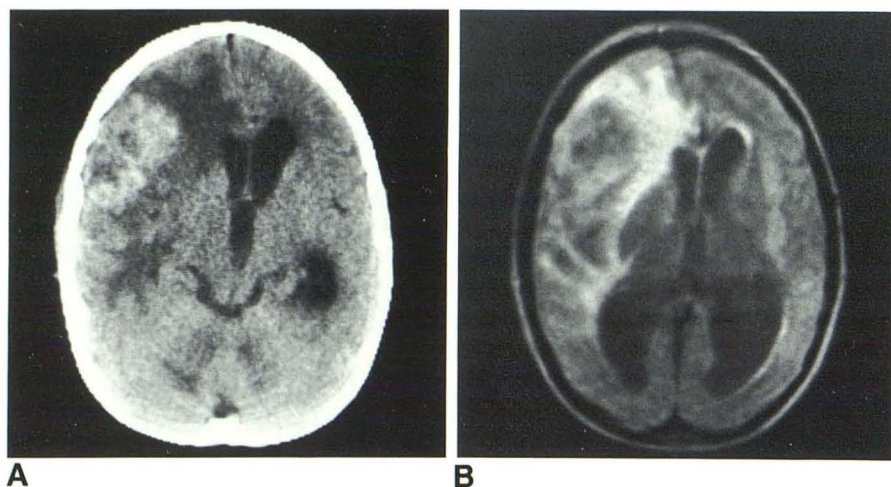


Fig. 1.—Case 1. A, Contrast-enhanced CT scan shows frontoparietal hypodense mass with perifocal edema. B, MR image (SE 1580/80) displays edema as light areas surrounding lesion.

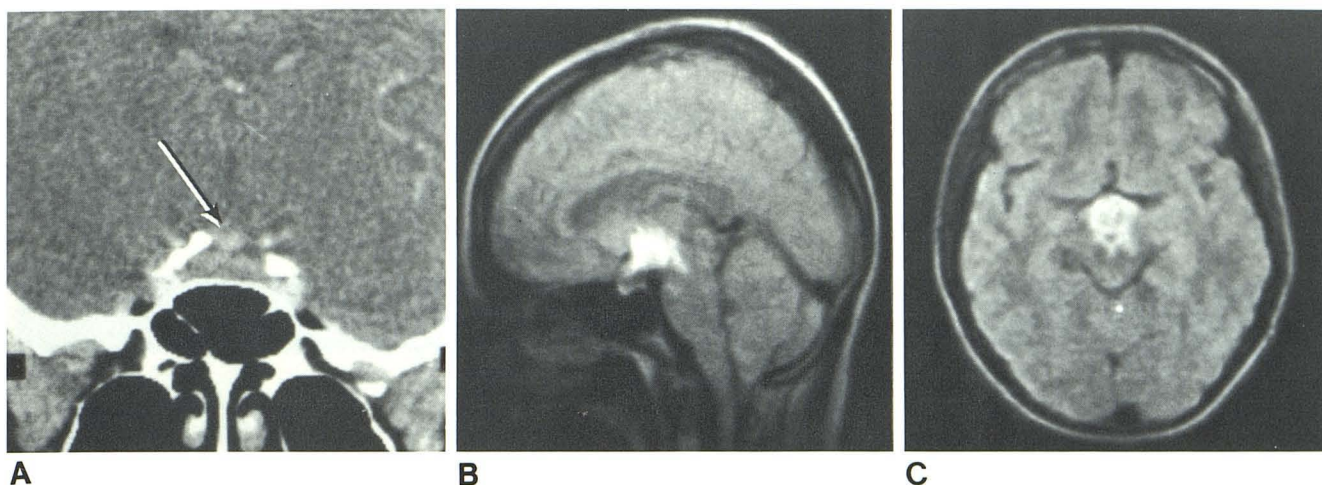
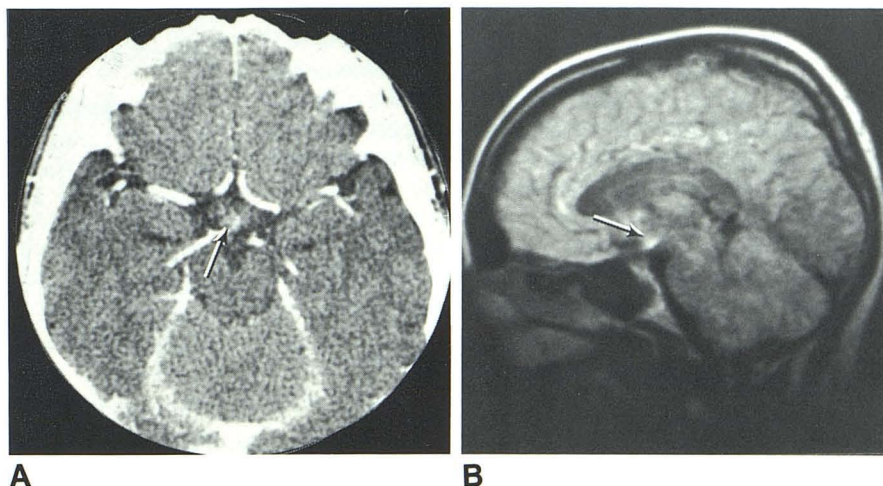


Fig. 2.—Case 2. A, Contrast-enhanced coronal CT scan shows region of abnormal contrast enhancement (arrow) in pituitary fossa. Sagittal (B) and transverse (C) MR images (SE 1580/80) demonstrate large suprasellar lesion involving hypothalamus extensively.

Fig. 3.—Case 3. A, CT scan demonstrates contrast-enhancing mass in suprasellar region (arrow). Same area (B, arrow) is demonstrated on sagittal MR image (SE 1580/80).



Since brain lesions in histiocytosis X are more frequent than clinically expected [7] and since localized low-dose radiation therapy may produce positive therapeutic results, our findings suggest that MR imaging is a valuable method of investigation.

REFERENCES

1. Miller JH, Pena AM, Segall HD. Radiological investigation of sellar region masses in children. *Radiology* **1980**;134:81-87
2. Tibbs PA, Challa V, Martara RH. Isolated histiocytosis X of the hypothalamus. *J Neurosurg* **1978**;49:929-934
3. Young IR, Burl M, Clarke GJ, et al. Magnetic resonance properties of hydrogen: imaging the posterior fossa. *AJNR* **1981**;2:487-493, *AJR* **1981**;137:895-901
4. Lichtenstein L. Histiocytosis X, integration of eosinophilic granuloma of bone, "Letterer-Siwe disease" and "Schüller-Christian disease" as related manifestation of a single nosologic entity. *Arch Pathol* **1953**;56:84-102
5. Cheyne C. Histiocytosis X. *J Bone Joint Surg [Br]* **1971**;53:366-382
6. Avioli LV, Lasersohn JT, Lopresti JM. Histiocytosis X (Schüller-Christian disease): a clinical pathological survey, review of ten patients and the results of prednisone therapy. *Medicine* **1963**;42:119-147
7. Braunstein GD, Whitaker JN, Kohler PO. Cerebellar dysfunction in Hand-Schüller-Christian disease. *Arch Intern Med* **1973**;132:387-390