



## Discover Generics

Cost-Effective CT & MRI Contrast Agents



WATCH VIDEO

# AJNR

## **Thoracic Outlet Syndrome: Review and Reference to Stroke in a Major League Pitcher**

William S. Fields, Noreen A. Lemak and Yoram Ben-Menachem

*AJNR Am J Neuroradiol* 1986, 7 (1) 73-78

<http://www.ajnr.org/content/7/1/73>

This information is current as  
of June 29, 2025.

# Thoracic Outlet Syndrome: Review and Reference to Stroke in a Major League Pitcher

William S. Fields<sup>1</sup>  
Noreen A. Lemak<sup>1</sup>  
Yoram Ben-Menachem<sup>2</sup>

The thoracic outlet compression syndrome is reviewed. It should be considered in all neurologic and vascular complaints of the upper extremity. Symptoms are related to arm position and use and are aggravated by sustained activity that stresses the shoulder. A participant in any sport that requires a repetitive violent throwing motion is a potential candidate for this condition. A detailed report of a major league pitcher illustrates the importance of early diagnosis and appropriate treatment, inasmuch as delay can be catastrophic, as in the case of this career athlete. A thorough history is the best aid in arriving at a diagnosis. When the symptoms are mild or moderate, conservative therapy may suffice. When surgery is indicated, the object is to create adequate space for passage of the brachial plexus, subclavian artery, and subclavian vein. Patients with thrombosis and occlusion of a major artery supplying the upper extremity require an additional arterial reconstructive procedure plus a cervicothoracic sympathectomy.

Vascular compression in the thoracic outlet, with or without the presence of local musculoskeletal anomalies, is a well documented entity [1]. When thoracic outlet syndrome occurs in athletes involved in repeated violent exercise of the arms, the subclavian artery may be subjected to a severe degree of recurrent trauma, resulting in intramural hematoma, dissection, and thrombosis of the artery. Antegrade or, less often, retrograde propagation of a thrombus or extension of an intramural hematoma places the cerebral circulation in great jeopardy by exposing the vertebral artery and, on the right side, the common carotid artery to proximal occlusion and/or distal embolization.

## Case Report

A 30-year-old, right-handed major league pitcher was first seen in 1980. During spring training of that year he complained of progressive fatigue and a sense of heaviness in his pitching arm after a lengthy workout or after he had pitched five or six innings. Once he began the pitching rotation during regular season, it became even more of a problem because he could not go past the third or fourth inning without great difficulty. After that, the greater the amount of effort, the more serious the problem. He was seen on several occasions by the team physician and was subsequently referred to an orthopedic surgeon specializing in bone and joint problems of baseball players.

In June 1980, during the third or fourth inning of a game, his arm suddenly "went dead," and he had numbness and tingling in the first three digits of the right hand. He was unable to continue.

He was admitted to a hospital a few weeks later for diagnostic evaluation, and on July 25, 1980, angiography demonstrated complete occlusion of the right subclavian artery just distal to the origin of the thyrocervical trunk and immediately proximal to the medial edge of the first rib (fig. 1A). The brachial artery was reconstituted via thyrocervical/subscapular collaterals (fig. 1B).

No surgery was performed at that time, and the patient was discharged from the hospital and allowed to resume his workouts. Early in the morning on July 30, 1980, he went to a chiropractor for manipulation of his neck. Later in the afternoon of that same day, while

This article appears in the January/February 1986 issue of *AJNR* and the April 1986 issue of *AJR*.

Received April 10, 1985; accepted May 29, 1985.

<sup>1</sup> Department of Neuro-Oncology, Box 118, University of Texas M. D. Anderson Hospital and Tumor Institute, 6723 Bertner Ave., Houston, TX 77030. Address reprint requests to W. S. Fields.

<sup>2</sup> Department of Radiology, Veterans Administration Medical Center, Houston, TX 77211.

*AJNR* 7:73-78, January/February 1986  
0195-6108/86/0701-0073

© American Society of Neuroradiology



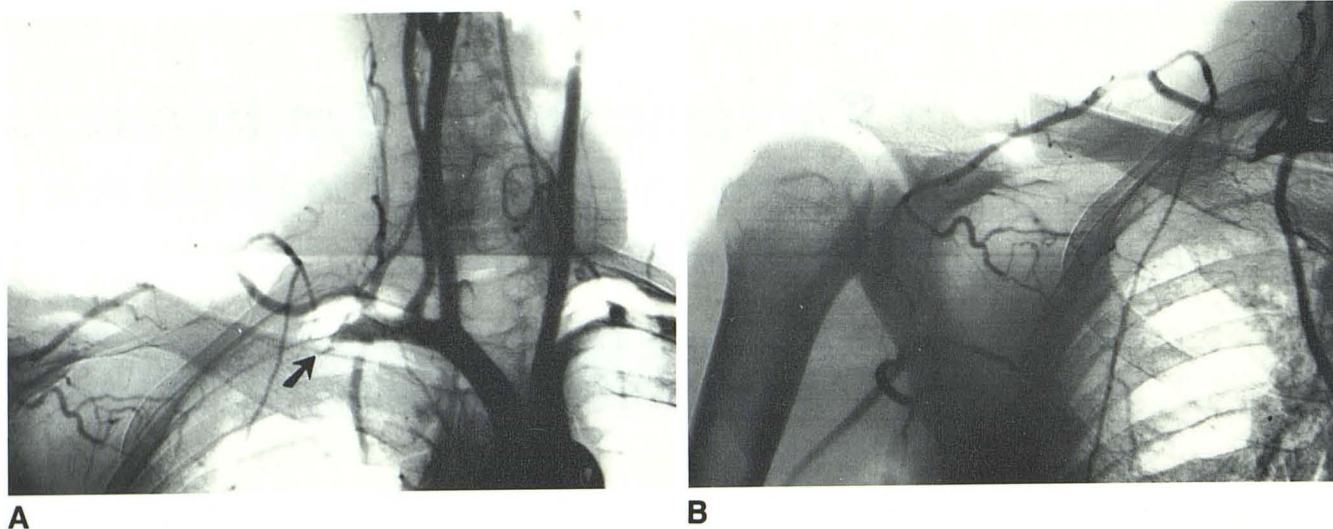


Fig. 1.—Aortogram (A) and subclavian arteriogram (B) document occlusion of right subclavian artery near first rib (arrow). Edge of occluded segment is spiral, indicating fairly recent occlusion, at least in part due to intimal dissection. Occlusion involves also entire length of axillary artery (B), with poor collateralization of brachial artery from suprascapular and descending scapular branches of thyrocervical trunk to circumflex scapular and thoracodorsal branches of subscapular artery. Collateral arteries are not well developed, indicating relatively recent subclavian-axillary occlusion.

zation of brachial artery from suprascapular and descending scapular branches of thyrocervical trunk to circumflex scapular and thoracodorsal branches of subscapular artery. Collateral arteries are not well developed, indicating relatively recent subclavian-axillary occlusion.

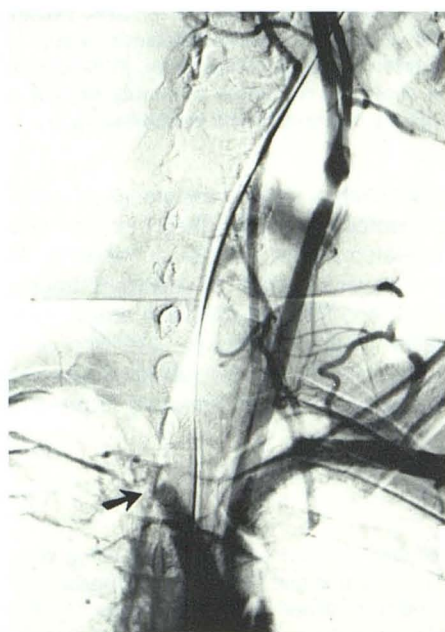

Fig. 2.—Aortogram after stroke. Complete occlusion of innominate artery near its bifurcation (arrow). Nature of occlusion—embolus, dissection or retrograde propagation of thrombus—cannot be established.

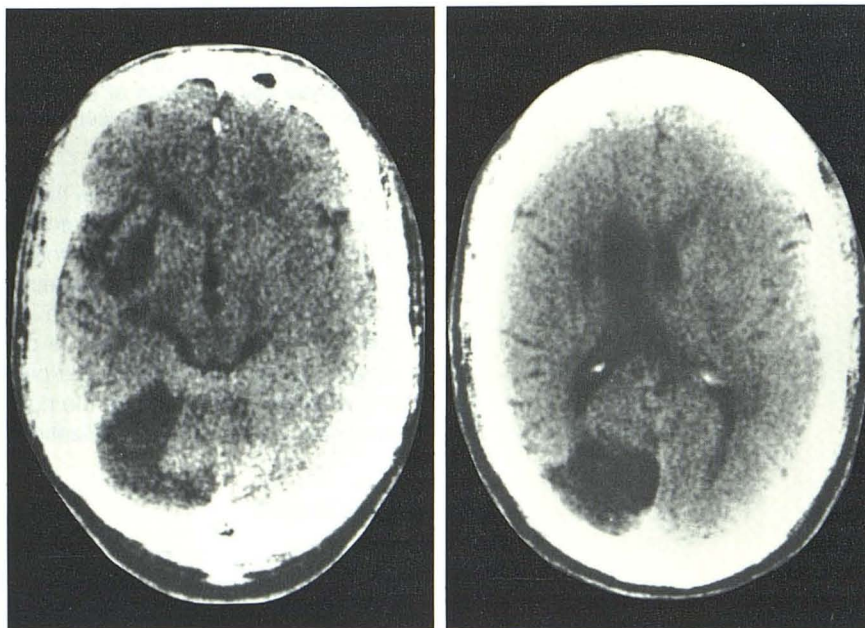


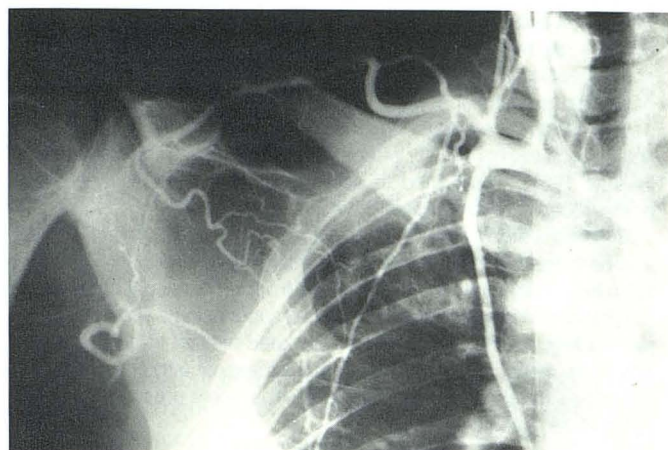
Fig. 3.—CT scans of brain. Infarcts in right basal ganglia, right occipital lobe, and right cerebellar hemisphere.

working out on the field, the patient experienced a sudden onset of confusion, headache, tinnitus, nausea, and generalized weakness, but did not lose consciousness. He was readmitted to the same hospital, where it was noted that he had suffered a stroke, manifested by left motor and sensory paralysis and left homonymous hemianopia. Arteriography revealed occlusion of the innominate artery, presumably by a thrombus (fig. 2). He was taken immediately to surgery,

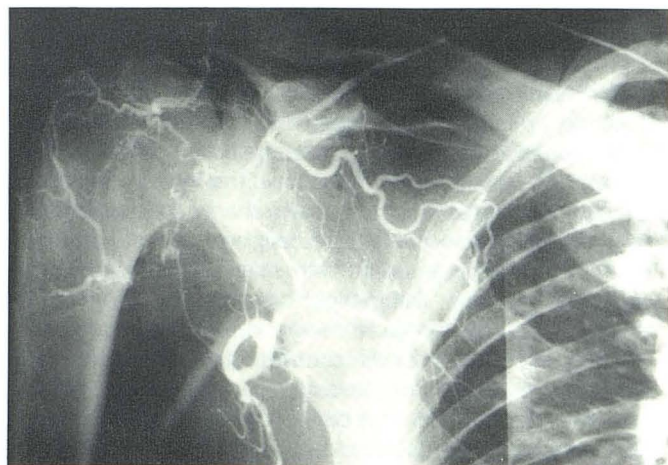
where a large amount of clot was removed from the innominate and right subclavian arteries and a smaller amount from the proximal segment of the right common carotid artery. After slow, but satisfactory, recovery, the patient began a rehabilitation program.

He first came under the care of one of us (W. S. F.) on September 29, 1980, and was admitted to another hospital for further assessment. At that time he was walking with only minimal difficulty, but



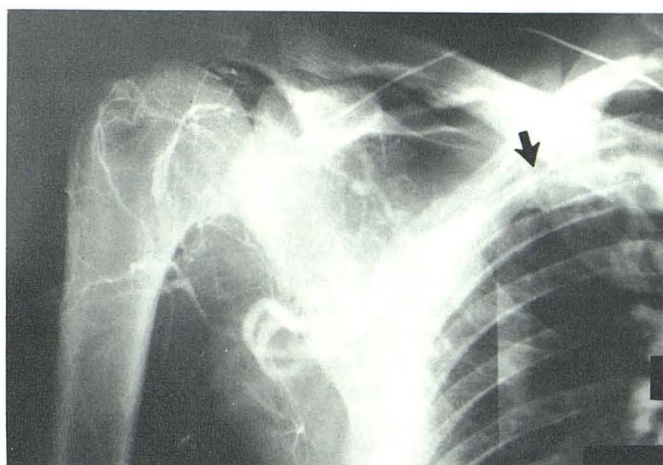

A



B

Fig. 4.—Postoperative selective subclavian angiography. **A**, Distal end of subclavian artery lumen rounded after thrombectomy. Right carotid and vertebral arteries are patent. **B**, Selective suprascapular angiogram. Thyrocervical/subscapular collaterals remain small. Contribution of internal mammary artery to brachial circulation is negligible. **C**, Thoracic outlet compression also involves subclavian vein, which becomes markedly narrowed as it crosses first rib (arrow).



C

had residual muscular weakness of the entire left upper extremity and left facial weakness.

His visual fields were full to confrontation testing when a single stimulus was presented from either side, but there was obvious inattention to the left visual field when simultaneous stimuli were presented from both sides. Neuroophthalmologic assessment revealed an incongruous left upper homonymous quadrantanopia. Some acquired myopia secondary to ciliary spasm was also present.

Examination by computed tomography (CT) on September 30, 1980, revealed large infarcts in the right basal ganglia, the right occipital lobe, and the right cerebellar hemisphere (fig. 3). It was presumed that these were embolic and had originated at the time of acute occlusion of the innominate artery on July 30, 1980. The appearance of the infarcts has remained basically unchanged on follow-up CT studies despite progressive clinical recovery. Arteriography on October 1, 1980, showed rounding-off of the subclavian artery after surgery (fig. 4A). Collateralization of the brachial artery remained slow (fig. 4B), to the extent that one could not study the distal upper extremity even with selective injections into the suprascapular collateral. During the late phase of the suprascapular study, the subclavian vein was seen to narrow considerably as it crossed the first rib (fig. 4C). The intracranial circulation was unremarkable except for a slightly delayed flow in the posterior temporal branch of the right middle cerebral artery.

It was believed that the best hope for complete athletic rehabilita-

tion would be a subclavian-brachial bypass, using an external iliac artery as an autograft. This was the procedure the patient chose after all options, both surgical and nonsurgical, had been discussed with him. He was then transferred to a third hospital (out of state), where surgery was performed on October 14, 1980.

Because of the patient's height (203 cm) and weight (118 kg), both external iliac arteries were harvested and sutured end-to-end to form a new subclavian-axillary conduit. The external iliac arteries were replaced with synthetic grafts. In addition, a right first rib resection, a scalenectomy, and an upper thoracic sympathectomy were performed. The patient tolerated the lengthy procedure very well, and his recovery was uneventful. When he was released from the hospital on October 25, 1980, the blood pressure in the right arm was normal and equal to that in his left arm, and there was no bruit audible over the graft. Slight numbness remained in the right middle finger but appeared to be resolving.

He returned to the care of one of us (W. S. F.) and entered a physical fitness program. By January 1981, the strength of his left upper extremity was almost normal, but both still showed residual increase of tendon reflexes. The left facial weakness was no longer apparent. Although repeat neuroophthalmologic assessment revealed no left visual field defect, a perceptual deficit still seemed to be present. As is often observed in patients with right cerebral hemisphere lesions, both his depth perception and his ability to transfer two-dimensional planes into three-dimensional displays were



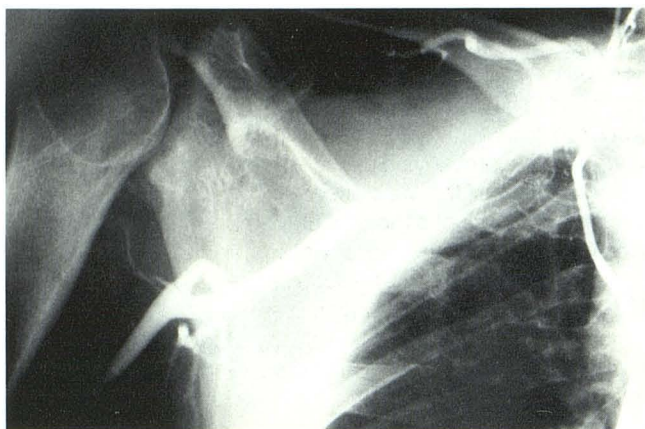


Fig. 5.—Subclavian arteriogram 3 years after stroke. Arterial conduit constructed from external iliac arteries serves as subclavian/axillary bypass autograft.

disturbed. The most frequent error that he made during the testing appeared to be that of rotation of objects in space. Later, during spring training, this deficit made it difficult at first for him to catch balls that were returned to his left side by the catcher, but, subsequently, he overcame this handicap.

At the end of spring training, the patient was placed on the disabled list and not reactivated until midsummer. He did, however, continue an intensive rehabilitation program, working out with the other players when the team was "at home," and was provided an opportunity on several occasions to pitch at batting practice. On September 1, 1981, he was reactivated and accompanied the team both at home and away.

The patient was seen for follow-up on January 13, 1982. No neurologic abnormality was apparent. Pulses and blood pressures were normal and equal in both arms. The right arm was warmer than the left, the result of the sympathectomy at the time of the second operation. Although 7 kg heavier than his usual playing weight, the patient was in excellent physical condition. Nevertheless, he had considerable difficulty in regaining his previous level of performance and was, therefore, sent to a minor league club. He gradually worked his way up to AAA level and was returned to the major league roster on September 1, 1982.

During the fall and winter of 1982–83, he worked extremely hard to maintain his physical condition. His emotional state and his attitude improved considerably, and when he returned for spring training, he had regained much of his old form. Unfortunately, when the team broke training to play some exhibition games before the regular season, he developed intermittent claudication in the left calf. He was examined again on March 3, 1983, and noted to have no dorsalis pedis or popliteal pulses on the left. The left femoral pulse was barely palpable, and there was an audible bruit over the femoral artery in the groin. The history and physical findings suggested occlusion of the prosthetic graft that had been inserted as a substitute for the external iliac artery in the fall of 1980.

Arteriography on March 3, 1983, revealed complete occlusion of the left external iliac graft, narrowing of the right external iliac graft, complete occlusion of the left distal radial artery, and a normal right subclavian/axillary conduit (fig. 5). (The radiologist believed that the occlusion of the left distal radial artery was probably iatrogenic: An arterial line must have been inserted in the distal radial artery at the time of one of the operations. The artery had been completely replaced functionally by the ulnar artery, which offered excellent blood flow to the entire wrist and hand.)

The left external iliac artery graft was bypassed, using a graft made of different material. The patient's recovery was uneventful, and repeat arteriography demonstrated a patent, smooth left iliac graft with normal blood flow.

The patient once again began a reconditioning program and was able to increase his activity without any recurrence of the claudication. In June 1983, he returned to active training, pitching regularly and participating in other physical pursuits.

Before the start of the 1984 season, however, his contract expired, and he was placed on waivers. He was not picked up by any other team and, therefore, decided to retire from professional baseball. At the present time he is working regularly, supervising a sports program for minority youths, and continues to keep himself in good physical condition. He is neurologically normal on examination, but brain CT still shows the same hypodense lesions that were present at the time of his initial evaluation in 1980.

## Discussion

Our mammalian predecessors carried their front legs in a dependent position so that they could stand on all four limbs. When we became bipeds and assumed an upright posture, our arms became parallel to the trunk. This moved the nerves, arteries, and veins (which leave the thorax to pass into the arm) laterally and increased their angle of flexion. The combination of this acute angle with stretching caused by the weight of the upper limbs might be expected to produce a thoracic outlet syndrome in everyone, but the support provided by the muscles of the shoulder girdle is normally adequate to compensate for this anatomic arrangement. If, however, this support fails or if the neurovascular bundle or the bony outlet from the thoracic cage is anatomically abnormal, the nerves, artery, or vein may become stretched or compressed [2].

All shoulder girdle compression syndromes have one common feature, namely, compression of the brachial plexus, the subclavian artery, and subclavian vein, usually between the first rib and the clavicle [3]. With elevation of the upper limb, there is a scissorlike approximation of the clavicle superiorly and the first rib inferiorly [4]. Grouping the various conditions under the single heading of thoracic outlet syndrome has resulted in more correct diagnoses and improved therapy. This syndrome should be considered in all neurologic and vascular complaints of the arm previously reported as scalenus anticus, hyperabduction, costoclavicular, cervical rib, fractured clavicle, cervicobrachial compression, pneumatic hammer, effort vein thrombosis, subcoracoid pectoralis minor, and first thoracic rib syndromes [5].

Our case involved retrograde propagation of a right subclavian artery thrombus into the brachiocephalic trunk. Such an occurrence, although rare, was first reported by Gould in 1884 [6] and again in 1887 [7]. Symonds [8] subsequently reported two cases of thrombosis of the subclavian artery accompanied by contralateral hemiplegia of sudden onset, probably caused by embolic infarction. As one might expect, the lesion in all published cases has been on the right side, since only on that side does circulation to both the head and arm originate in a common trunk from the aorta [9]. In all cases thus far reported, a latent period of 3 months to 3 years



has elapsed between the onset of upper limb symptoms and the occurrence of hemiplegia. Although this complication is uncommon, it must be anticipated and prevented because its consequences are potentially devastating. We believe that the chiropractic manipulation on our patient had no bearing on the events that followed. Strokes after such maneuvers involve the territory supplied by the vertebrobasilar arterial circulation. To our knowledge no cases have been reported that involve the carotid middle cerebral circulation [10].

### Diagnosis

A detailed history from the patient is the best aid in arriving at a proper diagnosis of thoracic outlet compression syndrome. Symptoms may originate from nerve compression (paresthesias, numbness, pain, weakness), from arterial compression (coolness, pallor, claudication, pain, numbness, weakness), or from venous compression (edema, skin discoloration, fatigue, prominent venous pattern over arm, shoulder, or chest) [11]. If the sympathetic nervous system is involved, the condition can lead to Raynaud phenomenon. When the subclavian artery is compressed, poststenotic dilatation or an aneurysm can be produced distal to the site of stenosis. These dilatations or aneurysms can become thrombosed or can act as foci for repeated small distal emboli [4]. In some instances, amputation has been necessary because of repeated embolization and gangrene.

The symptoms in thoracic outlet syndrome are related to arm position and use and are aggravated by sustained activity that stresses the shoulder girdle such as combing or blow-drying the hair; reaching; holding a newspaper, telephone, or steering wheel; or hammering. A participant in any sport that requires a repetitive violent throwing motion is a potential candidate for thoracic outlet compression.

Symptoms are more common in those baseball players whose throwing motion is overhand rather than sidearm. They also occur in cricket bowlers whose throwing motion is traditionally overhand and in oarsmen who engage in repetitive rhythmic hyperabduction of both shoulders.

Strukel and Garrick [12] published what they believed to be the first case reports of thoracic outlet compression in athletes. Three of their four cases were in baseball players, aged 16, 17, and 20 years. One of us previously reported brief case histories of three other major league pitchers who suffered from thoracic outlet compression symptoms [1]. This author has learned subsequently of two others undergoing surgery successfully during 1984; these athletes have both resumed pitching (Yao JST, personal communication). We are also aware of another case report of a left-handed major league pitcher in whom a subclavian artery thrombosis had occurred. After surgical intervention had solved his problem, he was able to return to pitching [13]. He was not at risk for a stroke because his occlusion was on the left side.

Objective findings are often minimal or absent and leave one with a clinical diagnosis based largely on subjective symptoms. The Adson, costoclavicular, and hyperabduction tests are not consistently and unequivocally positive in reproducing symptoms and, conversely, may produce radial pulse obliteration in asymptomatic subjects [14]. Telford and Mot-

tershead [15] found that, of 120 healthy medical students, 38% had obliteration of the radial pulse with shoulder depression, 68% with shoulder retraction, and 54% with shoulder abduction. These tests are helpful only when the symptoms produced clearly simulate the patient's complaints and correlate with accompanying changes in the radial pulse.

Radiographs of the chest, cervical spine, and shoulder may suggest the cause of a thoracic outlet compression only when a gross anomaly such as a visible cervical rib is present. Blood-flow studies using the Doppler technique are useful in confirming that arterial flow diminishes or ceases during postural tests. Nerve conduction-velocity studies are valuable in differentiating thoracic outlet syndrome from other neurologic diseases and also as a guide to therapy [16]. Angiography offers the most precise method of locating the site of compression when the artery or vein is involved; it should be performed with the arm in a neutral position and repeated during postural maneuvers that produce alterations in the distal pulse [14, 17].

### Treatment

*Nonoperative.* In early and mild cases, conservative therapy may suffice. Any of several techniques may be effective: avoiding hyperabduction and obesity; improving posture by elevating shoulders; exercising to strengthen shoulder girdle muscles; cervical traction; moist heat; ultrasound; and rest from all activities [4].

*Operative.* The aim of surgery is to create an adequate passage for the neurovascular bundle. Certain patients require resection of bony abnormalities, such as prolonged transverse processes, a cervical rib, or other congenital or acquired abnormalities. In most patients, transaxillary resection of the first rib and scalenotomy is favored today [4].

Once vascular symptoms appear and a cervical rib is present, it should be removed. Schein et al. [18] recommend replacement of the affected segment of the subclavian artery with a homograft to restore normal blood flow and prevent further emboli or thrombosis. (In athletes, a homograft [from an artery bank] may not withstand repetitive stress as well as an autograft [from the patient's body], as was used in our patient.) In cases of brachial embolus, the distal vessel is occluded, and placing a graft does not improve the circulation to the hand and forearm to an extent greater than would be accomplished by a sympathectomy. Rob and Standeven [19] subscribed to the idea that, since an upper thoracic gangliectomy could be done in a few minutes, it should always be done to secure rapid and maximal dilatation of the collateral channels.

Patients with thromboembolism and angiospastic phenomena of a severe degree, or those with thrombosis and occlusion of a major artery in the arm, require some arterial surgical procedure and, in addition, a cervicothoracic sympathectomy. For this type of operation, most surgeons have used the transaxillary approach.

When feasible, the artery should be directly reconstructed or bypassed to restore adequate flow in the arm and prevent further emboli or retrograde thrombosis from the affected segment of the subclavian artery [20]. When this is impossible



or inadvisable, further distal embolization should be prevented by ligating the artery distal to the points of compression. One should recognize that a cervical rib is not an essential requirement for this syndrome, since any situation that results in prolonged or repetitive compression of the subclavian artery can lead to the mural and intimal changes that predispose to thrombosis and distal embolization.

The importance of early diagnosis and treatment of the syndrome must be emphasized. Vigorous investigation is required, particularly in the symptomatic athlete. A progressively shorter time interval from beginning of daily workout to onset of symptoms is an ominous sign of impending disaster, and investigation and treatment become matters of great urgency. With its typical historic/clinical presentation, the syndrome requires only our most basic diagnostic modality: Listen to the patient; he may be telling you the diagnosis.

#### REFERENCES

1. Fields WS. Neurovascular syndromes of the neck and shoulders. *Semin Neurol* **1981**;1:301-309
2. Thoracic outlet compression syndrome. *Br Med J* **1976**;1:1033
3. Clagett OT. Presidential address: research and prosearch. *J Thorac Cardiovasc Surg* **1962**;44:153-166
4. Daskalakis MK. Thoracic outlet compression syndrome: current concepts and surgical experience. *Int Surg* **1983**;68:337-344
5. Roos DB, Owens JC. Thoracic outlet syndrome. *Arch Surg* **1966**;93:71-74
6. Gould AP. A case of spreading obliterative arteritis. *Trans Clin Soc London* **1884**;17:95
7. Gould AP. Further notes of a case of obliterative arteritis. *Trans Clin Soc London* **1887**;20:252
8. Symonds CP. Two cases of thrombosis of subclavian artery with contralateral hemiplegia of sudden onset, probably embolic. *Brain* **1927**;50:259-260
9. Hoobler SW. The syndrome of cervical rib with subclavian arterial thrombosis and hemiplegia due to cerebral embolism. Report of a case. *N Engl J Med* **1942**;226:942-944
10. Fields WS. Nonpenetrating trauma of the cervical arteries. In: RJ Joynt, D Goldblatt, DR Bennett, eds. *Seminars in neurology*, vol 1, no. 4. New York: Thieme-Stratton, **1981**:284-290
11. Kremer RM, Ahlquist RE Jr. Thoracic outlet compression syndrome. *Am J Surg* **1975**;130:612-616
12. Strukel RJ, Garrick JG. Thoracic outlet compression in athletes. A report of four cases. *Am J Sports Med* **1978**;6:35-39
13. Tullos HS, Cooley DA, Wukasch DC. Unusual lesions of the pitching arm. *Clin Orthop* **1972**;88:169-182
14. Eklöf B. Vascular compression syndromes of the upper extremity. *Acta Chir Scand [Suppl]* **1976**;465:74-77
15. Telford ED, Mottershead S. Pressure at the cervico-brachial junctions: an operative and anatomical study. *J Bone Joint Surg [Br]* **1948**;30:249-265
16. Caldwell JW, Crane CR, Krusen EM. Nerve conduction studies: an aid in the diagnosis of the thoracic outlet syndrome. *South J Med* **1971**;64:210
17. Weibel J, Fields WS. Arteriographic studies of thoracic outlet syndrome. *Br J Radiol* **1967**;40:676-683
18. Schein CJ, Haimovici H, Young H. Arterial thrombosis associated with cervical ribs and surgical consideration. *Surgery* **1956**;40:428-443
19. Rob CG, Standeven A. Arterial occlusion complicating thoracic outlet compression syndrome. *Br Med J* **1958**;2:709-719
20. Eastcott HHG. Reconstruction of the subclavian artery for complications of the cervical rib and thoracic outlet syndrome. *Lancet* **1962**;2:1243-1246