



## Discover Generics

Cost-Effective CT & MRI Contrast Agents



[VIEW CATALOG](#)

# AJNR

## Penetrating Vascular Injuries of the Face and Neck: Clinical and Angiographic Correlation

Charles M. North, Jamshid Ahmadi, Hervey D. Segall and Chi-Shing Zee

*AJNR Am J Neuroradiol* 1986, 7 (5) 855-859  
<http://www.ajnr.org/content/7/5/855>

This information is current as of September 3, 2025.

# Penetrating Vascular Injuries of the Face and Neck: Clinical and Angiographic Correlation

Charles M. North<sup>1, 2</sup>  
Jamshid Ahmadi  
Hervey D. Segall  
Chi-Shing Zee

A retrospective review was made of 139 clinically stable patients who had sustained penetrating trauma to the face and neck. The study was done to learn more about the indications for angiography and the impact of angiography upon patient management. Some relationship between the physical examination and the angiographic findings was found. In the presence of any one of four physical signs or symptoms (absent pulse, bruit, hematoma, or alteration of neurologic status) there was a 30% incidence of vascular injury. However, it is unlikely that a clinically significant traumatic vascular lesion will be missed if angiography is not obtained when these clinical signs and symptoms are not present. In the group of 78 patients who presented with only a wound penetrating the platysma and no other findings or symptoms, just two had vascular injuries on angiograms; one of these lesions was minor and the other did not affect the patient's management. There was a substantially higher rate (50%) of vascular injury in patients with trauma cephalad to the angle of the mandible compared with 11% of patients who had neck trauma. Gunshot wounds were associated with vascular damage more frequently than were stab wounds.

Angiography is often performed in penetrating trauma to the head and neck to evaluate the possibility of vascular injury and to aid in planning appropriate management [1]. Nonetheless, the role of angiography in penetrating head and neck trauma has remained controversial. Some authors have advocated surgical exploration of all cases of penetrating wounds to the neck and face [2-4] while others have used angiography routinely in all cases in order to reduce the number of unnecessary surgical procedures [5, 6]. Angiography, however, is not completely without risk [7], and a more selective policy would be desirable. We retrospectively reviewed a consecutive series of 139 angiograms performed during an 18-month period and correlated the results of those studies with the clinical findings and outcome. The purpose of our study was to establish guidelines for performing angiography and to determine the impact of angiography upon patient management.

This article appears in the September/October 1986 issue of *AJNR* and the November 1986 issue of *AJR*.

Received September 26, 1985; accepted after revision March 12, 1986.

<sup>1</sup> All authors: Department of Radiology, Section of Neuroradiology, University of Southern California School of Medicine, Los Angeles, CA 90033. Address reprint requests to J. Ahmadi, 1200 N. State St., Box 2, Los Angeles, CA 90033.

<sup>2</sup> Present address: Department of Radiology, Mercy Hospital, Bakersfield, CA 93301.

*AJNR* 7:855-859, September/October 1986  
0195-6108/86/0705-0855

© American Society of Neuroradiology

## Subjects and Methods

We retrospectively reviewed the cases of 139 consecutive patients with neck and face trauma who underwent angiography of the brachiocephalic vessels from January 1, 1983, through June 30, 1984. The patients' ages ranged from 12 to 72 years with a mean age of 26 years. There were 135 male patients and 4 female patients. All the patients had been stabilized in the trauma admitting area prior to being referred for angiography. Therefore, our patient population excluded those so critically ill they required immediate exploration and those who succumbed to their trauma in the admitting area.

Angiograms were performed with percutaneous transfemoral technique. The filming sequence routinely included two exposures per second for 4 sec, followed by one exposure per second for 8 sec to facilitate visualization of the jugular veins. There were nine aortic arch studies and 130 selective angiograms. The latter included 84 left carotid, 55 right carotid, 26



left vertebral, 10 right vertebral, and 11 subclavian artery angiograms. Selective angiography was performed on the basis of location and path of the penetrating wound.

All angiograms were reviewed by staff neuroradiologists who had no knowledge of the details of the patients' clinical status. Two patients had minor complications of angiography; one had a transient diminution of the dorsalis pedis pulse, which resolved within 2 hr, and the other had a large hematoma at the puncture site. Observations made and data collected in 139 patients were tabulated according to the weapon used, the side and anatomic location involved, the symptomatology and physical findings resulting from the injury, the angiographic findings, and the management of the patient.

## Results

Of the 139 patients, 62 sustained gunshot wounds and 77 sustained stab wounds. Fifty-five of the 77 patients sustaining stab wounds were injured on their left side, whereas gunshot wounds were evenly distributed between the left and right sides. Seventeen patients with gunshot wounds and six patients with stab wounds had positive angiographic findings. Trauma to the neck occurred in 119 patients, while 20 patients sustained facial trauma. Penetrating trauma above the angle of the jaw and to the face was associated with a higher frequency of abnormal angiographic findings (10 of 20 patients, or 50%) compared with neck trauma (13 of 119 patients, or 11%).

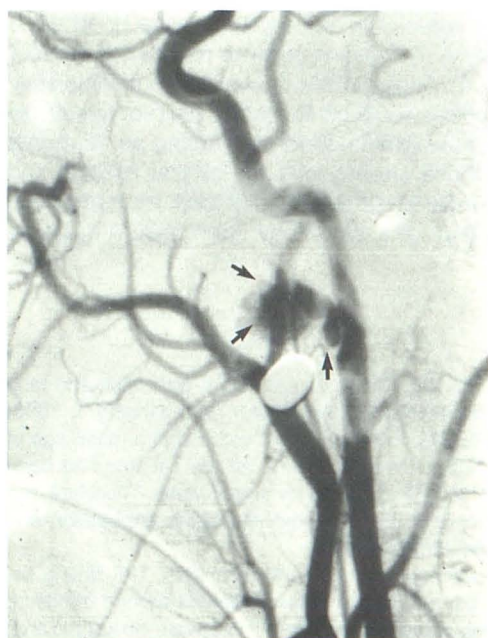One hundred sixteen of the 139 patients had normal angiograms. Of the remaining 23 patients with abnormal angiograms, 12 sustained vascular injuries affecting or potentially affecting cerebral hemodynamics. This included entities such as arterial lacerations, narrowing and occlusions, arteriovenous fistulae, and a pseudoaneurysm (Fig. 1). Two patients had internal jugular vein lacerations. In these two patients compression of the internal jugular vein by hematoma was

seen but the lacerations themselves were not apparent on the angiograms (Fig. 2). Seven patients had lesions affecting the external carotid circulation (four patients had branch occlusions of the external carotid that were clinically insignificant), one patient had a subclavian arteriovenous fistula associated with a large pseudoaneurysm (Fig. 3), and one patient had an injury to the thyrocervical trunk with fistulization into the jugular vein (Fig. 4).

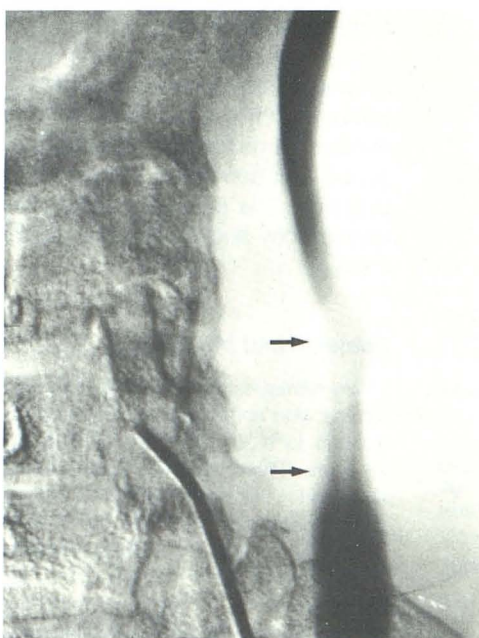
Clinical data on the 139 patients is correlated with angiographic findings in the following paragraphs. One group of patients had no signs or symptoms other than the wound itself. The remaining patients had various combinations of loss of consciousness or neurologic deficits, decreased or absent carotid pulses, bruits, or clinically detectable hematomas at the site of injury. It is important to note that some of the patients had more than one sign or symptom, and various clinical presentations overlapped.

Fifty-eight patients had clinically detectable hematomas at the site of injury. Among the 58 patients with hematoma, 44 presented with only the hematoma (Table 1). In the other 14 patients, the hematoma was associated with various combinations of other clinical findings, such as loss of consciousness, neurologic deficits, decreased or absent carotid pulses, or bruits (Table 2). In the total group of 58 patients with hematomas, 50 had a stable hematoma and eight had expanding hematomas. Of the 50 patients with stable hematomas, 16 had abnormal angiograms; of the eight patients with expanding hematomas, four had abnormal angiograms (Table 3).

Eighty-one patients had no hematoma at the site of injury (Table 4). Two of these patients presented with neurologic deficit (both had cranial nerve palsies and normal angiograms) and one patient presented with a bruit (this patient had a thyrocervical trunk—internal jugular vein fistula). The remain-



1



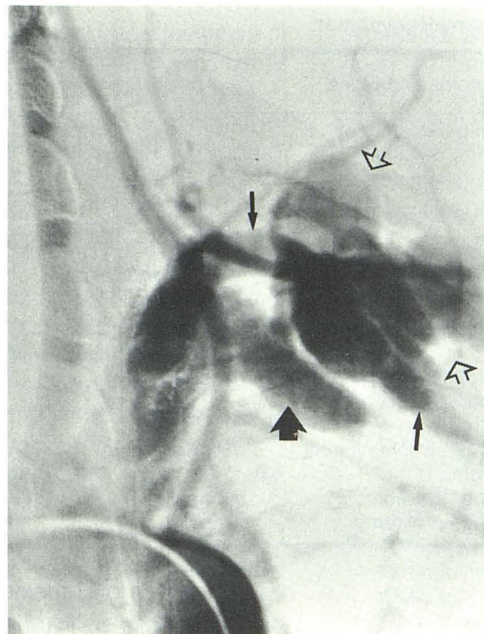
2

Fig. 1.—26-year-old man with expanding hematoma due to gunshot wound to right side of neck. Lateral projection of a common carotid angiogram shows pseudoaneurysm (arrows) of right internal carotid artery projecting anteriorly from its uppermost cervical portion. A Selverstone clamp was placed over the internal carotid artery followed by ligation 2 days later.

Fig. 2.—31-year-old man with large hematoma due to gunshot wound to neck. Anteroposterior projection of venous phase of angiogram shows compression of internal jugular vein by hematoma (arrows). Laceration of the vein was found and repaired at surgery.

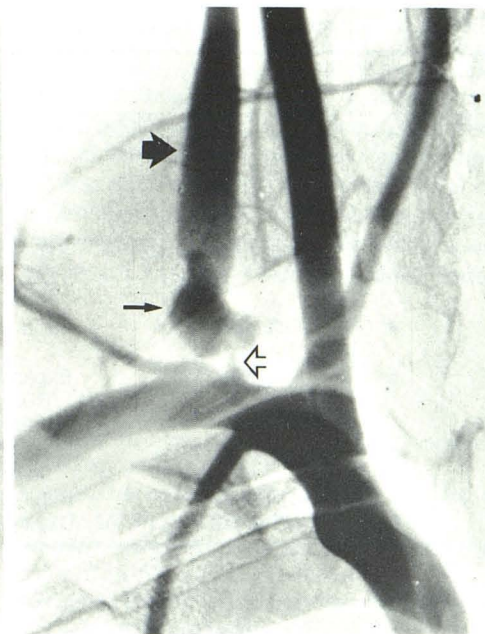


Fig. 3.—22-year-old man with hematoma and bruit over lower portion of left side of neck due to gunshot wound. An arch aortogram obtained with a slightly oblique projection shows large pseudoaneurysm (*open arrows*) of left subclavian artery (*narrow arrows*) and fistulization into left subclavian vein (*wide arrow*). The pseudoaneurysm was resected and the subclavian artery and vein were repaired.



3

Fig. 4.—17-year-old man with a bruit at base of neck, but without a hematoma, caused by stab wound to right side of neck. An arch aortogram shows a pseudoaneurysm (*narrow arrow*) of thyrocervical artery (*open arrow*) and fistulization and reversal of direction of flow in the internal jugular vein (*wide arrow*). Thyrocervical artery was ligated and jugular vein repaired.



4

TABLE 1: 44 Patients with Only a Hematoma

33 normal angiograms
28 observed
5 explored
2 retropharyngeal hematomas
1 perforated esophagus
2 negative explorations
11 patients with abnormal angiograms
3 observed
2 carotid or vertebral occlusions
1 carotid compression or spasm
6 explored
2 carotid compressions or spasm
1 pseudoaneurysm internal carotid artery (Fig. 1)
2 jugular vein lacerations (Fig. 2)
1 facial artery occlusion and submandibular gland laceration
2 embolized
2 pseudoaneurysms internal maxillary artery with arteriovenous fistulas

ing 78 patients had no signs or symptoms other than the wound itself. Of these 78, only two had abnormalities on angiograms while the remaining 76 had normal studies. Neither of the two patients with positive angiograms had clinical signs or symptoms of major significance; one, however, did have occlusion of a vertebral artery and the other patient had only an occlusion of an occipital artery.

Eleven patients had either loss of consciousness or neurologic deficits; nine of these patients had a hematoma (Table 2) and two did not (Table 4). In two patients with loss of consciousness, one had occlusion of the internal carotid and the other had a carotid cavernous fistula. In three patients, angiograms revealed injuries of external carotid artery branches. One of these had a peripheral facial nerve palsy, a

TABLE 2: 14 Patients with Hematomas Associated with Other Symptoms and Signs

8 hematomas and loss of consciousness or neurologic deficits
4 normal angiograms
3 observed
1 observed (this patient had a facial hematoma; an associated ruptured globe was removed)
4 abnormal angiograms
1 observed
1 occlusion occipital artery
2 explored
1 extravasation internal maxillary artery
1 occlusion facial artery (open reduction, associated mandibular fracture)
1 embolized
1 carotid-cavernous fistula
1 hematoma with loss of consciousness and absent carotid pulse
1 abnormal angiogram
1 observed
1 occlusion carotid artery
2 hematomas with decreased or absent carotid pulse
2 abnormal angiograms
2 observed
1 occlusion carotid artery
1 intimal tear and laceration carotid artery
3 hematomas with bruit
1 normal angiogram
1 observed
2 abnormal angiograms
1 explored
1 pseudoaneurysm with subclavian arteriovenous fistula (Fig. 3)
1 embolized
1 carotid cavernous fistula

mandibular fracture, and an occlusion of the facial artery; another patient had a peripheral facial nerve palsy associated with extravasation from the internal maxillary artery; and a third patient had an occipital artery occlusion (this patient had



TABLE 3: Summary of Eight Patients with Expanding Hematomas

Patient No.	Type of Wound/ Site of Trauma	Symptoms and Signs	Angiographic Results	Management
1	Gunshot/face	Expanding hematoma and bruit	Carotid-cavernous fistula	Embolized
2	Gunshot/face	Expanding hematoma	Pseudoaneurysm and arteriovenous fistula internal maxillary	Embolized
3	Gunshot/neck	Expanding hematoma	Pseudoaneurysm internal carotid artery	Silverstone clamp over internal carotid artery; ligated 2 days later
4	Gunshot/neck	Expanding hematoma	External compression or spasm carotid artery	Explored and hematoma evac.
5	Gunshot/neck	Expanding hematoma and RUE paraparesis and paresthesia	Normal	Observed
6	Stab/neck	Expanding retropharyngeal hematoma	Normal	Explored and hematoma evac.
7	Stab/neck	Expanding hematoma	Normal	Observed
8	Stab/neck	Expanding hematoma	Normal	Observed

TABLE 4: 81 Patients Without Hematomas

3 patients with neurologic deficit or bruit
2 with normal angiograms were observed
1 with abnormal angiogram was explored
1 thyrocervical—internal jugular vein fistula (Fig. 4)
78 patients with only wound itself
76 had normal angiograms
72 were observed
4 were explored
2 upper airway lacerations
2 negative explorations
2 had abnormal angiograms
2 were observed
1 left vertebral occlusion
1 external carotid branch occlusion

loss of consciousness after cardiopulmonary arrest). In the remaining six patients, the angiograms were normal and the loss of consciousness or neurologic deficits were attributed to direct injuries to the nervous system.

Three patients had decreased or absent carotid pulses detected by physical examination. One of them had an intimal tear and laceration of the internal carotid artery while the other two had a total occlusion of the internal carotid artery.

Four patients had bruits on physical examination. One of these had a carotid-cavernous fistula, another had an arteriovenous fistula between the thyrocervical trunk and the internal jugular vein, and a third patient had a pseudoaneurysm of the subclavian artery with fistulization into the subclavian vein. The fourth patient with a bruit had a normal angiogram.

The 139 cases were managed as follows: (1) Twenty-three patients had abnormal angiograms. Of these, nine were observed, 10 underwent exploration (two of these 10 patients had internal jugular vein lacerations found at surgery with angiographic abnormalities noted only retrospectively), and four had intraarterial embolization. (2) Ten additional patients also had surgery despite normal angiography because they sustained injuries or were suspected of having other injuries

to the face and upper respiratory or digestive tracts. Four of these had a negative exploration with no such injuries. (3) The other 106 patients had normal angiograms and conservative management.

Overall, 115 patients (83%) were just observed. Of the remaining 24 patients, only nine (6.5%) were explored or embolized as a result of what was found at angiography. The other 15 patients were operated on for nonvascular injuries.

## Discussion

Since World War II, there has been a great deal of controversy over the management of penetrating injuries to the head and neck [2–6, 8–11]. In recent years, the concept of selective exploration seems to be replacing the earlier dictum of mandatory exploration of penetrating wounds [5, 6, 9–11]. In contrast to certain earlier opinions [4, 11], our work suggests some relationship between the clinical situation and the results of angiography. For example, in our series, there were 78 patients who presented with a wound penetrating the platysma but with no other clinical abnormalities. These patients had normal angiograms, except for two who had lesions that did not affect their management. Therefore, there appears to be a rational basis for using the clinical assessment as a guide when considering angiographic evaluation. In our series, 14% of patients with penetrating wounds underwent surgical exploration. Compared with earlier reports [2–6, 9–13], this is a significantly lower exploration rate. It should be kept in mind that our study included only stable patients who were referred for angiography; critically ill patients requiring immediate exploration were not part of the patient population described in this report.

It is interesting that stab wounds of the neck were associated with a relatively low incidence of significant vascular abnormalities at angiography; approximately 92% of these patients had a normal angiogram. Even with gunshot wounds to the neck, there was a 73% rate of negative angiographic studies.



In the group of 11 patients with loss of consciousness or neurologic findings, angiography revealed vascular injuries (significant with respect to the cerebral circulation) in only two patients. Direct injury to the nervous system accounted for the symptoms and findings in eight patients in this group, while one other patient had a cardiopulmonary arrest. However, in instances where neurologic abnormalities have a delayed onset after trauma (particularly when cranial CT fails to show intracranial lesions that can explain the patient's new findings), emergency cerebral angiography should be considered to search for a correctable vascular lesion.

Four of five patients with occlusions of the carotid and/or vertebral arteries had no evidence of cerebral ischemia because of collateral blood flow via the circle of Willis. These patients were managed conservatively.

The anatomic location of trauma to the neck has been divided into three zones [3, 4, 13]: zone I is the area below the level of the cricoid cartilage, zone II is between the cricoid and the angle of the mandible, and zone III is above the angle of the mandible. In this series there was a substantially higher rate of significant angiographic abnormalities in patients with trauma cephalad to the angle of the mandible. Fifty percent of angiograms were abnormal with injuries above the angle of the mandible compared with 11% below.

In view of the two cases of internal jugular vein lacerations where abnormalities were not initially detected at the time of angiography, subtraction films might be useful for the venous phase as well as the arterial phase to enable optimum diagnosis, even though most surgeons would not explore for an isolated venous laceration. The literature indicates that more venous than arterial injuries have been noted at exploration [2, 9, 11, 12]. In a series of 625 patients explored because of penetrating neck injuries, there was a 53% incidence of vascular injuries. Involvement of the venous system was noted in 61% of the vascular injuries [9]. It seems certain that many of these venous injuries are not detected on angiograms.

In our study, angiography had an impact on patient management. The exploration rate in this series was significantly lower than in earlier reports; a negative angiogram limited explorations in search of vascular traumatic lesions. Our

experience also suggests that angiography is not necessary when there are no symptoms or signs other than the wound itself. One cannot be absolutely certain in such instances that a dissection or other vascular lesion is not present; however, the risk of missing a significant lesion with resultant serious harm to the patient is probably less than the potential risk of angiography itself. Although additional experience may further modify the use of angiography in such cases, we have shown that a clinically significant vascular lesion is unlikely under such circumstances.

#### REFERENCES

1. Davis JM, Zimmerman RA. Injury of the carotid and vertebral arteries. *Neuroradiology* **1983**;25:55-69
2. Markey JC, Hines JL, Nance FC. Penetrating neck wounds: a review of 218 cases. *Am Surg* **1975**;41:77-83
3. Saletta JD, Lowe RJ, Lim LT, Thornton J, Delk S, Moss GS. Penetrating trauma of the neck. *J Trauma* **1976**;16:579-587
4. Roon JA, Christensen N. Evaluation and treatment of penetrating cervical injuries. *J Trauma* **1979**;19:391-397
5. McCormick JM, Burch BH. Routine angiographic evaluation of neck and extremity injuries. *J Trauma* **1979**;19:384-387
6. Hiatt JR, Busuttill RW, Wilson SE. Impact of routine arteriography on management of penetrating neck injuries. *Vasc Surg* **1984**;1:860-866
7. Vitek JJ. Femoro-cerebral angiography: analysis of 2000 consecutive examinations; special emphasis on carotid artery catheterization in older patients. *AJR* **1973**;118:633-647
8. Giannotta SL, Ahmadi J. Vascular lesions with head injury. In: Wilkins RM, Rengachary SS, eds. *Neurosurgery*. New York: McGraw-Hill, **1985**:1678-1688
9. Sheely CH, Mattox KL, Reul GJ, Beall AC, DeBaakey ME. Current concepts in the management of penetrating neck trauma. *J Trauma* **1975**;15:895-900
10. Elerding SC, Manari FD, Moore EE. Reappraisal of penetrating neck injury management. *J Trauma* **1930**;20:695-697
11. Rao PM, Bhatti MF, Gaudino J. Penetrating injuries of the neck: criteria for exploration. *J Trauma* **1983**;23:47-49
12. Massac EJR, Siram SM, Leffall LDJ. Penetrating neck wounds. *Am J Surg* **1983**;145:263-265
13. Monson DW, Saletta JD, Freeark RJ. Carotid-vertebral trauma. *J Trauma* **1969**;9:987-999