



Providing Choice & Value
Generic CT and MRI Contrast Agents

**FRESENIUS
KABI**

CONTACT REP

AJNR

Horner's syndrome secondary to traumatic pseudoaneurysms.

P J Yang, J F Seeger, R F Carmody and T B Burt

AJNR Am J Neuroradiol 1986, 7 (5) 913-915

<http://www.ajnr.org/content/7/5/913.citation>

This information is current as
of July 17, 2025.

Horner's Syndrome Secondary to Traumatic Pseudoaneurysms

Peter J. Yang,¹ Joachim F. Seeger, Raymond F. Carmody, and Todd B. Burt

Since many clinical entities may result in Horner's syndrome, patients with this symptom complex must be evaluated for an underlying cause. We present two cases in which traumatic pseudoaneurysms along the oculosympathetic routes were discovered. Although vascular lesions of the internal carotid artery have been shown to cause Horner's syndrome [1-5], to the best of our knowledge there is no previous report of an internal mammary artery pseudoaneurysm as a cause. We also review the anatomy of oculosympathetic pathways, which are critical to understanding the location of lesions causing this common syndrome.

Case Reports

Case 1

A 23-year-old woman had onset of pain in her right shoulder extending up to the side of her head during a physical workout that involved hyperextension and rotation of the neck. About 1 week later, she noticed drooping of her right eyelid and soreness of her throat on the same side.

On physical examination her palpebral angle was narrower on the right side. The right pupil measured 2-3 mm, and the left 4-5 mm. She had no anhydrosis, palpable neck mass, or bruits. CT examination revealed a retroclavicular mass on the right side (Fig. 1A). An IV digital subtraction angiogram was performed, which showed a pseudoaneurysm of the proximal internal mammary artery, presumably posttraumatic (Fig. 1B). Because the size of the mass on CT was larger than the angiographically demonstrated aneurysm, surrounding hematoma was suspected. By the time surgery was performed, 1 week after the CT scan, no distinct hematoma was found. However, some adjacent lymph nodes contained hemosiderin-laden macrophages consistent with previous hemorrhage. Six months after surgery, the patient has only residual miosis.

Case 2

A 25-year-old man was hit on the left side of his head and neck when exiting a bar. He experienced some soreness in his neck and several days later had transient numbness of his right hand. He had intermittent, transient episodes of right-body numbness and weakness, and after 2 weeks sought medical help.

Physical examination disclosed left-sided ptosis and miosis, but no

anhydrosis. Intraarterial digital subtraction angiography showed a large pseudoaneurysm of the distal cervical portion of the left internal carotid artery (Figs. 2A and 2B). The lesion was believed to be too close to the skull base to be surgically accessible. Because superficial temporal artery-middle cerebral artery bypass was contemplated, a selective left external carotid artery injection was performed, which showed an additional pseudoaneurysm of the superficial temporal artery (Fig. 2C). Proximal internal carotid artery ligation was done because of repeated ischemic symptoms. After surgery, the patient's transient ischemic attacks ceased, but the Horner's syndrome persists.

Discussion

The clinical triad of Horner's syndrome consists of ipsilateral miosis, ptosis, and enophthalmos [6]. A transitory rise in facial temperature coupled with ipsilateral anhydrosis also is common [7]. This is due to disruption of the ocular sympathetic fibers. Causes of Horner's syndrome include neoplasia, trauma, infectious diseases (granulomatous or abscess), syringomyelia, tabes dorsalis, and vascular lesions such as aneurysms or arteritis [1-9]. Transient Horner's syndrome has been described after direct carotid arteriography and internal jugular venous catheterization, as well as brachial plexus and caudal anesthesia [9].

To understand the likely locations of lesions causing a Horner's syndrome, one must know the anatomic relationships of the sympathetic nerve chain [10]. The oculosympathetic preganglionic fibers originate from the hypothalamus and exit at lower cervical and upper thoracic levels, usually C6 to T4 (Fig. 3). First-order preganglionic fibers synapse in the spinal cord near the cervicothoracic junction, while most second-order preganglionic fibers leave the cord with the spinal nerves and synapse at the superior cervical ganglion. En route to the superior ganglion, many of the sympathetic fibers loop just inferior to the subclavian artery and medial to the internal mammary artery in the ansa subclavia (Fig. 3).

The postganglionic fibers originate from the superior cervical ganglion and take several different courses, depending on which area they innervate. The fibers that control facial sweating follow the course of the external carotid artery. The

Received October 18, 1984; accepted after revision February 3, 1985.

¹ All authors: Division of Neuroradiology, Department of Radiology, Arizona Health Sciences Center, Tucson, AZ 85724. Address reprint requests to P. J. Yang.

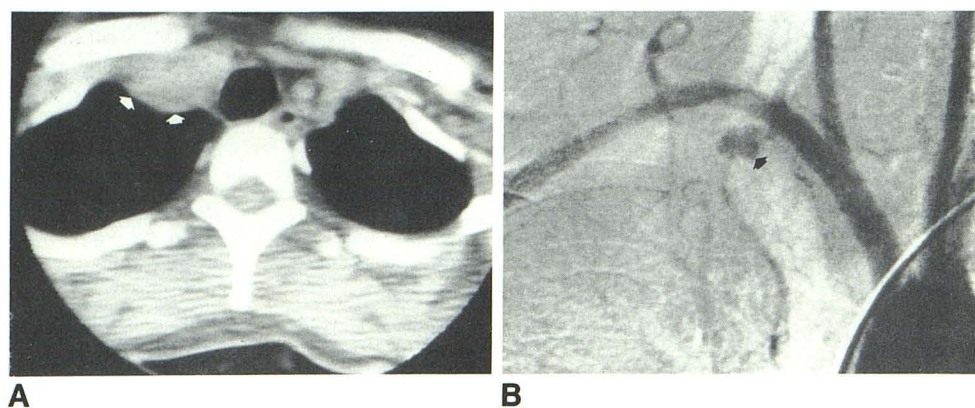


Fig. 1.—**A.** CT shows right retroclavicular mass (arrows) in region of right subclavian artery and brachiocephalic vein. **B.** IV digital subtraction angiogram shows pseudoaneurysm of proximal right internal mammary artery (arrow). Larger size of mass seen on CT is explained by surrounding hematoma.

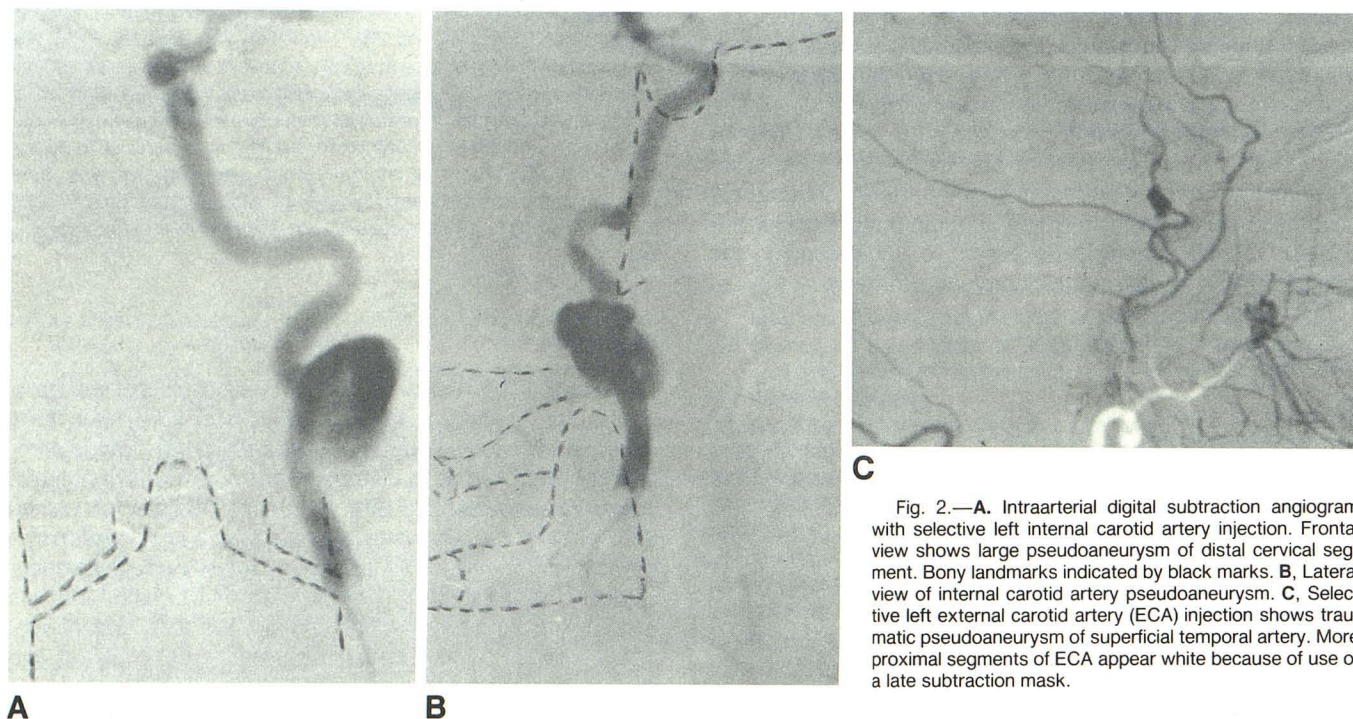


Fig. 2.—**A.** Intraarterial digital subtraction angiogram with selective left internal carotid artery injection. Frontal view shows large pseudoaneurysm of distal cervical segment. Bony landmarks indicated by black marks. **B.** Lateral view of internal carotid artery pseudoaneurysm. **C.** Selective left external carotid artery (ECA) injection shows traumatic pseudoaneurysm of superficial temporal artery. More proximal segments of ECA appear white because of use of a late subtraction mask.

fibers controlling the superior palpebral muscle and dilator pupillae are located adjacent to the internal carotid artery in its cervical and intracranial segments.

Vascular injury resulting in a Horner's syndrome most often involves the internal carotid artery. West et al. [1] described eight patients with nontraumatic dissections of the internal carotid artery resulting in Horner's syndrome accompanied by pain in the head, face, and neck. In all cases, there was angiographic narrowing of the vessel. Mokri et al. [3] described a similar presentation in five patients with spontaneous internal carotid artery dissections.

Healy et al. [4] presented three pseudoaneurysms of the cervical internal carotid artery, similar to our second case, giving rise to Raeder's syndrome. Raeder's syndrome differs from Horner's syndrome in its association with headaches and preservation of ipsilateral facial sweating [4].

Our two cases reemphasize that vascular injury resulting in Horner's syndrome can occur at any point along the route of the oculosympathetic chain. The first case is unique in that, to our knowledge, no previous case of an internal mammary artery pseudoaneurysm giving rise to Horner's syndrome has been described.

Localization of the vascular injury can sometimes be made on clinical examination. An example of an intracavernous carotid aneurysm giving rise to a sixth-nerve palsy and Horner's syndrome was described by Abad et al. [2]. Lesions could not be precisely localized by clinical findings in either of our patients.

The mechanism of sympathetic disruption in both cases was probably direct compression. In our first case, the pseudoaneurysm and adjacent hematoma was in the expected location of the ansa subclavia, accounting for the patient's

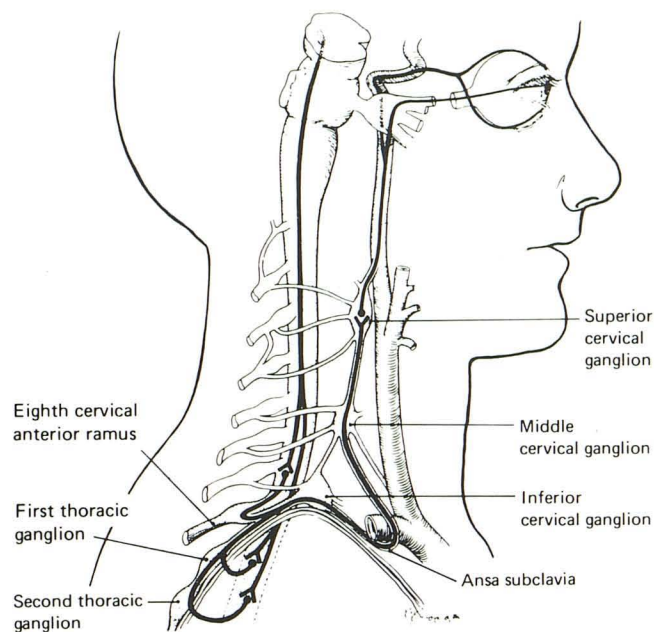


Fig. 3.—Diagram of ocular sympathetic pathways (reprinted with permission from Fleishman et al. [9]).

symptoms. It is well known that other lesions in this area, particularly superior sulcus (Pancoast) tumors can give rise to Horner's syndrome. The internal carotid artery pseudoaneurysm affected the oculosympathetic chain more distally, at the level of the cervical postganglionic fibers.

These two cases reemphasize the need to understand the

anatomic relationships of the oculosympathetic pathways to help in localizing lesions that may cause Horner's syndrome. In patients with a history of trauma, vascular injuries such as pseudoaneurysms may be responsible for the symptoms.

REFERENCES

1. West TET, Davies RJ, Kelly RE. Horner's syndrome and headache due to carotid artery disease. *Br Med J* **1976**;1:818-820
2. Abad JM, Alvarez F, Blazquez MG. An unrecognized neurological syndrome: sixth-nerve palsy and Horner's syndrome due to traumatic intracavernous carotid aneurysm. *Surg Neurol* **1981**;16(2):140-144
3. Mokri B, Sundt TM, Houser OW. Spontaneous internal carotid dissection, hemicrania, and Horner's syndrome. *Arch Neurol* **1979**;36:677-680
4. Healy JF, Zyff J, Rosenkrantz H. Raeder syndrome associated with lesions of the internal carotid artery. *Radiology* **1981**;141:101-104
5. Law WR, Nelson ER. Internal carotid aneurysm as a cause of Raeder's paratrigeminal syndrome. *Neurology* **1968**;18:43-46
6. White PR. Horner's syndrome and its significance in the management of head and neck trauma. *Br J Oral Surg* **1976**;14:165-170
7. Bruce-Chwatt RM, Al-Shihabi B, Dawkins R. Horner's syndrome associated with air-rifle wound of the neck: a case report. *J Laryngol Otol* **1980**;94:1441-1446
8. Varghese S, Hengerer AS, Putnam T, Colgan MT. Neck abscess causing Horner's syndrome. *NY State J Med* **1982**;13:1855-1856
9. Fleishman JA, Bullock JD, Rosset JS, Beck RW. Iatrogenic Horner's syndrome secondary to chest tube thoracostomy. *J Clin Neuro-ophthalmol* **1983**;3:205-210
10. The sympathetic nervous system. In: Warwick R, Williams PL, eds. *Gray's anatomy*. Philadelphia: Saunders, **1973**:1068-1076