



Discover Generics

Cost-Effective CT & MRI Contrast Agents



FRESENIUS
KABI

WATCH VIDEO

AJNR

Opacification of an optic nerve sheath cystic tumor with intrathecally injected metrizamide.

D L Daniels, J P Davis, M C Kay, G A Meyer and V M Haughton

AJNR Am J Neuroradiol 1986, 7 (5) 976-977

<http://www.ajnr.org/content/7/5/976.citation>

This information is current as
of June 30, 2025.

the potential disastrous consequences of attempted biopsy or surgical resection. In fact, it should be emphasized that any erosive mass at the skull base that involves the cavernous sinus region should be studied angiographically. This would allow the identification of not only giant aneurysm but also masses encasing or occluding the carotid artery.

Te Hua Liu
Gary De Filipp
Temple University Hospital
Philadelphia, PA 19140

REFERENCES

1. Heiskanen O, Nikki P. Large intracranial aneurysms. *ACTA Neurol Scand* 1962;38(3):195-208
2. Obrador S, Dierssen G, Rodriguez Hernandez J. Giant aneurysms of the posterior cerebral artery. *J Neurol* 1967;26:413-416
3. Ball J. Massive aneurysms at the base of the skull. *Brain* 1969;92:535-570
4. Polis Z, Bryezinski J, Chodak-Gazewicz M. Giant intracranial aneurysm. Case report. *J Neurosurg* 1973;39:408-411
5. Sarwar M, Batrutzky S, Schechter MM. Tumorous aneurysms. *Neuroradiology* 1976;12:79-97
6. White JC, Ballantine HT. Intracranial aneurysms simulating hypophyseal tumors. *J Neurosurg* 1961;18:34-49
7. Morley TP, Barr HWK. Giant intracranial aneurysms: diagnosis, course and management. *Clin Neurosurg* 1969;16:73-94
8. Pinto RS, Kricheff II, Butler AR, Murali R. Correlation of computed tomographic, angiographic, and neuropathological changes in giant cerebral aneurysms. *Radiology* 1979;132:85-92

Opacification of an Optic Nerve Sheath Cystic Tumor with Intrathecally Injected Metrizamide

A technique for opacifying the optic nerve sheath has been reported but has not been used frequently [1-5]. We report a case in which metrizamide enhancement of the optic nerve sheath helped to characterize an optic sheath cystic mass.

Case Report

A 16-year-old boy was admitted for evaluation of long-standing, painless left proptosis that had recently progressed. Physical examination demonstrated normal extraocular motility and inferior displacement of the left globe. Skull radiographs showed enlargement of his

left optic foramen. MR and IV-enhanced CT studies demonstrated a cystic mass downwardly displacing the left optic nerve. To determine if the mass communicated with the subarachnoid space, a metrizamide-enhanced CT study was performed. The patient was placed prone on a fluoroscopic tilting table. Via lumbar puncture, 5 ml of metrizamide (170 mg/ml) were instilled. The patient was kept in a 20° head-down position for 2 min and then placed prone in a CT/T 9800 scanner. Axial and coronal sections (3- and 1.5-mm thick) through the orbits were obtained. Other technical factors included 120 kV, 200 mA, and 3- and 4-sec scanning times. The metrizamide-enhanced CT study showed opacification of a left optic nerve sheath lobular and cystic mass with an irregular capsule and of a normal right optic nerve sheath (Fig. 1). The patient tolerated the procedure well. Subsequently, he had a left frontal craniotomy, superior orbitotomy, unroofing of his optic foramen, and excisional biopsy. Surgical and pathologic findings demonstrated a benign optic nerve sheath cystic mass with a fibrous capsule. The patient had an unremarkable postoperative course with persistent proptosis.

Discussion

Opacification of the space around the optic nerve via an intrathecal injection of contrast medium implies communication of the space with the cerebral subarachnoid spaces [1]. The optic nerve sheath rarely opacifies with metrizamide [1] or gas [6] after an intrathecal injection of contrast medium.

In this case metrizamide CT proved useful in diagnosing an abnormal optic nerve sheath. In nine prior attempts with other patients (three with orbital tumors, six with intracranial problems) using similar techniques we successfully opacified the optic nerve sheath only once. The reason for failure is not clear but none of these patients had an abnormal optic nerve sheath. Since adequate amounts of contrast media in our patients were demonstrated in the suprasellar cistern, we discount technical problems as a cause of failure to opacify the optic nerve sheath.

Despite its low success rate, opacification of the optic nerve sheath may prove useful in determining the communication of a cystic orbital mass with the subarachnoid space.

David L. Daniels
Jeffrey P. Davis
Marilyn C. Kay
Glenn A. Meyer
Victor M. Haughton
Medical College of Wisconsin
Milwaukee, WI 53226

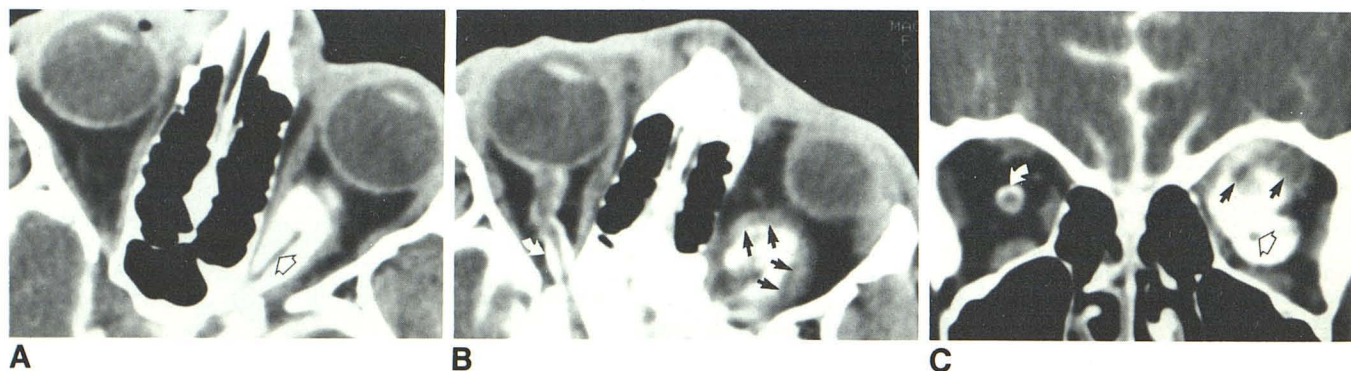


Fig. 1.—Metrizamide-enhanced axial (A,B) and coronal (C) CT images of opacified left optic nerve sheath cystic mass. Note irregular fibrous capsule of mass (black arrows, B and C), left optic nerve (open arrows, A and C), and opacified normal right optic nerve sheath (curved arrows, B and C).

REFERENCES

1. Manelfe C, Pasquine U, Banks WO. Metrizamide demonstration of the subarachnoid space surrounding the optic nerves. *J Comput Assist Tomogr* 1978;2:545-547
2. Haughton VM, Davis JP, Eldevik OP, Gager WE. Optic nerve sheath imaging with metrizamide. *Invest Radiol* 1978;13:544
3. Haughton VM, Davis JP, Harris GJ, Ho KC. Metrizamide optic nerve sheath opacification. *Invest Radiol* 1980;15(4):343-345
4. Davis JP, Haughton VM, Harris GJ, Eldevik OP, Gager WE. Cat optic nerve imaging with metrizamide. *Invest Ophthalmol Vis Sci* 1979;18:273-277
5. Fox AJ, Debrun G, Viñuela F, Assis L, Coates R. Intrathecal metrizamide enhancement of the optic nerve sheath. *J Comput Assist Tomogr* 1979;3:653-656
6. Tenner NS, Trokel SL. Demonstration of intraorbital portion of the optic nerves by pneumoencephalography. *Arch Ophthalmol* 1968;79:572-573

Tapeworm Cysts of the Cauda Equina

Cysticercus, coenurus, and echinococcus may affect the intracranial structures and spread to the spinal subarachnoid space via cerebrospinal fluid pathways [1, 2]. At myelography, tapeworm cysts in the spinal subarachnoid space may be difficult to distinguish from other causes of arachnoiditis and other intradural extramedullary processes, such as metastatic tumor implants. We recently encountered a case in which the mobility of the intradural masses allowed us to make the proper diagnosis.

Case Report

A 69-year-old female Peruvian immigrant was hospitalized for tonic-clonic movements of the upper extremities, lethargy, and transient loss of consciousness. One year before, she had developed sudden hemiparesis that resolved completely. Physical examination revealed nuchal rigidity, flaccid and severely paretic lower extremities, absent knee and ankle jerks, and extensor plantar reflexes bilaterally. The WBC was 12,200 cells/mm³ (71 neutrophils, 19 band forms, nine lymphocytes, one eosinophil). A lumbar puncture yielded opaque fluid at an opening pressure of 500 mm H₂O, containing 21,300 WBC/mm³, 0 mg% glucose, 600 mg% protein. No organisms were present. A lumbar myelogram showed multiple spherical filling defects ranging from several millimeters to approximately 2 cm in size in the dependent portion of the thecal sac while metrizamide was being injected under fluoroscopic control. As the patient was tilted to a 30° Trendelenburg position, several of these filling defects gravitated cephalad (Figs. 1A and 1B), and vice versa as the patient was returned to the erect position. At surgery the dura was thickened and approximately 10 to 12 clear yellow cysts up to 1.5 cm in size lay in the subarachnoid space among the nerve roots of the cauda equina, which were thickened and inflamed. Most cysts were free-floating but some were interconnected by thin branching stalks, forming grapelike clusters. All were easily extracted from the thecal sac by flushing the operative site with saline.

The cysts were identified as cysticerci or possibly coenuri, based on the presence of branching stalks and the absence of daughter vesicles within the cyst cavities. The absence of scoleces (larva "heads" with their distinctive arrays of hooklets and suckers) prevented a more precise diagnosis. A cerebral CT scan showed dilatation of all ventricles with no evidence of parenchymal mass or calcifications. The patient was treated with corticosteroids, diphenylhydantoin and helminthicide praziquantel; she became progressively more alert but did not regain the use of her lower limbs.

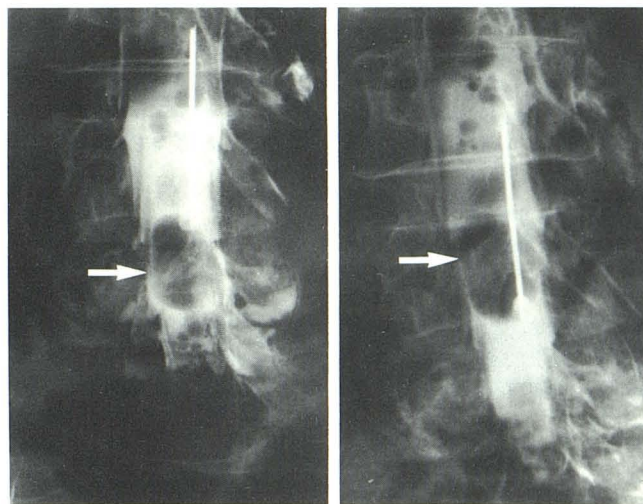


Fig. 1.—Metrizamide myelogram in semierect position (A). Multiple filling defects are seen in thecal sac including a 2-cm lesion at level of top of L5 vertebral body (arrow). In 30° Trendelenburg position, large cyst (arrow) gravitates to level of middle of L4 vertebral body (B).

Discussion

Many cases of tapeworm cysts of the CNS defy specific diagnosis because the cysts do not contain the characteristic scoleces at the time they are discovered [3]. Most reported cases of so-called "sterile" cysts have been attributed to cysticercosis on the basis of associated clinical or laboratory findings, such as soft-tissue calcification or infestation of the bowel by the adult tapeworm *Taenia solium*. Involvement of the spinal cord and its envelopes by tapeworm cysts is a rare condition in the United States.

The myelographic features of spinal subarachnoid cysticercosis are usually nonspecific and consist of single or multiple intradural filling defects caused by the cysts themselves, as well as irregularity of the dural sac contours and blunting of nerve roots sleeves because of associated leptomeningitis. The most commonly affected site is the high cervical region [4], presumably as a result of direct spread from posterior fossa cisterns where cysticercus cysts are often found. Cysts may settle in the caudal portion of the thecal sac and affect the nerve roots of the cauda equina.

Spherical filling defects from other causes of arachnoiditis or tumor implants are difficult to distinguish from tapeworm cysts, unless mobility of the latter can be demonstrated by positional variation. In our case several cysts showed rostrocaudal positional changes in response to tilting of the table, indicating that they were free-floating and able to gravitate within the cerebrospinal fluid of the thecal sac. This sign virtually excludes tumor and arachnoiditis as the cause of such filling defects and should be of help in diagnosing tapeworm-cyst disease in the proper clinical setting.

Alain D. Hyman
Cynthia E. Gray
Moutn Sinai Medical Center
New York, NY 10029

Charles Lanzieri
The Cleveland Clinic Foundation
Cleveland, OH 44106

Alexander S. Belman
South Nassau Community Hospital
Oceanside, NY 11572