



**Providing Choice & Value**

Generic CT and MRI Contrast Agents



FRESENIUS  
KABI

CONTACT REP

**AJNR**

**"Benign" metastasizing meningiomas.**

P M Som, M Sacher, S W Strenger, H F Biller and L I Malis

*AJNR Am J Neuroradiol* 1987, 8 (1) 127-130

<http://www.ajnr.org/content/8/1/127>

This information is current as  
of July 5, 2025.

# “Benign” Metastasizing Meningiomas

Peter M. Som<sup>1,2</sup>  
 Michael Sacher<sup>1</sup>  
 Scott W. Strenger<sup>3</sup>  
 Hugh F. Biller<sup>2</sup>  
 Leonard I. Malis<sup>3</sup>

Less than one in 1000 meningiomas metastasizes. Although the angioblastic and hemangiopericytic tumors are believed by some authors to metastasize with a greater frequency than the other histologic forms of meningioma, most investigators believe that neither the histologic pattern, local aggressiveness, size, nor location of the tumor can be used accurately to predict which tumors will metastasize. Three new cases are presented, bringing the total reported number of metastasizing meningiomas to 113. If the angioblastic meningiomas and hemangiopericytomas are eliminated from this group, 69 reported cases of “benign” metastasizing meningioma remain.

The malignant nature of a neoplasm is ultimately defined by its biological behavior and its ability to metastasize. Unfortunately, some tumors defy any reliable correlation between their histologic appearance or their local behavior and their ultimate biological propensity to metastasize. As an example, meningiomas are generally considered to be benign, slowly growing tumors that have a tendency to be locally aggressive [1–3]. Such local behavior has not been shown to be indicative of their malignancy, however [3]. The meningiomas that do metastasize are rare: since 1880, only 110 cases have been reported [1, 4–13]. This number represents an incidence of metastasis of less than 1 in 1000 meningiomas [14]. The purpose of this paper is to present three additional cases of metastatic meningioma (two documented with CT scans) and to examine the question of whether one can reliably predict which meningiomas will metastasize.

## Case Reports

### Case 1

The patient was a 50-year-old man who presented with a several-month history of headache. An angiogram revealed a parasagittal meningioma. He underwent a craniotomy with complete resection of the tumor. At the time of surgery, a second small parasagittal meningioma was discovered and removed. He did well for 3 years, and then his headaches returned. A workup revealed a tumor recurrence and he underwent a second craniotomy for removal of the meningioma. One year later, another recurrence was found and he had a third operation with complete removal of the tumor. He presented with chest pain 10 months later, and a chest radiograph revealed pulmonary metastases (Fig. 1). He died within 4 months and the autopsy revealed that the pulmonary metastases and all the surgical specimens of the intracranial tumors were the same benign meningioma. No areas of angioblastic meningioma were identified on any of the specimens.

### Case 2

The patient is a 56-year-old man who 17 years earlier presented with epistaxis. A nasal mass was discovered and he underwent a lateral rhinotomy for removal of a meningioma. Five years later he developed a headache and a workup revealed a bifrontal meningioma that involved both olfactory grooves. He underwent a craniotomy with excision of the meningioma.

Received April 16, 1986; accepted after revision July 16, 1986.

<sup>1</sup> Department of Radiology, The Mount Sinai Medical Center of CUNY, New York, NY 10029. Address reprint requests to P. Som, Department of Radiology, Mount Sinai Hospital, 1 Gustave Levy Place, New York, NY 10029.

<sup>2</sup> Department of Otolaryngology, The Mount Sinai Medical Center of CUNY, New York, NY 10029.

<sup>3</sup> Department of Neurosurgery, The Mount Sinai Medical Center of CUNY, New York, NY 10029.

*AJNR* 8:127–130, January/February 1987

0195–6108/87/0801–0127

© American Society of Neuroradiology



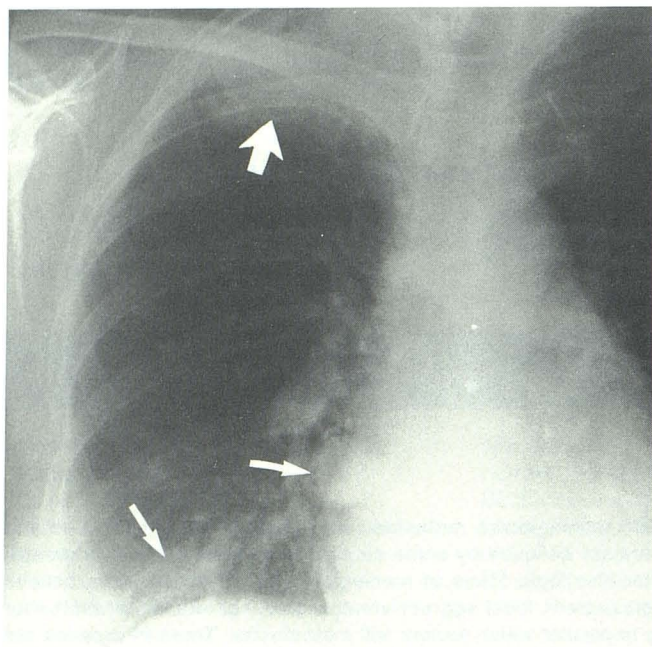


Fig. 1.—Posteroanterior chest radiograph reveals two metastatic parenchymal nodules (*small arrows*). Third apical mass (*large arrow*) was both parenchymal and pleural with erosion of posterior margin of third right rib.

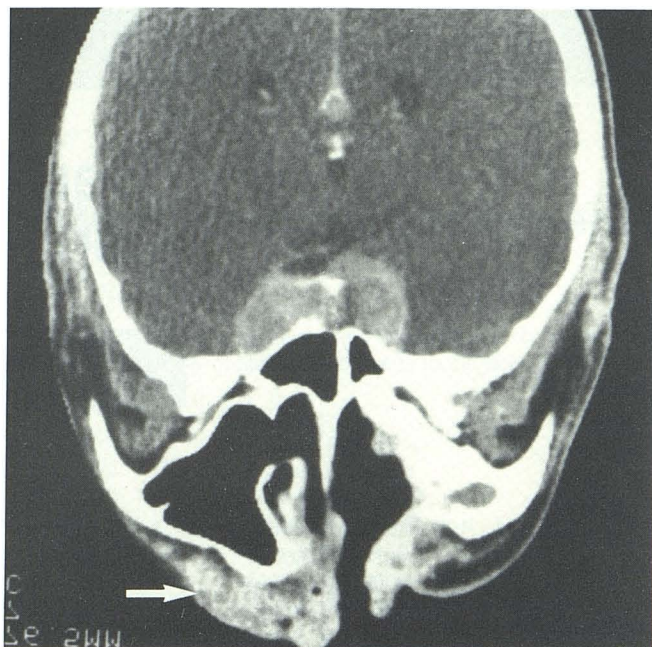


Fig. 2.—Modified coronal postcontrast CT scan reveals tumor mass in cavernous sinuses. In addition, there is biopsy-proven isolated metastatic tumor mass (*arrow*) in right side of face. Solely on the basis of CT appearance, this lesion could not be distinguished from granuloma.

Two years later he developed headaches and a workup revealed a right parietal meningioma that was removed via his earlier craniotomy. One year later he developed left proptosis and epistaxis. A meningioma recurrence was discovered. He developed a subfrontal abscess (presumably because of direct communication with the nasal vault) and, after surgery for this abscess, the tumor was removed via a craniofacial resection. Over the next 3 years he underwent five operations for local recurrences of the meningioma. On two of these occasions, isolated soft-tissue nodules were discovered on the lower face, at a distance from any incision lines (Fig. 2). These masses were resected and found to be metastatic meningioma. All pathologic specimens throughout his entire course have been the same benign meningioma, with no areas of angioblastic meningioma.

### Case 3

The patient was a 53-year-old woman who presented 6 years earlier with right retroorbital pain and headache. A right sphenoid-wing meningioma was discovered, which was resected via a craniotomy. She did well for 4½ years until she presented with recurrent headaches. A workup revealed a meningioma recurrence and she had a second operation with complete tumor removal. Eight months later she had a second recurrence and had her third craniotomy for removal of the sphenoid-wing meningioma. The entire tumor was again believed to have been resected; however, because of the multiple recurrences, prophylactic irradiation of 4500 rad (45 Gy) was given to the tumor bed. She did well for 6 months. Then she presented with what was clinically diagnosed as a right parotid mass. A CT scan revealed the parotid gland to be normal; however, there was an expansile, cystlike lesion in the angle of mandible (Fig. 3). A peroral biopsy revealed benign meningioma. During the next 3 weeks, while arrangements were being made for the surgical removal of the mandibular lesion, the patient developed weakness and chest pain.

She was admitted to the hospital and found to have metastases to the ribs, vertebra, lungs, and liver. She died 2 weeks later. All pathologic specimens revealed the same benign meningioma, with no areas of angioblastic change.

### Discussion

Although meningiomas represent between 13–18% of all primary intracranial tumors, the number of cases in which they metastasize to distant sites is small—an estimated 0.1% [3, 4, 14–16]. Meningiomas arise from clusters of meningocytes, often located at the tips of arachnoid villi [1–3]. Usually, these tumors are considered to be benign, solitary, and well-circumscribed neoplasms. Discovery of multiple lesions within the central nervous system can give rise to the suspicion of neurofibromatosis [3].

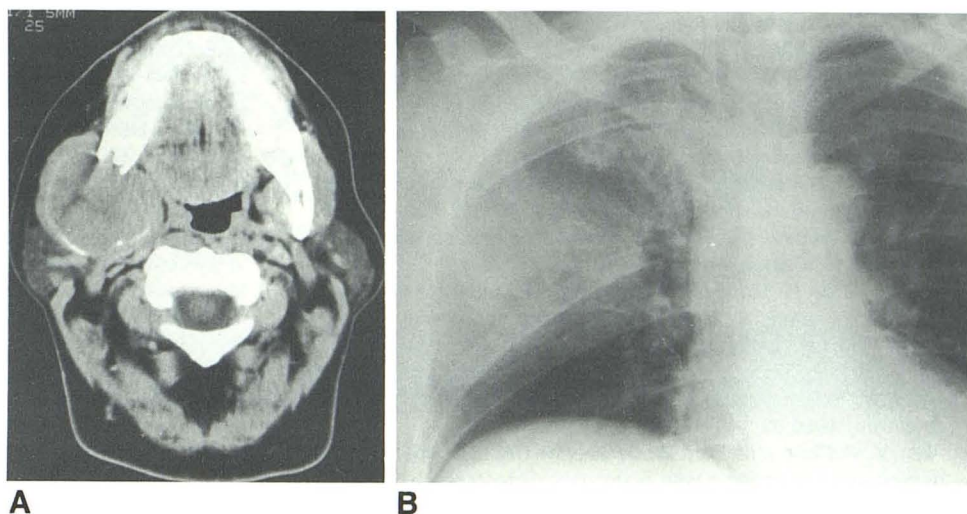
Characteristically, meningiomas are known to compress adjacent neural tissue and can be locally invasive of dura, dural sinuses, adjacent bones, and soft tissues. Such locally aggressive behavior is not necessarily indicative of malignancy, and is usually associated with benign cellular features [3, 9]. Four distinct histologic patterns of meningioma exist: synytial, fibroblastic, transitional, and angioblastic. Some authors suggest that the angioblastic form has a higher incidence of extracranial metastasis than the other types of meningioma and should therefore be considered as a potentially more malignant neoplasm if it does not actually represent a form of meningosarcoma or hemangiopericytoma [15, 17, 18].

Less than 10% of meningiomas have malignant features



Fig. 3.—A, Axial CT scan reveals "cystic" mass of right posterior mandible. Mass has markedly expanded bone; thin osseous rim remains at periphery of lesion.

B, Posteroanterior chest radiograph reveals large, metastatic, parenchymal and pleural mass in right chest that has eroded posterior portion of fifth and sixth ribs.



[7, 18]. Criteria that have been suggested for determining the malignancy of a meningioma include rapid rate of recurrence, aggressive local invasiveness, a high mitotic index of greater than three mitoses per 10 high-power fields, atypical histologic features, and the presence of remote metastases [15]. With the exception of the last criterion, which is by definition indicative of malignancy, each has a variable and significant margin of error in any attempt to predict biological behavior. It is possible that, in the future, cytogenetics may play a predictive role, since malignant meningiomas appear to have nonrandom karyotypic aberrations, especially in chromosome 22 [5].

The frequency of reported sites for metastases is 60% pulmonary; 34% abdominal (primarily liver); 18% cervical lymph nodes; 11% long bones, pelvis, and skull; 9% pleura; 7% vertebra; 7% central nervous system; and 5% mediastinum [1–20]. Patients with metastatic meningioma have an average age of 39 years (range, 1 week to 83 years), and 75% are between 40–60 years old. The male:female ratio is 3:2, which reverses the standard 2-to-4-times predominance of women among patients with solitary, nonmetastasizing meningioma [3, 7].

The rarity of extracranial metastases in meningiomas may be due to the strong cohesiveness of these tumor cells, the absence of intracranial lymphatics, and the possibility that the extracranial organs may not provide a "fertile soil" for these neoplastic cells [2]. The low metastatic rate is especially intriguing when one considers that meningiomas commonly invade the dural sinuses and thus have access to the vascular system [2]. Their hematogenous spread via the caval circulation probably explains the high incidence of pulmonary metastases, while involvement of Batson's plexus may explain spread to the vertebrae [7, 9]. Surgical intervention has also been implicated in disseminating meningioma cells via the CSF and the venous circulation; however, 13 cases in the literature were not operated on before the discovery of their metastases [1, 9, 21].

In virtually every reported case of a metastasizing menin-

gioma, the histopathologic features of the metastases were similar, if not identical to, the primary lesion, even if both appeared totally benign [6]. When one critically analyzes the 113 reported cases of metastatic meningioma, including the three cases presented here, several difficulties arise. Some of the earliest reported cases were poorly illustrated, which does not allow a true assessment of the histologic character of the case. A second problem arises from the disagreement between neuropathologists as to what constitutes a malignant meningioma versus a primary meningiosarcoma [4]. Lastly, there is some controversy over how to classify hemangiopericytic tumors of the meninges. Owing to their apparently high malignancy potential, some authors do not consider them true meningiomas [1, 4, 9]. If one eliminates from consideration the 36 hemangiopericytic tumors, the four angioblastic lesions, and the four cases too poorly documented for present review, the total number of cases of metastasizing "benign" meningioma is reduced to 69. Several reviews of the literature failed to identify any particular pattern of meningioma that subsequently metastasized. We therefore conclude that the recurrence or metastatic potential of a benign meningeal tumor cannot be predicted by its histologic pattern, location, or size [6, 20].

#### REFERENCES

1. Miller DC, Ojemann RG, Proppe KH, McGinnis BD, Grillo HC. Benign metastasizing meningiomas. *J Neurosurg* 1985;62:763–766
2. Jestico JV, Lantos PL. Malignant meningioma with liver metastases and hypoglycaemia: a case report. *Acta Neuropathol (Berl)* 1976;35:357–361
3. Barnes L, Peel RL, Verbin RS. Tumors of the nervous system. In Barnes L, ed. *Surgical pathology of the head and neck*, Vol. 1. New York: Dekker, 1985:698–700
4. Kepes JJ. Meningiomas: biology, pathology and differential diagnosis. Paris: Masson, 1982:190–199
5. Thomas HG, Dolman CL, Berry K. Malignant meningioma: clinical and pathological features. *J Neurosurg* 1981;55:929–934

6. Salvati CA. Metastatic meningioma. *Clin Neurol Neurosurg* **1981**;83:169-172
7. Wu JK, Kasdon DL, Whitmore EL. Metastatic meningioma to cervical vertebra: case report. *Neurosurgery* **1985**;17:75-79
8. Wende S, Bohl J, Schubert R, Schulz V. Lung metastasis of a meningioma. *Neuroradiology* **1983**;24:287-291
9. Wasserkrug R, Peyser E, Lichtig C. Extracranial bone metastasis from intracranial meningiomas. *Surg Neurol* **1979**;12:480-484
10. Peck AG, Dedrick CG, Taft PD. Pulmonary metastases from intracerebral meningioma. *AJR* **1976**;126:419-422
11. Morild I, Bang G, Mork S. Hemangiopericytic meningioma with extracranial spread to multiple sites without intracranial recurrence. *Clin Neuropathol* **1984**;3:128-130
12. Anderson C, Rorabeck CH. Skeletal metastases of an intracranial malignant hemangiopericytoma: report of a case. *J Bone Joint Surg [Am]* **1980**;62:145-148
13. Allen IV, McClure J, McCormick D, Gleadhill CA. LDH isoenzyme pattern in a meningioma with pulmonary metastases. *J Pathol* **1977**;123:187-191
14. Bauman J. A contribution to the problem of extracranial metastasis in meningiomas. *Confin Neurol* **1958**;18:394-397
15. Rubinstein LJ. *Tumors of the central nervous system. Atlas of tumor pathology*, Series II, Fascicle 6. Washington, D.C.: Armed Forces Institute of Pathology, **1972**:169-190
16. Strang RR, Tovi D, Nordenstam H. Meningioma with intracerebral, cerebellar and visceral metastases. *J Neurosurg* **1964**;21:1098-1107
17. Burger PC, Vogel FS. *Surgical pathology of the nervous system and its coverings*. New York: Wiley, **1976**:74-97
18. Shuangshoti S, Hongsaprabhas C, Netsky MG. Metastasizing meningioma. *Cancer* **1970**;26:832-841
19. Karasick J, Mullan S. A survey of metastatic meningiomas. *J Neurosurg* **1974**;39:206-212
20. Simpson D. The recurrence of intracranial meningiomas after surgical treatment. *J Neurol Neurosurg Psychiat* **1957**;20:22-39
21. Ludwin SK, Conley FK. Malignant meningioma metastasizing through the cerebrospinal pathways. *J Neurol Neurosurg Psychiat* **1975**;38:136-142