



Providing Choice & Value

Generic CT and MRI Contrast Agents



FRESENIUS
KABI

CONTACT REP

AJNR

Air in the cavernous sinus: a new sign of septic cavernous sinus thrombosis.

J T Curnes, J L Creasy, R L Whaley and J H Scatliff

AJNR Am J Neuroradiol 1987, 8 (1) 176-177

<http://www.ajnr.org/content/8/1/176.citation>

This information is current as
of July 8, 2025.

tomography, myelography, and CT metrizamide myelography (CTMM), was lymphoma. These investigations had revealed a mediastinal mass with bony destruction of the body of the second thoracic vertebra and mild extradural compression at the same level. None of these techniques revealed the true extent of the lesion. MR clearly showed this mediastinal mass to be an abscess extending from the upper thoracic region to the nasopharynx (Fig. 1). Furthermore, because MR showed the lesion as nonlocal, we decided to aspirate it through its dependent (thoracic) portion. This procedure, with subsequent antituberculous treatment, produced a complete resolution of the abscess as documented by the follow-up MR scan (Fig. 2).

We feel MR is definitely superior to CT scanning for diagnosing osteomyelitis and abscess [3]. In our patient, it not only delineated the extent of the disease and its relation to normal anatomy, but facilitated treatment.

V. Wagle
D. Melanson
R. Ethier
R. Leblanc

Montreal Neurological Hospital and Institute
McGill University
Montreal, Quebec, Canada H3A 2B4

REFERENCES

1. Modic MT, Weinstein MA, Pavlicek W, Boumpfrey F, Starnes D, Duchesneau PM. Magnetic resonance imaging of the cervical spine: technical and clinical observations. *AJNR* 1984;5:15-22
2. Hyman RA, Edwards JH, Vacirca SJ, Stein HL. 0.6 T MR imaging of the cervical spine: multislice and multiecho techniques. *AJNR* 1985;6:229-236
3. Davidson HD, Steiner RE. Imaging in infections of the CNS. *AJNR* 1985;6:499-504

Air in the Cavernous Sinus: A New Sign of Septic Cavernous Sinus Thrombosis

Several articles have documented the importance of CT scanning in the diagnosis of cavernous sinus thrombosis [1-4]. A recent article

by Ahmadi et al. [1] reviewed the CT literature on this subject and presented four cases of their own in which multiple irregular filling defects were seen in the enhancing cavernous sinus. We report an apparently unique case of air within the cavernous sinus bilaterally in a patient with proven septic cavernous sinus thrombosis.

Case Report

An 18-year-old black man presented with primary complaints of headache, symptoms of upper respiratory infection, and right eye pain. A diagnosis of right otitis media was made and treatment with amoxicillin was begun. The patient returned to the emergency room 2 days later with a fixed right pupil, total right ophthalmoplegia, and left sixth nerve paresis. He was transferred to North Carolina Memorial Hospital.

Examination at the hospital revealed a diaphoretic man with clear sensorium, temperature 39.2°C, and markedly decreased vision in the right eye as well as a fixed dilated right pupil and total ophthalmoplegia. There was no proptosis of either eye. Left sixth nerve palsy was also noted. There was slight nuchal rigidity and a positive Brudzinski sign, but no other neurologic findings. Lumbar puncture revealed xanthochromic fluid with 780 RBC/mm³ and a total nucleated cell count of 4200/mm³; 80% of the cells were neutrophils, and macrophages and atypical lymphs were also present. The CSF glucose was 6 mg/dl and protein was 560 mg/dl. A CT scan on the day of admission showed opacification of the right maxillary, ethmoid, and sphenoid sinuses, as well as air within both cavernous sinuses (Figs. 1A and 1B). No brain abscess was identified. Cultures of both blood and sinus grew *Peptostreptococcus anaerobius* and *Fusobacterium nucleatum*.

Two days later, the patient developed a left hemiparesis. Cerebral angiography revealed bilateral severe stenosis of the cavernous internal carotid arteries bifurcation and a right intracavernous carotid artery aneurysm (Fig. 2). The cavernous sinuses did not fill. The patient died 3 days later.

Gross examination of the base of the skull revealed diffuse hemorrhage; the clot distended both cavernous sinuses. Microscopic examination of the base of the skull showed an acute osteomyelitis of the bone extending from the paranasal sinuses to the dura. In both

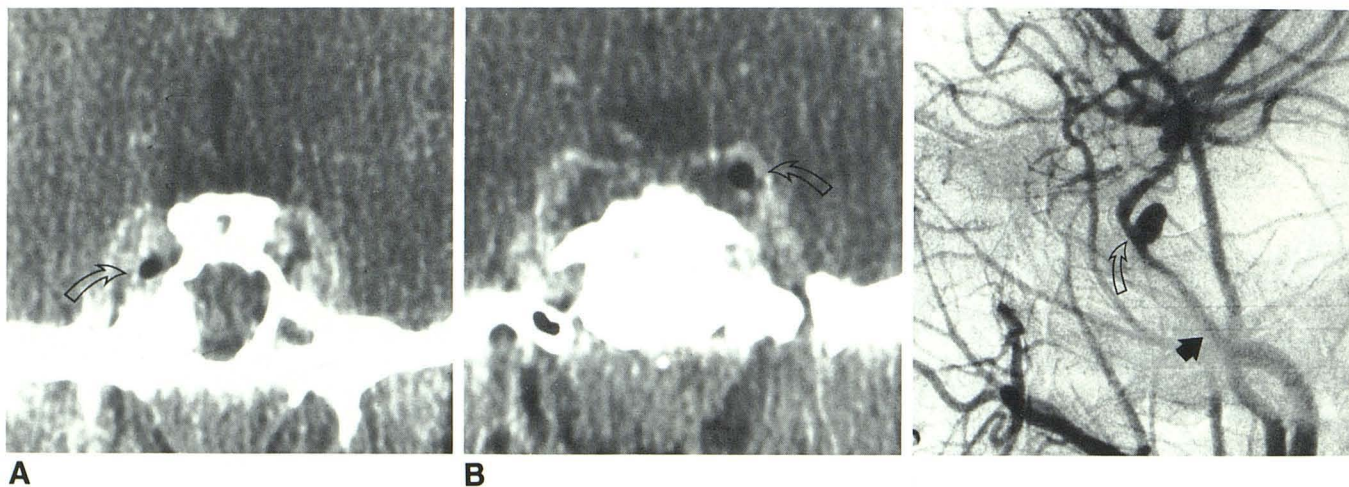


Fig. 1.—A, Coronal CT scan with contrast infusion shows air within right cavernous sinus (arrow), bulging of sinus walls, and opacity of sphenoid sinus.

B, Another section more posterior shows air in left cavernous sinus (arrow), as well as irregular low-density areas within sinus, representing thrombus.

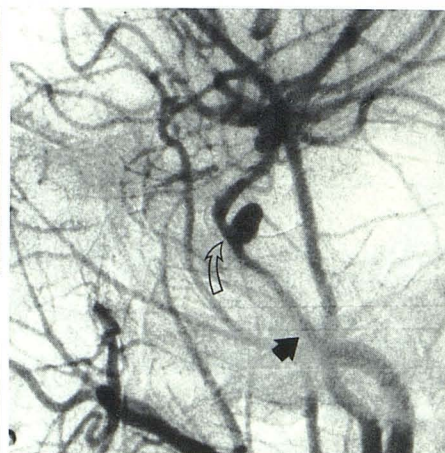


Fig. 2.—Right common carotid arteriogram reveals narrowing of internal carotid beginning at base of skull (solid arrow) continuing up cavernous carotid where 5 x 3 mm aneurysm is seen (open arrow).

cavernous sinuses acute inflammation, granulation tissue, and thrombus surrounded the nerves and internal carotid arteries. The left carotid artery was intact, but focally inflamed. The right internal carotid artery was focally necrotic, acutely inflamed and ruptured, with hemorrhage emanating from the defect.

Discussion

We are not aware of any instances of air within the cavernous sinus in a normal patient or after trauma. Our case demonstrates several of the reported findings in cavernous sinus thrombosis including bulging of the lateral walls, irregular low-attenuation filling defects within the cavernous sinus, and proptosis (Fig. 1).

It is unclear whether the air within the sinus originated from a gas-forming organism or via direct extension from one of the sinuses via the veins. The organisms that were cultured from the blood and sinus postmortem can be associated with gas formation. The presence of a large amount of fat within the cavernous sinus was reported by Bachow et al. [4] in patients with Cushing disease. Careful measurement of the CT HU will discriminate between the two, since fat has a value of minus 60 HU, whereas air, as in our case, has a value of minus 200 HU or greater.

Narrowing or occlusion of the carotid artery associated with cavernous sinus thrombosis has been well documented in the literature [2, 5]. In addition, aneurysms associated with septic emboli to the cerebral vasculature have been reported. However, a mycotic aneurysm involving the cavernous carotid artery secondary to bacterial invasion of the wall is a previously unrecognized complication. It is likely that a septic embolus from this aneurysm led to the infarction. While angiography in the diagnosis of cavernous sinus thrombosis is of limited value, it may be indicated to exclude such aneurysm formation or even carotid occlusion, particularly in cases of cerebral infarction.

John T. Curnes
Jeff L. Creasy
Robert L. Whaley
James H. Scatliff

University of North Carolina School of Medicine
Chapel Hill, NC 27514

REFERENCES

1. Ahmadi J, Keane JR, Segall HD, Zee C. Observations pertinent to septic cavernous sinus thrombosis. *AJNR* 1985;6:755-758
2. Segall HD, Ahmadi J, McComb JG, Zee CS, Becker TS, Han JS. Computed tomographic observations pertinent to intracranial venous thrombotic and occlusive disease in childhood. *Radiology* 1982;143:441-449
3. Clifford-Jones RE, Ellis CJK, Stevens JM, Turner A. Cavernous sinus thrombosis. *J Neurol Neurosurg Psychiatry* 1982;45:1092-1097
4. Bachow TB, Hesselink JR, Aaron JO, Davis KR, Taveras JM. Fat deposition in the cavernous sinus in Cushing disease. *Radiology* 1984;153:135-136
5. Matthew NT, Abraham J, Taori GM, Iyer GV. Internal carotid artery occlusion in cavernous sinus thrombosis. *Arch Neurol* 1971;24:11-16

The Ascending Pharyngeal Artery: A Collateral Pathway in Complete Occlusion of the Internal Carotid Artery

The ascending pharyngeal artery is the smallest branch of the external carotid artery [1], but it is one of the most important branches because of the structures it supplies and the collateral pathways in

which it participates. This report describes two cases in which common carotid angiography showed complete occlusion of the internal carotid artery at its origin. Subsequent vertebral angiography in both cases showed reconstitution of this vessel several millimeters above the origin by the ascending pharyngeal artery, which had an unusual origin from the internal carotid artery [2]. Endarterectomy as a technical option was feasible in both cases because the occluded segments were only millimeters in length.

The first patient, a 59-year-old man, presented 5 days before admission with a sudden paresis of the right arm and leg. Angiography revealed complete occlusion of the left internal carotid artery with a small, smooth stump (Fig. 1A). A left vertebral arteriogram demonstrated reconstitution of the left internal carotid artery just above the occlusion (Fig. 1B). Collateral supply was from muscular branches of the vertebral artery, which anastomosed with muscular branches of the ascending pharyngeal artery. This vessel, which originated from the proximal internal carotid artery, maintained patency of the carotid artery throughout its length (Fig. 1C).

The second patient, a 61-year-old man, had experienced an episode of light headedness and left-sided weakness 1 month before admission. Angiography revealed bilateral internal carotid artery occlusions and the left vertebral study showed reconstitution of a patent left internal carotid artery via the ascending pharyngeal artery, which again originated from the proximal internal carotid artery.

In both cases, the ascending pharyngeal arteries functioned as important collateral pathways, maintaining patency of proximally occluded internal carotid arteries. The continued patency was made possible by the unusual origin of the ascending pharyngeal artery from the internal carotid artery in both cases.

The ascending pharyngeal artery most commonly arises from the posterolateral aspect of the proximal external carotid artery, close to the origin of the lingual artery and just below that of the occipital artery [3]. There are several variations in its point of origin, the most common being (a) from the carotid bifurcation in the angle between the internal and external carotid arteries, (b) from the internal carotid artery above its origin, sometimes paired with the occipital artery, and (c) from the external carotid artery, combined with the occipital artery or just above it. The anterior branch of this vessel supplies pharyngeal and palatine tissues. The posterior branch gives important meningeal supply to the skull base and muscular branches to the prevertebral muscles. These muscular branches can anastomose with branches originating from the occipital and vertebral arteries and it was these muscular anastomoses from the vertebral artery that provided the collateral channels in our two cases.

It is well known that it is important to perform vertebral angiography in cases of proximal common carotid occlusion, since vertebral-to-occipital artery collaterals may keep the ipsilateral internal carotid artery patent [4]. Similarly, one should be aware of potential collateral pathways through anatomic variants of the ascending pharyngeal artery. Vertebral angiography, therefore, should be considered in cases of proximal internal carotid artery occlusion when the ascending pharyngeal artery has not been clearly identified as a branch from the ipsilateral external carotid artery on the common carotid angiogram.

David M. Pelz
Allan J. Fox
Fernando Viñuela
Jacques E. Dion
L. Agnoli

University Hospital, University of Western Ontario
London, Ontario, Canada N6A 5A5

REFERENCES

1. Salamon G, Faure J, Raybaud C, Grisoli F. The external carotid artery. In: Newton TH and Potts DG, eds. *Radiology of the skull*