



Discover Generics

Cost-Effective CT & MRI Contrast Agents



FRESENIUS
KABI

WATCH VIDEO

AJNR

Comparison of MR imaging and CT in patients with intracranial aneurysm clips.

S Holtås, M Olsson, B Romner, E M Larsson, H Säveland and L Brandt

AJNR Am J Neuroradiol 1988, 9 (5) 891-897

<http://www.ajnr.org/content/9/5/891>

This information is current as of June 23, 2025.

Comparison of MR Imaging and CT in Patients with Intracranial Aneurysm Clips

Stig Holtås¹
 Magnus Olsson²
 Bertil Romner³
 Elna-Marie Larsson¹
 Hans Säveland³
 Lennart Brandt³

CT and MR imaging of the brain were performed without complications in 16 patients who had undergone surgery for a ruptured aneurysm with the use of nonferromagnetic Yasargil 316 or Sugita Elgiloy clips. MR was performed on a 0.3-T Fonar β -3000M imaging system. The artifacts caused by the clips were smaller on MR than on CT, and, therefore, anatomic structures such as the brainstem and temporal lobes were better visualized on MR. Brain-tissue lesions corresponding to the frontotemporal surgical approach were seen with MR in seven patients and with CT in six. In three patients temporal-lobe lesions seen on MR were not seen on CT because of beam-hardening artifacts. Lesions unrelated to the region of surgery were seen with MR in nine patients and with CT in five.

In conclusion, MR was safe and superior to CT both in demonstrating anatomic details and in detecting tissue lesions in patients with aneurysm clips.

In some patients with intracranial aneurysm clips there are reasons to study the brain. CT is not ideal for this purpose because beam-hardening artifacts caused by the clips make interpretation in the region of surgery impossible or unreliable.

MR imaging is a valuable method for detecting and characterizing brain lesions, and its sensitivity is higher than that of CT, especially in the white matter [1]. MR has been considered contraindicated in patients with intracranial aneurysm clips because of the risk of clip motion [2]; therefore, patients have not been studied systematically with this method. However, the risk of clip motion is only present when ferromagnetic clips have been used [3, 4].

We have studied the forces on and magnetization of some commonly used ferromagnetic and nonferromagnetic aneurysm clips when introduced into our 0.3-T MR scanner.* The artifacts caused by the clips were studied on a phantom. Yasargil Phynox and Sugita Elgiloy clips were not magnetized and did not move when introduced into the scanner. Furthermore, the artifacts caused by the clips were rather limited (B. Romner et al., unpublished data). Therefore, we considered MR to be a safe and meaningful examination in patients with these clips. The aim of the present study was to evaluate the MR quality and diagnostic information in patients with nonferromagnetic Yasargil 316 and Sugita Elgiloy clips and to compare the results with CT.

Subjects and Methods

Sixteen patients, four men and 12 women 27–70 years old (mean age, 48 years), in whom intracranial metal clips had been implanted during aneurysm surgery 4 years earlier were examined with MR and CT on the same day. For the CT study, a Toshiba TCT 80-B scanner was used; 10-mm-thick slices were obtained in the orbitomeatal plane. The MR examinations were performed on a 0.3-T Fonar β -3000M imaging system with a vertical magnetic field. A sagittal scout image was used for orientation of the axial slices in the same plane as used in the CT examination. For the axial slices two spin-echo pulse sequences, 400/16 and 2000/56 (TR/TE), were obtained. The other parameters included a 7-mm slice thickness, 10-mm

Received January 13, 1988; accepted after revision April 21, 1988.

This work was supported by a grant from the Swedish Medical Research Council, project No. B88-39x-08164-02B.

¹ Department of Diagnostic Radiology, University Hospital, S-221 85 Lund, Sweden. Address reprint requests to S. Holtås.

² Department of Radiation Physics, University Hospital, S-221 85 Lund, Sweden.

³ Department of Neurosurgery, University Hospital, S-221 85 Lund, Sweden.

AJNR 9:891-897, September/October 1988

0195-6108/88/0905-0891

© American Society of Neuroradiology

* Fonar β -3000M, Fonar Corp., Melville, NY.

slice interval, 25.6-cm field of view, 256×256 matrix, 384 sampling levels, sagittal (y-axis) frequency direction, and 7-min 42-sec (short TR/TE) and 12-min 50-sec (long TR/TE) scanning times. The patients had nonferromagnetic Yasargil 316 (mini, standard, or large) or Sugita Elgiloy (standard or large) clips. For information about the composition of the alloy in the aneurysm clips the reader is referred to the work of New et al. [3].

Ten patients had a single Yasargil clip, two had two, one had three, and one had five. The size of the Yasargil clips varied between 13 and 25 mm and the weight between 132 and 461 mg. In one patient two Yasargil clips and one Sugita clip had been used, and in one patient three Yasargil clips and one Sugita clip were used. The sizes of the Sugita clips were 15 and 22 mm and the weights were 405 and 438 mg. Five patients had undergone surgery because of a single aneurysm of the internal carotid artery; four had middle cerebral artery aneurysms, three had an aneurysm of the anterior communicating artery, and one had an anterior cerebral artery aneurysm. One patient had bilateral middle cerebral artery aneurysms, one had bilateral middle cerebral and internal carotid artery aneurysms, and one had an aneurysm of the anterior cerebral artery.

Lesions in the brain and artifacts from the aneurysm clips were evaluated. MR and CT examinations were evaluated separately by the same neuroradiologist, without knowledge of the results of the other examination. Finally, the MR and CT examinations were evaluated together and differences noted.

Results

The patients did not experience any adverse effects during or after the examinations.

Artifacts

On MR, the artifacts around the clips consisted of a center with signal void and a thin rim of increased signal on both sides of the center in the direction of the frequency axis (sagittal direction). No diagnostic information was available in

this region (Figs. 1A and 1B). Close to this area there was some distortion; however, it did not affect the diagnostic information to any great degree. In the other areas the image was not affected by the clips. The artifact was somewhat larger on the long TR/TE images compared with the short TR/TE images. There was a correlation between the size of the clip and the size of the artifact (compare Figs. 1 and 2).

On CT, the artifact consisted of a center of complete X-ray attenuation corresponding to the metal in the clips, and outside this was a zone of dense beam-hardening artifacts most pronounced along the long axis of the clips. In this region no diagnostic information was obtained (Fig. 1C). Streak artifacts were seen radiating outside this region, with the diagnostic information gradually improving with increasing distance from the clip.

The mean diameters of the artifacts resulting in complete loss of diagnostic information were 3 cm (range, 1–5 cm) on CT, 2.6 cm (range, 1.5–4 cm) on short TR/TE sequences, and 3.1 cm (range, 1.5–4 cm) on long TR/TE sequences. The central part of the artifacts, without diagnostic information, was close in size on CT and MR, but the rapid change to normal image quality outside this region on MR enabled evaluation of structures rather close to the clip. These structures often were difficult to evaluate on CT. For example, the temporal horn, the tip of the temporal lobe, and the brainstem often were difficult to see on CT, but were visualized on MR (Fig. 2).

Lesions Related to Surgical Trauma

CT revealed low-attenuation lesions in the brain parenchyma in the frontal and/or temporal lobe adjacent to the artifact (region of surgery) in six patients. On MR such lesions were found in seven patients. The signal from the lesions was increased on long TR/TE and decreased on short TR/TE

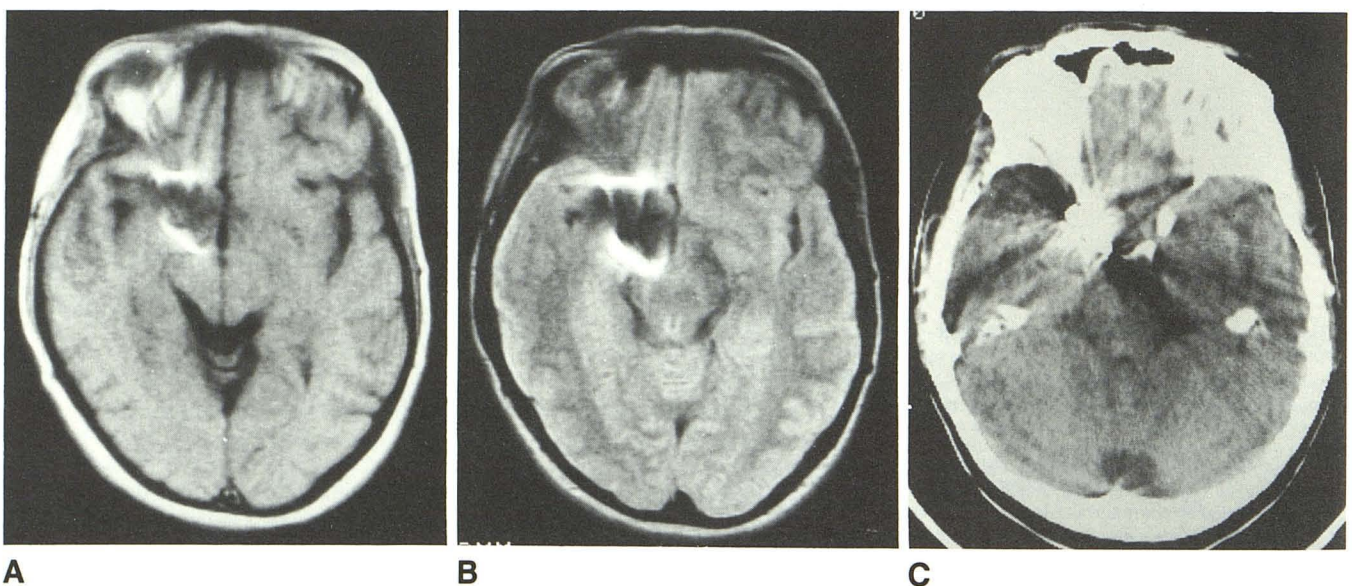


Fig. 1.—Short TR/TE (A), long TR/TE (B), and CT (C) images in patient with Yasargil aneurysm clip (18 mm, 337 mg). Note rim of increased signal in frequency-encoding (sagittal) direction. Except for artifact, findings are normal in region of surgery.

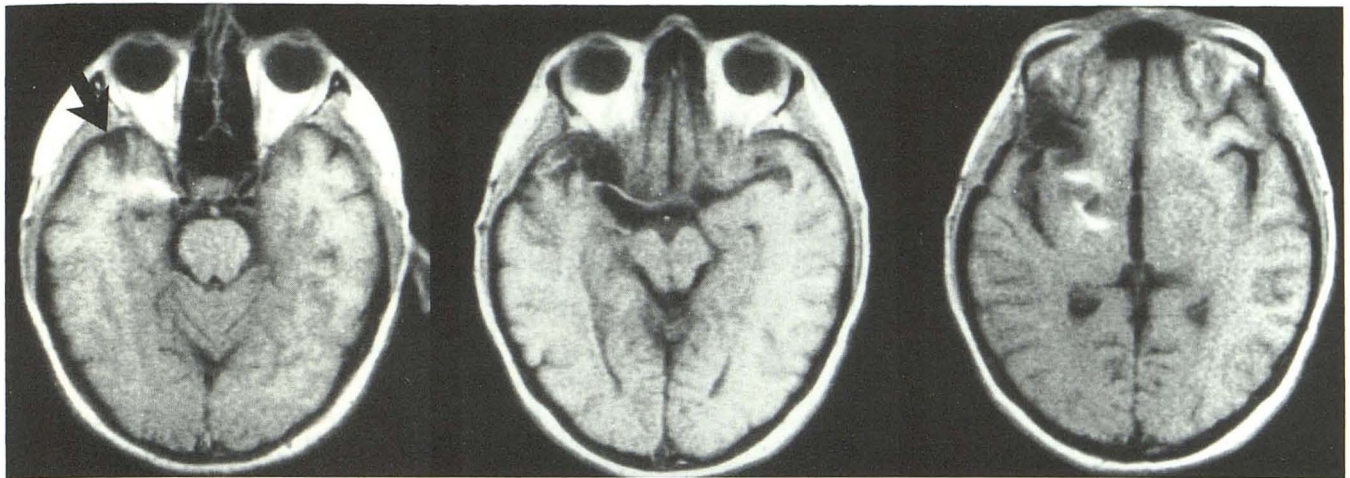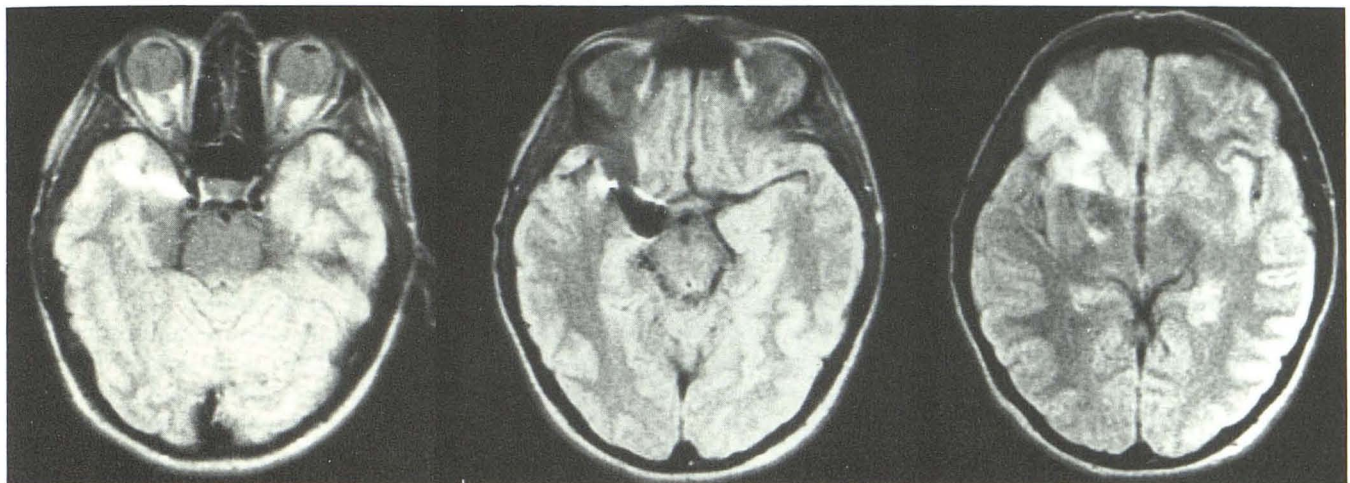
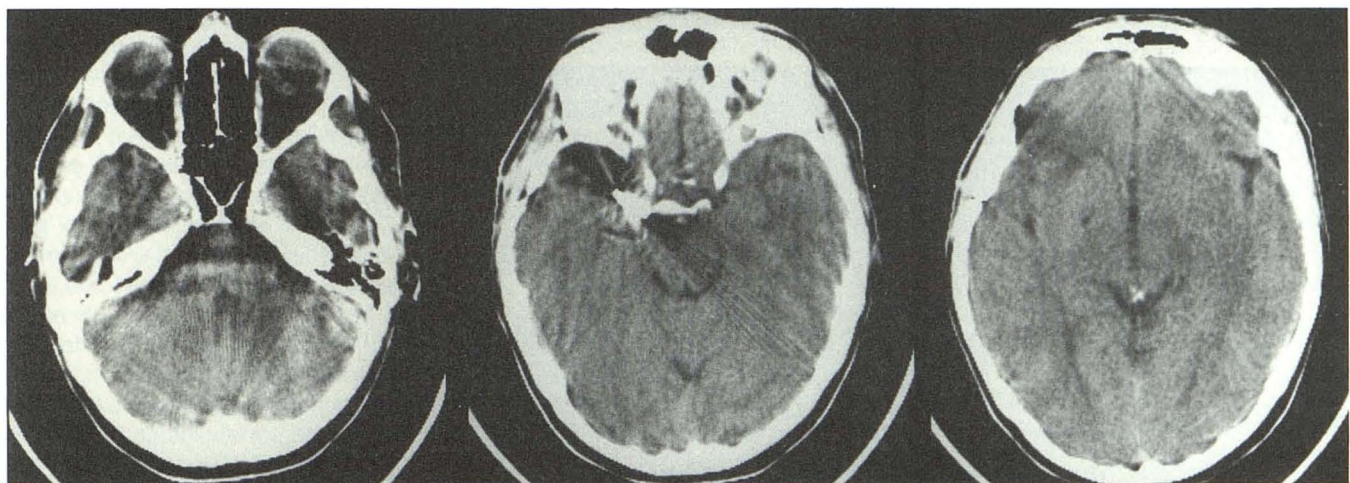
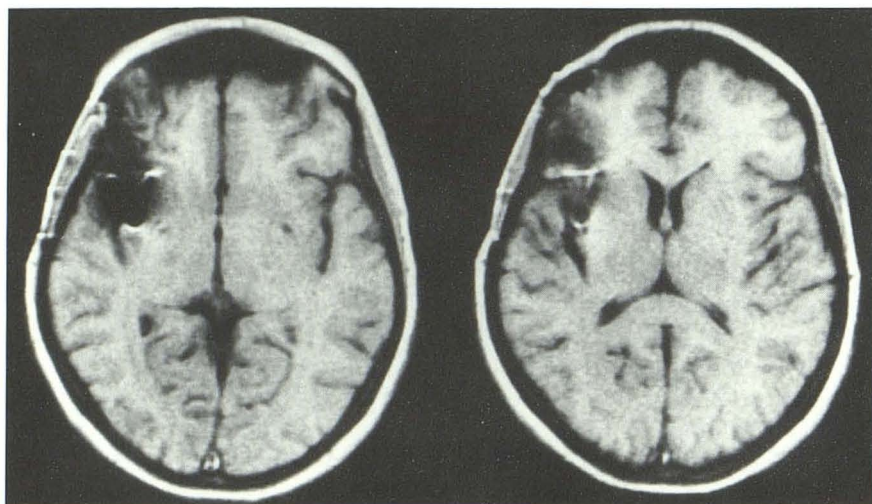
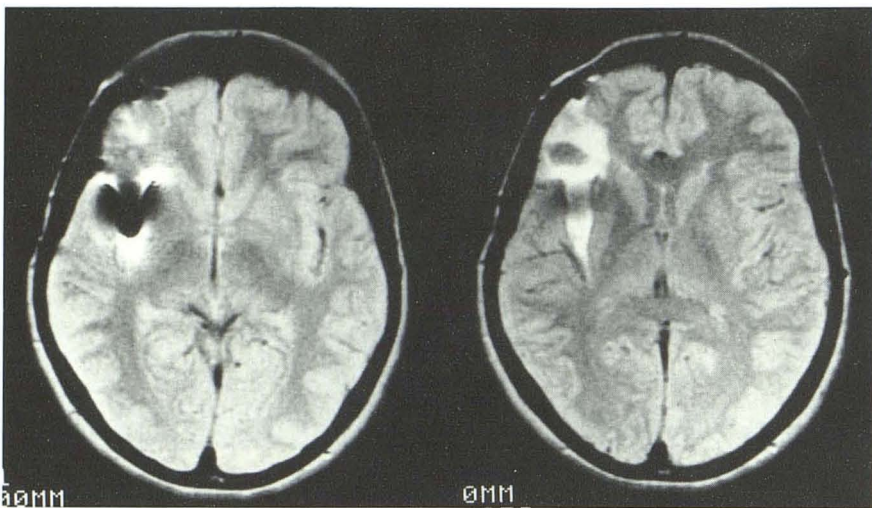
**A****B****C**

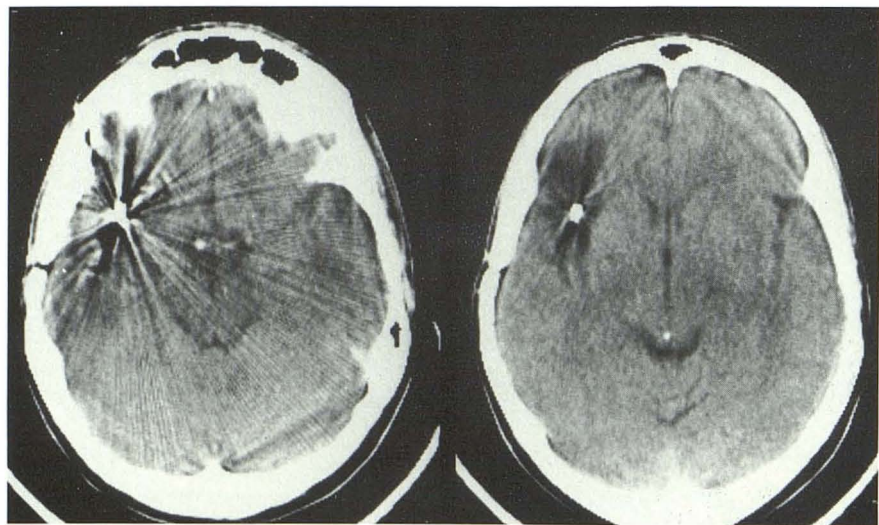
Fig. 2.—Short TR/TE (A), long TR/TE (B), and CT (C) images in patient with small Yasargil clip (13 mm, 139 mg). Temporal lobe and brainstem are better seen on MR. Small focal atrophy in tip of temporal lobe on short TR/TE image (arrow) is easily overlooked on CT. Lesion in frontal lobe is related to surgical approach and is best seen on long TR/TE images.



A



B



C

Fig. 3.—Short TR/TE (A), long TR/TE (B), and CT (C) images in patient with Yasargil clip (18 mm, 333 mg). Lesion in sylvian fissure and frontal lobe is best appreciated on long TR/TE images.

images. The lesions appeared smaller on CT than on MR and ranged in volume from 5 to 100 ml on MR (Figs. 1–3). In three patients temporal-lobe lesions seen on MR were not seen on CT because of beam-hardening artifacts caused by the clips. The long TR/TE images were more efficient in demonstrating lesions than the short TR/TE images, and in one case a white-matter frontal lesion was seen only on long TR/TE images. The short TR/TE images, however, were superior in demonstrating the anatomy; for example, widening of the temporal horn and local atrophy of the tip of the temporal lobe.

Lesions Unrelated to Region of Surgery

CT revealed five low-attenuation lesions that were not directly connected to the region of surgery. One patient had an infarct corresponding to the distribution area of the pericallosal artery (Fig. 4) and four patients had small lesions of 1–3 ml. MR showed all these lesions, which were of high signal on long TR/TE images, and demonstrated small white-matter lesions in four other patients in whom no lesions were seen on CT. In four of the five patients who had lesions unrelated to the region of surgery on CT, MR was able to reveal more lesions than were seen on CT. In three patients, all more than 50 years old, small white-matter lesions of high signal on long TR/TE images were seen on MR on the side contralateral to the aneurysm.

Discussion

MR has been considered contraindicated in patients with intracranial aneurysm clips of any type at most MR centers because of the risk of clip dislodgment [2]. This is certainly a wise policy if there is any doubt about the type of clip used at surgery. However, in some patients with aneurysm clips and neurologic symptoms, MR is indicated when CT cannot adequately demonstrate the disease causing the symptoms. In experimental work with the Yasargil 316 and Sugita Elgiloy clips used in the present study, no magnetization or clip motion occurred when the clips were introduced into our Fonar β -3000M scanner. Furthermore, the artifacts caused by the clips were rather limited (B. Romner et al., unpublished data). On the basis of these results and the findings of other authors regarding RF-heating effects and clip motion [4, 5], we considered it to be safe to examine patients with these clips in our MR scanner. However, it should be noted that older Yasargil and Sugita clips have a different alloy composition and slight ferromagnetic properties.

Ferromagnetic properties might be induced in nonferromagnetic material by tooling and by deformation during surgery, thus discounting the reliability of ferromagnetic determinations based on experimental data [2]. The risk is probably very low of notable ferromagnetism having been introduced into nonferromagnetic aneurysm clips in this manner. This assumption is supported by the results of our experimental study, in which the aneurysm clips we examined had been opened and closed many times because they had been used for demonstration and training. Despite this, no magnetization could be measured and the artifacts seen in the phantom study were not as large as when ferromagnetic clips were used. To rule out the risk of alteration of the magnetic

properties of the clips due to previous exposure to a high magnetic field, we conducted a test in which the nonferromagnetic clips used in the study were exposed to a field of 2.3 T and then examined in the Fonar scanner. The size of the artifact was the same before and after exposure to the high magnetic field, thus ruling out a significant change in magnetic properties. Another factor further reducing the possible risk in our patients is that all our patients had undergone surgery 4 years before the MR examination; therefore, the clips most likely were surrounded by fibrous tissue that prevented clip motion. It has been shown in experimental animals that ferromagnetic clips can be dislodged by the magnetic forces early after surgery [3, 4]. Our MR scanner has a rather low field strength (0.3 T), although theoretically the risk should not be increased at higher field strengths. However, it might be wise to use a more conservative approach at higher field strengths because a mistake could have serious consequences. Furthermore, the artifacts probably will be increased due to the increased magnetic susceptibility effects at higher field strengths.

Aneurysm clips cause artifacts on both MR and CT images, and the artifacts make interpretation impossible within a diameter of approximately 3 cm around the center of the clip with both methods (Figs. 1–3). However, MR was superior to CT outside the central area of the artifact because of the rapid change to normal image quality, enabling evaluation of anatomic structures and disease; on CT, streak artifacts disturbed evaluation over a large area, with a gradual increase in information with increasing distance from the clip. It should also be noted that some patient motion greatly increases the beam-hardening artifacts.

The artifacts on MR images are caused by the paramagnetic properties of the alloy in the clips, leading to a local distortion of the magnetic field and a frequency error resulting in absence of RF excitation and causing a signal void close to the clips [6]. Some authors have suggested that the artifacts caused by nonferromagnetic alloys result from eddy currents in the material induced by the changing magnetic field from the gradient coils [2, 6]. This explanation is improbable because such excellent conductors as gold and silver do not cause artifacts of this type in MR imaging.

There was always a rim of increased signal on both sides of the area of signal void in the frequency-encoding direction. This also is caused by the distortion of the magnetic field, but in this region the frequency error is smaller and causes a spatial mismatching within the imaging area instead of the total loss of signal seen in the central part where the frequency error is larger. This artifact corresponds to the halo around the metal observed by New et al. [3], but in their experiments back projection was used, which leads to a circular artifact because all spatial information depends on variation of frequency. In our machine, two-dimensional Fourier transformation is used for image reconstruction, in which spatial information depends on frequency in one direction and on phase in the other. Therefore, the artifact will appear only in the frequency-encoding direction. The knowledge of the typical appearance of this artifact is important because it facilitates interpretation and discrimination of a low-signal lesion

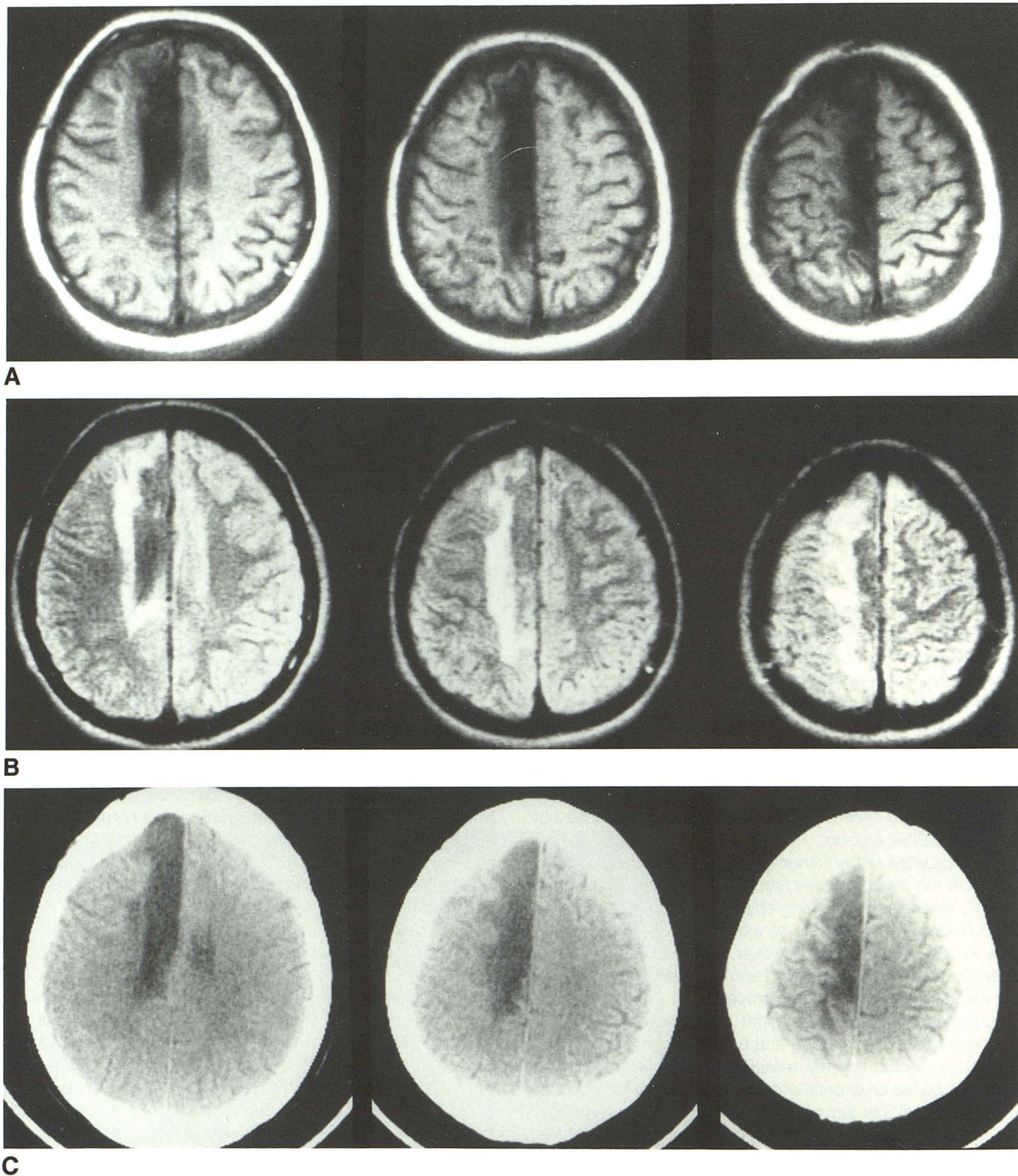


Fig. 4.—Pericallosal infarct on short TR/TE (A), long TR/TE (B), and CT (C) images.

from a metal artifact. The artifact is somewhat larger in the frequency direction, which means that a lesion close to the metal can be seen better if the frequency direction is chosen perpendicular to it. The artifact was somewhat larger when a

long TR/TE (2000/56) was used than when a short TR/TE (500/16) was used, which is explained by the weaker readout gradient used in our system when long TEs are used, leading to a larger spatial mismatching.

The diagnostic information of MR was superior to that of CT in the region adjacent to the aneurysm clip. Lesions in the region of surgery were seen in seven patients with MR, whereas CT only revealed six. Furthermore, temporal extension of the lesions was obscured by beam-hardening artifacts on CT in three patients. In one case a frontal lesion was revealed only on the long TR/TE examination. MR also was superior to CT in revealing lesions not related to the region of surgery, and in four patients small white-matter lesions were found that were not seen on CT. These lesions probably represented infarcts. In three patients small white-matter lesions were found on the side contralateral to the aneurysm. Small white-matter lesions are rather common findings on MR in elderly patients [7] and not necessarily associated with clinical symptoms. All patients in our study with such lesions were over 50 years old, and the lesions were probably not related to the subarachnoid hemorrhage, spasm, or surgery. However, the white-matter lesions seen on the side of the aneurysm were also seen in young patients and, therefore, probably were related to the hemorrhage or surgery. On the basis of the results of our study, we suggest that patients with nonferromagnetic aneurysm clips who need a morphologic evaluation of the brain first be examined by CT; if CT is inadequate then MR can be performed if it has been established that the clips are of the safe, nonferromagnetic type.

In conclusion, our study shows that patients with nonferromagnetic Yasargil and Sugita clips can be examined safely in a 0.3-T Fonar MR scanner. MR provides more information than CT does because of less disturbance of the image by metal artifacts and superior soft-tissue discrimination.

REFERENCES

1. Holland BA. Diseases of white matter. In: Brant-Zawadzki M, Norman D, eds. *Magnetic resonance imaging of the central nervous system*. New York: Raven, 1987:259-277
2. Kelly WM. Image artifacts and technical limitations. In: Brant-Zawadzki M, Norman D, eds. *Magnetic resonance imaging of the central nervous system*. New York: Raven, 1987:43-82
3. New PFJ, Rosen BR, Brady TJ, et al. Potential hazards and artifacts of ferromagnetic and nonferromagnetic surgical and dental materials and devices in nuclear magnetic resonance imaging. *Radiology* 1983;147:139-148
4. Dujovny M, Kossovsky N, Kossowsky R, et al. Aneurysm clip motion during magnetic resonance imaging: in vivo experimental study with metallurgical factor analysis. *Neurosurgery* 1985;17:543-548
5. Davis PL, Crooks L, Arakawa M, McRee R, Kaufman L, Margulis AR. Potential hazards in NMR imaging: heating effects of changing magnetic fields and RF fields on small metallic implants. *AJR* 1981;137:857-860
6. Fache JS, Price C, Hawbolt EB, Li DKB. MR imaging artifacts produced by dental materials. *AJNR* 1987;8:837-840
7. Brant-Zawadzki M, Fein G, Van Dyke C, Kiernan R, Davenport L, DeGroot J. MR imaging of the aging brain: patchy white-matter lesions and dementia. *AJNR* 1985;6:675-682