

Generic Contrast Agents

Our portfolio is growing to serve you better. Now you have a *choice*.



FRESENIUS
KABI

[VIEW CATALOG](#)

AJNR

Acute Carbon Monoxide Poisoning: Computed Tomography of the Brain

Kwang S. Kim, Peter E. Weinberg, Jung H. Suh and Sam U. Ho

AJNR Am J Neuroradiol 1980, 1 (5) 399-402

<http://www.ajnr.org/content/1/5/399>

This information is current as
of May 12, 2025.

Acute Carbon Monoxide Poisoning: Computed Tomography of the Brain

Kwang S. Kim¹
 Peter E. Weinberg¹
 Jung H. Suh²
 Sam U. Ho³

Ten computed tomography (CT) brain scans were evaluated in nine patients with acute carbon monoxide poisoning. The most common CT feature was symmetrical bilateral basal ganglia abnormalities. The lesions appeared as symmetrical low density areas, more dense than cerebrospinal fluid in the early stage and as well defined and more lucent lacunae in the late stage. A second feature was symmetrical and diffuse white matter low density areas. The low density areas, attributed to edema, were poorly defined and faintly lucent in the early stage. They became better defined and more lucent later as permanent necrotic changes developed. Ventricular dilatation and sulcal widening developed as late changes.

Carbon monoxide (CO) intoxication produces hypoxia by displacing oxygen from hemoglobin and impeding its release from hemoglobin in tissues [1]. The organ most affected is the brain. Victims who survive acute CO poisoning may have various neuropsychiatric symptoms and signs [2]. With the advent of computed tomography (CT), it has become possible to demonstrate the extent and distribution of the morphologic brain changes in surviving patients. CT can safely demonstrate the dynamic aspect of the structural changes, but reports to date describing the CT appearances of the brain in cases with acute CO poisoning are few. We discuss the CT features in nine patients with acute CO intoxication.

Subjects and Methods

The diagnosis of acute CO poisoning was made by overwhelming circumstantial evidence. Seven patients with acute CO poisoning admitted to Severance Medical Center, Seoul, Korea were exposed to domestic coal gas. Many Koreans have a unique home heating system in which smoke and heat from the coal stove goes through rock-lined channels under the floor of the house and out a chimney at the far end, furnishing a system of radiant heating. CO-containing gas can accidentally leak into the room through cracks in the floor, resulting in acute CO poisoning. The accidents usually occur during sleeping hours.

All the CT studies were made with an Ohio Nuclear Delta 50 scanner and included pre- and postinfusion contrast-enhanced scans. In five patients (cases 1–5), scans were done within 1 week after acute CO intoxication (early stage) and in two cases (cases 5 and 7), scans were obtained 2 months after the accidents (late stage). In one patient (case 6), the scan was obtained 6 weeks after the accident. One patient (case 5) had two scans, one in the early stage and the other in the late stage.

In two patients (cases 8 and 9) with acute CO poisoning due to fire-related smoke inhalation, scans were obtained at Northwestern Memorial Hospital, Chicago using an EMI 1005 scanner. The scans were performed without infusion of contrast material 3 months

Received March 1, 1980; accepted after revision April 24, 1980

¹ Department of Radiology, Northwestern University Medical School, and Northwestern Memorial Hospital, Superior St. and Fairbanks Ct., Chicago, IL 60611. Address reprint requests to K. S. Kim.

² Department of Radiology, Severance Medical Center, Yonsei University School of Medicine, Seoul, Korea.

³ Department of Neurology, Northwestern University Medical School, and Northwestern Memorial Hospital, Chicago, IL 60611.

AJNR 1:399–402, September/October 1980
 0195–6108/80/0104–0399 \$00.00
 © American Roentgen Ray Society

TABLE 1: CT Features in Acute Carbon Monoxide Poisoning

Case No.	Age, Gender	Time from Accident to CT	Neurologic Status	CT Features
Without and with contrast infusion:				
1	42, F	Same day	Coma	Bilateral basal ganglia low density areas
2	66, M	1 day	Coma	Bilateral basal ganglia low density areas
3	54, M	6 days	Coma	Bilateral basal ganglia low density areas
4	22, F	3 days	Coma	Bilateral basal ganglia low density areas
5	25, M	1 day	Coma	Bilateral white matter low density areas
		2 mos	Vegetative state	White matter low density areas sharply demarcated and lucent. Bilateral basal ganglia lacunae, ventricular dilatation and sulcal widening
6	37, M	6 wks	Coma for 6 hr; neurologically normal for 6 weeks; disoriented and confused	Bilateral basal ganglia lacunae and white matter low density areas
7	55, F	2 months	Vegetative state	Bilateral basal ganglia lacunae and white matter low density areas. Ventricular dilatation and sulcal widening
Without contrast infusion:				
8	12, F	3 months	Quadriparesis, severe dysarthria	Bilateral basal ganglia lacunae, ventricular dilatation and sulcal widening
9	32, F	3 months	Poor memory, mild quadriparesis	Bilateral basal ganglia lacunae

Note.—Cases 8 and 9 had fire-related smoke inhalation; all others inhaled domestic coal gas.

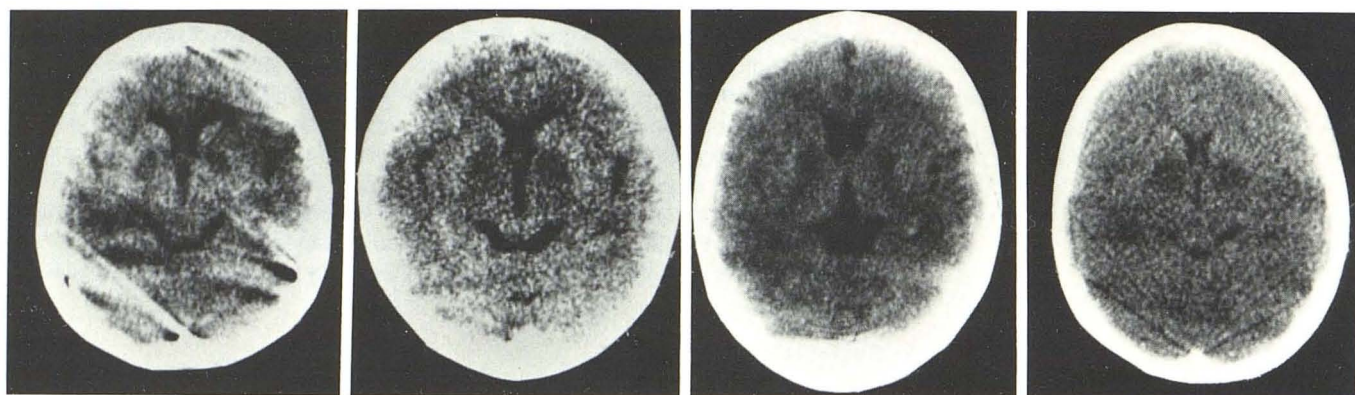


Fig. 1.—Cases 1–4, respectively. Noncontrast scans within 1 week after accidents. Bilateral symmetric low density areas in basal ganglia.

after the accidents. Only patients with positive CT scans are described.

Results

The most common CT feature of acute CO poisoning in our cases was symmetric bilateral basal ganglia abnormality (table 1). Four of five patients scanned within 1 week after the accidents (early phase) demonstrated symmetrical bilateral low density areas in the basal ganglia with a density greater than that of cerebrospinal fluid (fig. 1). This coincided with the edematous stage of infarction. All five patients

who had scans 6 weeks or more after the accidents (late phase) showed bilateral symmetrical lacunae in the basal ganglia. The lesions were well defined and more lucent with a density similar to that of cerebrospinal fluid (figs. 2C, 3, and 4). The CT findings were not dissimilar to those commonly observed in ischemic infarction secondary to arterial occlusion except that the lesions were bilateral in cases of acute CO poisoning.

The second conspicuous CT feature was the occurrence of diffuse white matter low density areas in three of nine cases. The low density areas were remarkable in their symmetrical distribution (figs. 2 and 3). In the early phase,

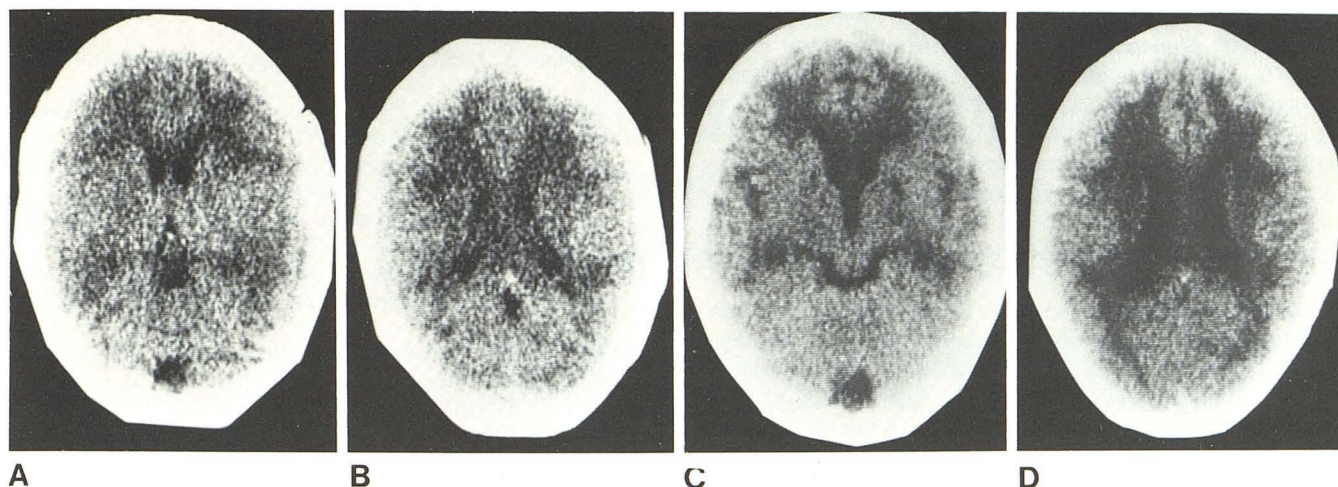


Fig. 2.—Case 5. Noncontrast scans. **A** and **B**, 1 day after accident. Bilateral symmetric low density areas in white matter. **C** and **D**, 2 months later. Low density areas in white matter are more sharply demarcated and

more lucent with density of cerebrospinal fluid. Bilateral basal ganglia lacunae, ventricular dilatation, and sulcal widening.

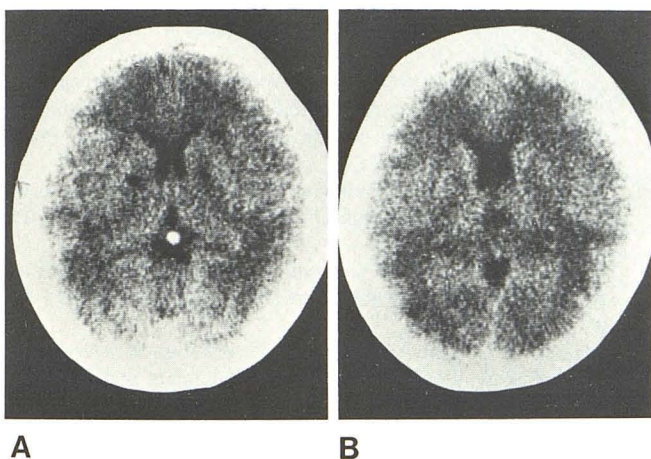


Fig. 3.—Case 6. Noncontrast scans 6 weeks after accident. Bilateral symmetrical low density areas in white matter and lacunae in basal ganglia.

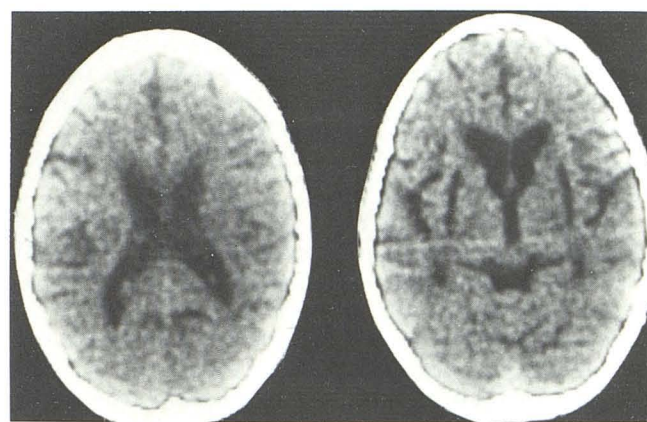


Fig. 4.—Case 8. Noncontrast scans 3 months after accident. Bilateral symmetrical lacunae in basal ganglia. Ventricular dilatation and sulcal widening relative to patient's age (12 years old).

the lesions appeared as poorly defined and faintly lucent areas in the periventricular white matter and were attributed to cerebral edema (figs. 2A and 2B). Kondo et al. [3] reviewed the CT studies of 11 cases with acute CO poisoning and observed various degrees of white matter edema in five cases, which cleared in 2 weeks in all five instances. CT studies were obtained within 2 weeks after the accidents, so delayed changes were not included.

In one patient (case 5) the white matter edema appeared 1 day after the exposure and evolved into well defined and more lucent lesions with a density equivalent to that of cerebrospinal fluid in 2 months (fig. 2). At this stage, the CT appearance was believed to represent permanent necrotic changes with cystic formation. In another case (case 7), similar changes were present in the CT scan obtained 2 months after the accident.

In one patient (case 6) CT was performed 6 weeks after the episode and showed diffuse white matter and bilateral basal ganglia involvement (fig. 3). The density of the white

matter lesions was less lucent than that of cerebrospinal fluid, and was considered to represent incomplete necrosis resulting in demyelination and gliosis. It appeared that white matter edema in the early stage might be reversible [3], but could progress to varying degrees of permanent necrotic changes.

The third feature was dilatation of the lateral ventricles and widening of the cortical sulci in three of nine cases (figs. 2 and 4). The ventricular dilatation and sulcal widening occurred together at the late stage. Two of the three cases were associated with diffuse white matter and basal ganglia involvement. The third case had only basal ganglia changes.

Discussion

Symmetric pallidal necrosis, formerly believed to be specific for acute CO poisoning, has been observed in many other conditions including barbiturate intoxication, trauma,

cyanide poisoning, hypoglycemia, and hydrogen sulfide poisoning [4-7]. The pathogenesis of lesions located in the arterial border zone is generally believed to be a secondary complication of systemic hypotension common to all of these conditions, not primary oxygen deficiency. Predilective involvement of the basal ganglia is not due to greater vulnerability of its neurons to hypoxia, but to the fact that the basal ganglia region is an end arterial zone that is hypoperfused secondary to systemic hypotension [4, 5, 7, 8].

The white matter lesions in acute CO poisoning have been well documented in autopsy specimens and experimental animals. The lesions are symmetrical and involve the periventricular centrum semiovale and the corpus callosum. The subcortical U-fibers are usually spared. Acidotic oligemic swelling develops in the acute stage and progresses to incomplete necrosis causing demyelination and gliosis or complete necrosis terminating in cystic lesions [4, 5, 8, 9]. Similar white matter changes have been observed in other conditions including anesthetic accidents, postoperative shock, hypoglycemia, and various drug intoxications [4, 5, 10]. The hemodynamic principle of the end arterial border zone of the basal ganglia is also applicable to the white matter [5, 8, 10]. The periventricular centrum semiovale is anatomically a hypoperfused region [11]. Also, the elevation of cerebral venous pressure secondary to right-sided heart failure plays an additive role in the pathogenesis of the lesions [5, 12].

The ventricular dilatation and sulcal widening indicated diffuse white and cortical gray matter atrophy. The cortical gray matter involvement, which had been well described in autopsy specimens [4, 5] was not observed in any of the CT scans obtained in the early stage. This was presumably due to the lesions being scattered, small, or isodense.

Nardizzi [13] reported areas of contrast enhancement in the basal ganglia and dentate nucleus bilaterally in a case when the CT scan was obtained on the eighth day after acute CO poisoning. There was no contrast enhancement in any of our cases. Contrast enhancement in infarction appears most often in lesions 1-4 weeks old [14], and CT scans in our study were obtained within the first week or after 6 weeks.

REFERENCES

1. Lillenthal JL. Carbon monoxide. *Pharmacol Rev* 1950;2:324-354
2. Garland, H, Pearce J. Neurological complications of carbon monoxide poisoning. *Q J Med* 1967;36:445-455
3. Kondo T, Ikeda T, Mogami H, Miura T, Mitomo M, Shimazaki S, Sugimoto T. Dynamic aspect of brain edema in cases of acute carbon monoxide poisoning. *No To Shinkei* 1978;30:525-531
4. Brierly JB. Cerebral hypoxia. In: Blackwood W, Crosell JAN, eds. *Greenfield's neuropathology*. London: Arnold, 1976:43-85
5. Lindenberg E. Systemic oxygen deficiencies. In: Minkler J, ed. *Pathology of nervous system*, vol II. New York: McGraw-Hill, 1971:1583-1617
6. Hicks SP. Brain metabolism in vivo. I. The distribution of lesions caused by cyanide poisoning, insulin hypoglycemia, asphyxia in nitrogen and fluoroacetate poisoning in rats. *Arch Pathol Lab Med* 1950;49:111-137
7. Fumisuke M, Cummins JW. Neurological sequelae of massive hydrogen sulfide inhalation. *Arch Neurol* 1979;36:451-452
8. Ginsberg MD, Myers RE, McDonagh BF. Experimental carbon monoxide encephalopathy in the primate. II. Clinical aspects, neuropathology and physiologic correlation. *Arch Neurol* 1974;30:209-216
9. Lapresle J, Fardeau M. The central nervous system and carbon monoxide poisoning. II. Anatomical study of brain lesions following intoxication with carbon monoxide (22 cases). *Prog Brain Res* 1967;24:31-75
10. Ginsberg MD, Hedley-Whyte ET, Richardson EP. Hypoxia-ischemic leukoencephalopathy in man. *Arch Neurol* 1976;33:5-14
11. DeRenck J. The human periventricular arterial blood supply and the anatomy of cerebral infarctions. *Eur Neurol* 1971;5:321-334
12. Preziosi TJ, Lindenberg R, Levy D, Christensen M. An experimental investigation in animals of the functional and morphologic effects of single and repeated exposure to high and low concentration of carbon monoxide. *Ann NY Acad Sci* 1970;174:369-384
13. Nardizzi LR. Computed tomographic correlate of carbon monoxide poisoning. *Arch Neurol* 1979;36:38-39
14. Wing SD, Norman D, Pollack JA, Newton TH. Contrast enhancement of cerebral infarcts in computed tomography. *Radiology* 1976;121:89-92