

Generic Contrast Agents

Our portfolio is growing to serve you better. Now you have a *choice*.



FRESENIUS
KABI

[VIEW CATALOG](#)

AJNR

High Cervical Carotid Artery Dissection: Spontaneous Resolution

R. G. Quisling, W. A. Friedman and A. L. Rhoton, Jr.

AJNR Am J Neuroradiol 1980, 1 (5) 463-468

<http://www.ajnr.org/content/1/5/463>

This information is current as
of May 13, 2025.

High Cervical Carotid Artery Dissection: Spontaneous Resolution

R. G. Quisling¹
W. A. Friedman²
A. L. Rhoton, Jr.²

The radiologic hallmark of intramural dissection of the high cervical internal carotid artery is asymmetric stenosis of the vessel lumen. The region of stenosis is generally centered at the C1-C2 level of the cervical spine, although the length of involvement may be considerably longer. Spontaneous dissection occurs unilaterally and is usually unrelated to atherosclerotic changes in the involved vessel. When the patient survives the initial event and its accompanying neurologic deficit, this diagnosis can be determined angiographically. This form of carotid artery dissection, occurring without pseudoaneurysm formation, generally resolves with conservative management.

High cervical carotidopathy resulting in significant luminal stenosis poses a difficult clinical problem, both in accurate diagnosis and treatment. The most common of such carotidopathies include atherosclerosis, fibromuscular dysplasia, and direct trauma [1-4]. Spontaneous mural hemorrhage has also been reported as a cause of luminal stenosis and pseudoaneurysm formation [15-26]. Angiographic opacification of either a false lumen or pseudoaneurysm requires disruption of the intima. However, when intimal integrity is preserved or only minimally affected, carotid stenosis in the absence of aneurysm results. In our experience, such patients are often considered for superficial temporal to middle cerebral artery bypass for an apparently isolated high cervical carotid stenosis, usually misconstrued as either fibromuscular dysplasia or atherosclerosis.

Our series of seven cases was selected from a larger collection of patients with spontaneous high cervical carotid dissections. Analysis of our data and literature review suggest that there is a significant difference in clinical course and outcome between patients who demonstrate either bilateral dissections or pseudoaneurysms and those whose mural hemorrhage results in unilateral carotid artery stenoses [27-31]. The cases analyzed in the series are restricted to those patients who had unilateral extraluminal stenosis of the high cervical carotid artery as the result of an apparent subintimal hemorrhage. The diagnosis of high cervical carotid dissecting hematoma was based on both the initial angiographic appearance and evidence of spontaneous resolution on subsequent angiographic evaluation. The radiologic features characterizing both the initial and resolution phases of this process are described.

Received November 16, 1979; accepted after revision March 7, 1980.

Presented at the annual meeting of the Southeastern Neuroradiology Society, New Orleans, October 1979.

¹Department of Radiology, Neuroradiology Section, Shands Teaching Hospital, Box J 374, J. Hillis Miller Health Center, University of Florida College of Medicine, Gainesville, FL 32610. Address reprint requests to R. G. Quisling.

²Department of Surgery, Neurosurgery Section, University of Florida College of Medicine, Gainesville, FL 32610.

AJNR 1:463-468, September/October 1980
0195-6108/80/0104-0463 \$00.00
© American Roentgen Ray Society

TABLE 1: Angiographic Features of Cervical Carotid Artery Dissection

Type of Initial Stenosis/Case No.	Age (yrs), Gender	Symptoms	Vessels Examined			Radiologic Course
			ICA	BCA	V	
Asymmetric						
1	34, M	TIA	Yes	No	No	Resolved by 3 months
2	59, F	TIA	No	Yes	No	Resolved by 3 months
5	52, F	TIA, Horner	No	Yes	Yes	Resolved by 3 months
6	42, M	TIA, HA	No	Yes	Yes	No improvement at 1 month; ca- rotid ligation
Irregular and accentuated tortuosity:						
3	45, F	Amaurosis fugax (HA)	No	Yes	Yes	Resolved by 2 months
7	46, M	TIA, HA	No	Yes	No	Resolved by 3 months
Tapered:						
4	46, F	Diplopia, HA	No	Yes	No	Resolved by 2 months

Note.—ICA = unilateral carotid artery; BCA = bilateral carotid artery; V = vertebral artery; TIA = transient ischemic attack; HA = headache.

Materials and Methods

Initial angiographic evaluation on all but one patient was performed at other institutions. These procedures include unilateral angiograms in one patient and bilateral angiograms in six patients performed either via a transfemoral approach or in most instances percutaneous common carotid punctures. In the latter circumstance, there was no evidence that the common carotid puncture contributed to the high cervical stenotic lesions. Follow-up angiography in each instance used transfemoral catheterization techniques and selective filming of both carotid circulations. Vertebral angiography, available in three of the seven cases, was normal in each instance.

Since our paper intends to elucidate the radiographic features of high cervical carotid dissection, the clinical course and mode of therapy are not considered in depth. As in other reports [32], our patients had cerebral ischemic episodes, headache, amaurosis fugax, diplopia, Horner syndrome, or a combination of these symptoms. They were 34–59 years old, and displayed a statistically insignificant gender distribution (table 1).

Results

The diagnosis of subintimal or intramural hemorrhage in the cervical and/or proximal intrapetrous carotid artery was made tenable because of the resolution of the stenotic lesions. Previous reports have stated that most other types of carotidopathy, with the exception of inflammatory vasculitis, do not resolve spontaneously [33]. None of the patients in this group displayed clinical signs of either focal or systemic vasculitis. A single case had stenosis of an iliac artery suggestive of fibromuscular hyperplasia. Subintimal hemorrhage has been reported beneath atheromatous plaques [34]. However, no patients in our series demonstrated atherosclerosis, either in the area of immediate interest, or generally throughout either carotid distribution. The radiologic features of high cervical carotid artery dissection are illustrated in the initial and resolving phases.

Initial Phase

Intramural dissection of the extracranial internal carotid artery was a unilateral process. This statement is based on

both the initial angiogram (when both carotid circulations were examined) and on the lack of contralateral intimal abnormalities on follow-up examinations. This will become apparent after the discussion of the radiologic features characterizing the resolving phase of this process. The extent of the lesion, although variable, tended to involve fairly long segments of the vessel wall, ranging between the carotid sinus and the proximal (or vertical) segment of the intrapetrous carotid canal. Although intimal irregularity and mild stenosis were visible over a longer region, the area of maximum stenosis generally involved a smaller region usually 2–3 cm long, centered over the C1–C2 level of the cervical spine (fig. 1A).

The region of maximal luminal stenosis was of variable appearance. The most common form was an asymmetric extraluminal impression (fig. 2A). Its margins remained sharply defined and the degree of narrowing varied over the course of the stenosis. Some patients exhibited a circumferential stenosis (figs. 3A and 4A). This form of dissection created an impression of vessel tortuosity that disappeared on follow-up examinations (fig. 4B), and therefore was considered part of the initial disease process. Other luminal irregularity, which would suggest atherosclerotic intimal change, was not apparent, either in the area of immediate interest or more proximally in the carotid sinus or common carotid bifurcation (table 1).

None of the patients exhibited a disruption of the intimal surface or creation of a false lumen. Cases demonstrating a false channel or pseudoaneurysm were excluded from this report, although they are generally considered part of the spectrum of spontaneous intramural dissection hemorrhage [20–23].

Resolution Phase

Six of the cases with apparent mural or subintimal dissecting hemorrhages underwent nearly complete resolution of the stenosis. The other case remained stable clinically but demonstrated no resolution of the stenosis on a follow-up carotid angiogram 1 month before initial angiography. This patient was then treated surgically with carotid ligation.

Fig. 1.—Case 1, 34-year-old man with transient ischemic episodes. Anteroposterior views, left common carotid angiograms. **A**, High cervical stenosis asymmetrically positioned along vessel margin with maximal stenosis (*arrow*) immediately proximal to vertical part of intrapetrous carotid canal (*ip*). Distal margin of intramural dissecting hematoma is at acute angle with uninvolved distal carotid artery lumen. **B**, After 3 months of conservative management on anticoagulants. Nearly complete resolution of stenotic lesion. Only residual angiographic abnormality is wedgelike intimal defect (*arrow*), apparently corresponding to junction between distal margin of dissection and normal arterial wall.

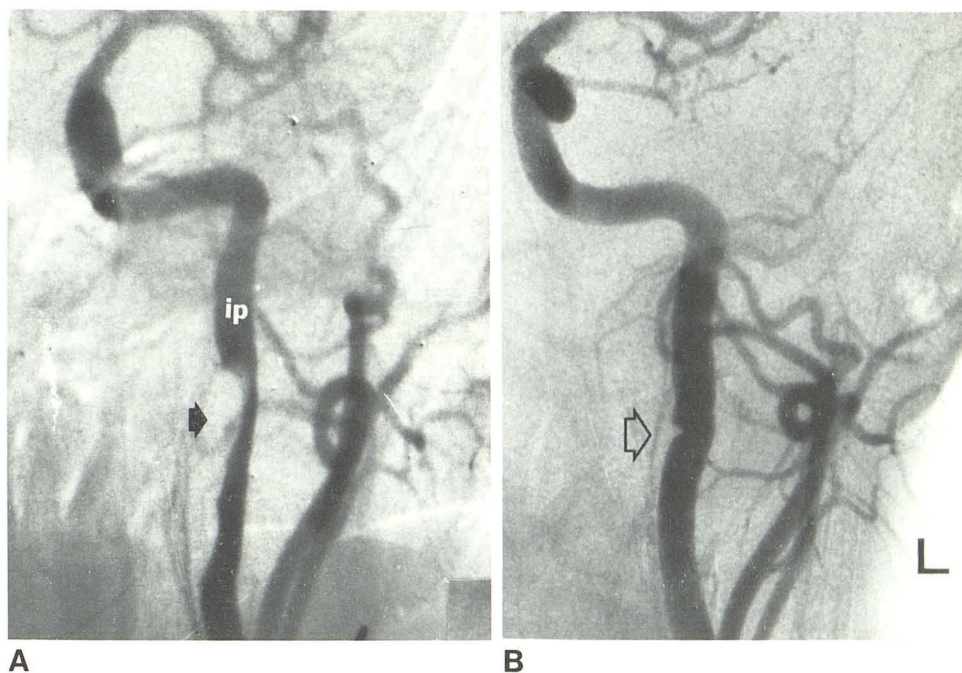
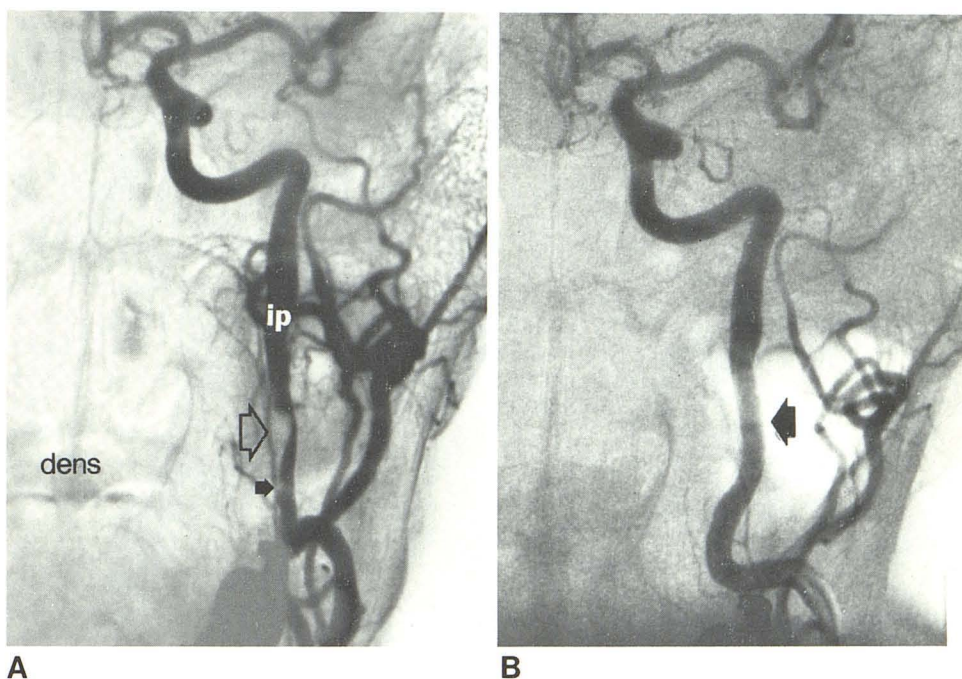


Fig. 2.—Case 2, 59-year-old woman with left hemispheric transient ischemic episodes. Anteroposterior views, left common carotid angiograms. **A**, Long-segment luminal stenosis of high cervical internal carotid artery. Region of maximal stenosis (*open arrow*) corresponds to level of odontoid process (*dens*). Wedgelike luminal defect (*solid arrow*) near proximal margin of subintimal dissecting hematoma. Distal extent of lesion extends to intrapetrous part (*ip*) of carotid artery. **B**, After 3 months of conservative management on anticoagulants. Nearly complete resolution of subintimal dissection. Diffuse mild narrowing (*arrow*) of internal carotid artery lumen throughout region of involvement.



In those cases that demonstrated nearly complete resolution on serial angiograms, subtle residual vessel wall changes remained evident. The actual lumen size throughout the area of involvement remained slightly smaller on follow-up angiography when compared with uninvolved proximal and distal segments of the same vessel (fig. 1B). Another common finding was evidence of small wedgelike luminal defects, presumably reflecting focal subintimal fibrosis at a margin of the hemorrhage (figs. 2B and 3B).

Discussion

Stenosis of the upper cervical carotid artery may result from many pathologic processes. Such carotidopathies, particularly atherosclerosis and fibromuscular dysplasia, usually involve more than one vessel, and generally progress with time [2, 30].

High cervical carotid dissections may result from direct trauma [1, 6, 10] or occur spontaneously [16–18, 20] (as in

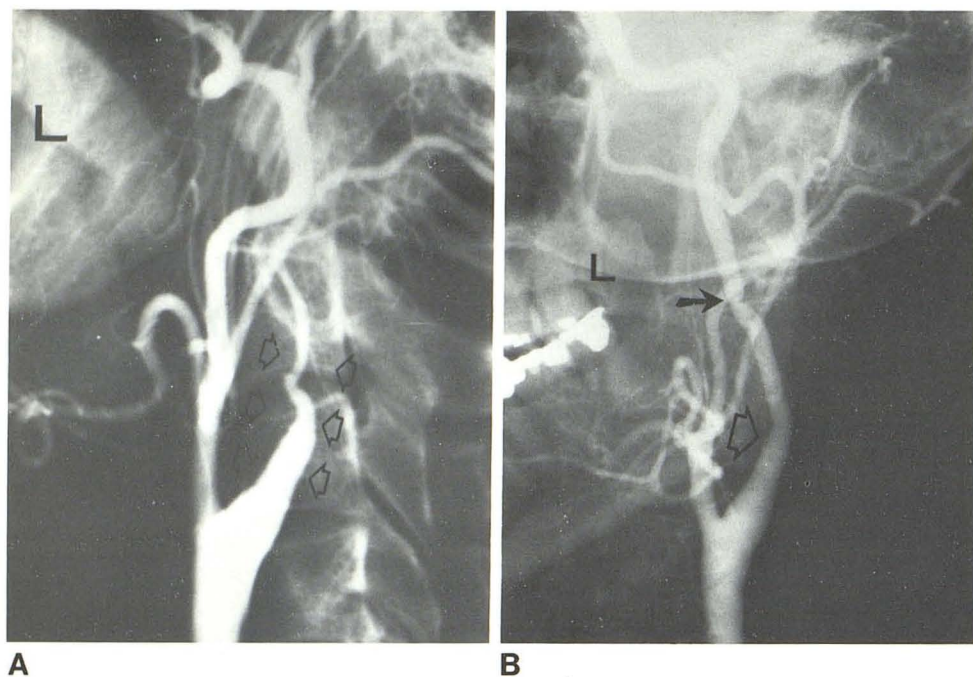


Fig. 3.—Case 3, 46-year-old woman with left-sided amaurosis fugax. Left common carotid angiograms. **A**, Lateral view. Tapered high-grade stenosis of internal carotid artery (arrows). Maximal stenosis was immediately distal to carotid sinus region. Proximal vessel lumen has no atheromatous plaque disease and distal cervical and intrapetrous carotid lumen appeared normal on serial radiographs. **B**, Oblique, anteroposterior view 2 months later. Nearly complete resolution. Normal area of maximal stenosis (open arrow). Persistent wedgelike defect (solid arrow) remains, presumably demarcating junction between intramural dissecting hemorrhage and normal vessel wall.

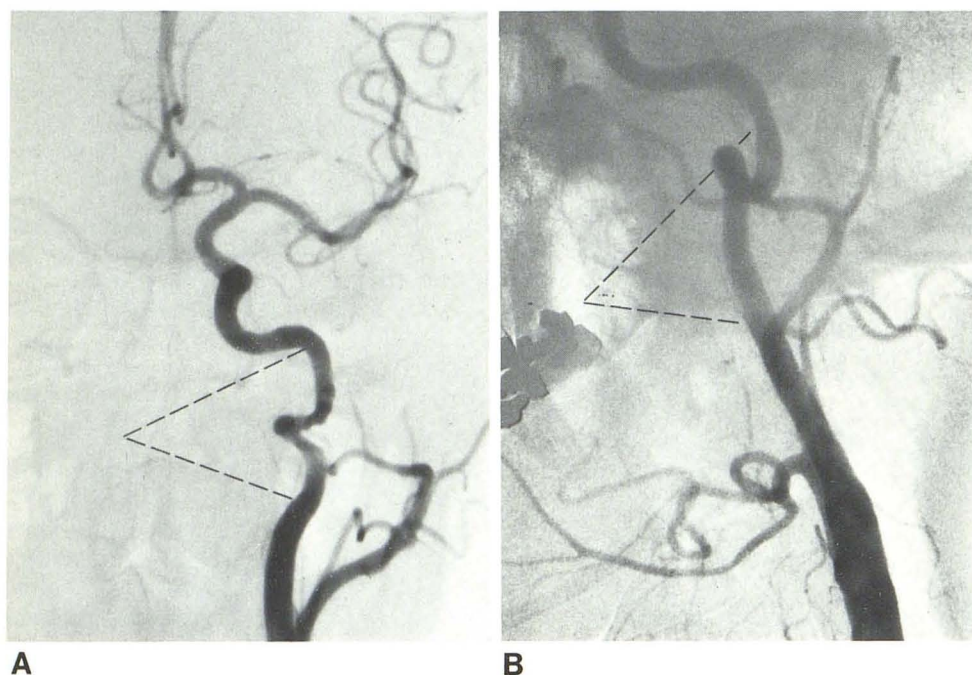


Fig. 4.—Case 4, 46-year-old woman with acute-onset left-sided headache and transient ischemic episode. Left common carotid angiograms. **A**, Anteroposterior view. Area of luminal stenosis affects high cervical and vertical part of internal carotid artery (dashed lines). Circumferential stenosis not associated with intimal fracture or pseudoaneurysm. Vessel otherwise normal both proximally and distally. **B**, Oblique, anteroposterior view after 3 months of conservative management. Complete resolution (dashed lines). Serpiginous appearance of involved segment of vessel has resolved except for single anatomic bend proximal to intrapetrous carotid canal.

our cases). In the latter circumstance an inapparent traumatic episode is also suspected as the initial event [31, 35, 36]. Similar cases, presented in the literature with pathologic correlation, have demonstrated a hematoma in a medial or subadventitial position [23]. These were associated with intimal disruption in some but not all cases [25]. When an intimal tear occurred and carotid angiography demonstrated stenosis without pseudoaneurysm, the false channel was obliterated by the clotted hematoma.

Although no pathology is available in our series, the spontaneous resolution and absence of apparent intimal disruption are indicative of a less severe injury, in which the overall integrity of the vessel wall is preserved. The pathologic mechanism in these cases is believed to be medial or subintimal hemorrhage into the vessel wall [37–39]. This may or may not be associated with an intimal rent. However, clear evidence of an intimal flap was not defined angiographically in this series.

While underlying pathology, such as cystic medial necrosis or congenital mural defect, has been reported [11, 20, 25, 27], other authors describe instances of spontaneous dissection in otherwise normal carotid arteries [16, 23]. The unilateral occurrence, the lack of laboratory or clinical evidence of systemic vasculitis, and the benign course in all but one case in our series suggest that cystic medial necrosis or diffuse arteritis was not a major predisposing factor in this form of carotid dissection. Focal parainflammatory vasculitis and direct trauma may resemble spontaneous dissection radiographically. However, the absence of either a traumatic episode or evidence of a retropharyngeal inflammatory focus precludes these entities.

The angiographic diagnosis of hemorrhagic dissection is difficult without a false lumen or pseudoaneurysm. Fibromuscular hyperplasia of the adventitial type also results in long segment stenotic lesions of the high cervical extracranial carotid artery. However, such lesions are frequently bilateral and may also affect the vertebral arteries. The involved vessel segments are uniformly affected with a circumferential narrowing of the vessel lumina. Fibromuscular hyperplasia does not usually resolve over time.

Spontaneous carotid dissection typically involves only one vessel in an asymmetric fashion, even when the vessel is involved circumferentially. The length of vessel wall involvement is generally longer than with either fibromuscular hyperplasia or atherosclerosis. Both the proximal and distal parts of the vessel are of normal size, which excludes the possibility of a developmental narrowing or carotid hypoplasia [40].

Atherosclerosis may cause focal high cervical carotid stenosis. However, the absence of common carotid bifurcation or carotid siphon involvement makes this an unlikely etiology. Most important for both diagnostic confirmation and therapeutic purposes is the nearly complete resolution of carotid dissections in 2–3 months. This never occurs with atherosclerosis. Subtle residual changes are present in most cases, which confirm the presence of a unilateral, healed, or healing lesion.

Historically, treatment for most high cervical carotidopathies has tended to be either conservative management or superficial temporal to middle cerebral artery bypass [41]. Treatment of suspected dissecting aneurysms has been surgical ligation, fenestration, or direct bypass of the internal carotid artery [18, 28, 42–44]. However, it is clear that an undefined proportion of high cervical carotidopathies, certainly larger than previously believed, are related to either inflammation or hemorrhage in the vessel wall [18, 23]. The absence of any focal or systemic inflammatory process makes the diagnosis of intramural hemorrhagic dissection the best etiologic possibility in our series. The spontaneous resolution of the stenotic segment over time was typical of all but one case.

The treatment protocol for suspected high cervical carotid dissections at our institution is now maintenance on anticoagulation to avoid embolic complications and follow-up angiography after a 2–3 month interval. Justification for the serial angiogram is based on the need to confirm the diagnosis and to preclude any additional therapy if there has

been nearly complete resolution of this form of carotidopathy.

To conclude, subintimal or medial dissecting hemorrhages result in inward displacement of the intima. When present in the high cervical region, this process results in a long-segment stenosis. If the intimal margins are preserved, no false lumen or pseudoaneurysm results. Spontaneous carotid dissection without pseudoaneurysm formation is a reversible process with most cases demonstrating nearly complete resolution on serial angiograms. The radiographic features in the initial and resolution phases are sufficiently characteristic to entertain the diagnosis prospectively, and obviate the need for immediate direct surgical intervention.

REFERENCES

1. Batzdorf U, Benson JR, Machleder HI. Blunt trauma to the high cervical carotid artery. *Neurosurgery* 1979;5:195–201
2. Bauer RB, Boulous RS, Meyer JS. Natural history and surgical treatment of occlusive cerebrovascular disease evaluated by serial arteriography. *AJR* 1968;104:1–17
3. Beatty RA. Dissecting hematoma of the internal carotid artery following chiropractic cervical manipulation. *J Trauma* 1977;17:248–249
4. Fleming JFR, Park AM. Dissecting aneurysms of the carotid artery following arteriography. *Neurology (Minneapolis)* 1959;9:1–6
5. Galligioni R, Iraci G, Marin G. Fibromuscular hyperplasia of the extracranial internal carotid artery. *J Neurosurg* 1971;34:647–650
6. Gonzalez A. Common carotid artery stenosis due to subintimal hematoma following blunt trauma to the neck. Report of a case. *J Cardiovasc Surg (Torino)* 1977;18:297–301
7. Gurdjian ES, Hardy WG, Lindner DW, Thomas LM. Closed cervical trauma associated with involvement of carotid and vertebral arteries. *J Neurosurg* 1963;20:418–427
8. Lai MD, Hoffman HD, Adamkiewicz JF. Dissecting aneurysm of internal carotid artery after nonpenetrating neck injury. *Acta Radiol [Diagn] (Stockh)* 1966;5:290–295
9. Lerner MA, Braham J. High cervical carotidopathies. *Clin Radiol* 1971;22:296–301
10. Ludwiczak RW, Fogel LM. Posttraumatic aneurysm of the cervical segment of the internal carotid artery. *Neuroradiology* 1975;10:179–182
11. Spudis EV, Scharyj M, Alexander E, Martin JF. Dissecting aneurysms in the neck and hand. *Neurology (Minneapolis)* 1962;12:867–875
12. Teal JS, Bergeron T, Rumbaugh CL, Segall HD. Aneurysms of the cervical portion of the internal carotid artery associated with nonpenetrating neck trauma. *Radiology* 1972;105:353–358
13. Webb RC Jr, Baker WF. Aneurysms of the extracranial internal carotid artery. *Arch Surg* 1969;99:501–505
14. Wylie EJ, Ehrenfeld WH. Extracranial occlusive cerebrovascular disease. Philadelphia: Saunders, 1970
15. Bostrom K, Liliequist B. Primary dissecting aneurysm of the extracranial part of the internal carotid and vertebral arteries. A report of three cases. *Neurology (Minneapolis)* 1967;17:179–186
16. Brice JG, Crompton MR. Spontaneous dissecting aneurysms of the cervical internal carotid artery. *Br Med J* 1964;2:790–796
17. Brown OL, Armitage JL. Spontaneous dissecting aneurysms of

- the cervical internal carotid artery. Two case reports and a survey of the literature. *AJR* **1973**;118:648-653
18. Ehrenfeld WK, Wylie EJ. Spontaneous dissection of the internal carotid artery. *Arch Surg* **1976**;111:1294
 19. Finney LA, David NJ. Aneurysm of the extracranial internal carotid artery. Report of a case and discussion. *Neurology* (Minneapolis) **1964**;14:376-379
 20. Liliequist B. The roentgenologic appearance of spontaneous dissecting aneurysm of the cervical internal carotid artery. Report of a case. *Vasc Surg* **1968**;2:223-226
 21. Margolis MT, Stein RC, Newton TH. Extracranial aneurysms of the internal carotid artery. *Neuroradiology* **1972**;4:78-81
 22. Roome NJ, Aderfeld DC. Spontaneous dissecting aneurysm of the internal carotid artery. *Arch Neurol* **1977**;34:251
 23. Ojemann RG, Fisher CM, Rich JC. Spontaneous dissecting aneurysm of the internal carotid artery. *Stroke* **1972**;3:434-440
 24. Shipley AM, Winslow N, Walker WW. Aneurysm in the cervical portion of the internal carotid artery. An analytical study of the cases recorded in the literature between August 1, 1925, and July 31, 1936. Report of two new cases. *Ann Surg* **1937**;105:673-699
 25. Thapedi IM, Ashenhurst EW, Rozdilsky B. Spontaneous dissecting aneurysm of the internal carotid artery in the neck. *Arch Neurol* **1970**;23:549-554
 26. Zakrzewski A. Spontaneous extracranial aneurysms of the internal carotid artery. *J Laryngol Otol* **1963**;77:342-350
 27. Lloyd J, Bahnson HT. Bilateral dissecting aneurysms of the internal carotid arteries. *Am J Surg* **1971**;122:549-551
 28. Mokri P, Houser OW, Sundt TM. Idiopathic regressing arteriopathy. *Ann Neurol* **1977**;2:466-472
 29. Mokri B, Sundt TM, Houser OW. Spontaneous internal carotid dissection, hemicrania and Horner's syndrome. *Arch Neurol* **1979**;36:677-680
 30. Northcroft B, Morgan AD. A fatal case of traumatic thrombosis of the internal carotid artery. *Br J Surg* **1944**;32:105-107
 31. Sullivan HG, Vines RS, Becker DP. Sequelae of indirect internal carotid injury. *Radiology* **1973**;109:91-98
 32. Fisher CM, Ojemann RG, Roberson GH. Spontaneous dissection of cervico-cerebral arteries. *Can J Neurol Sci* **1978**;5:9-19
 33. Tomono Y, Shirai S, Maki Y. Aneurysms of the upper cervical portion of the internal carotid artery due to exogenous focal arteritis. *Neuroradiology* **1975**;10:55-58
 34. Edwards JH, Kricheff II, Gorstein F, Riles T, Imparato A. Atherosclerotic subintimal hematoma of the carotid artery. *Radiology* **1979**;133:123-129
 35. Boldrey E, Maass L, Miller E. The role of atlantoid compression in the etiology of internal carotid thrombosis. *J Neurosurg* **1956**;13:127-139
 36. New PFJ, Momose KJ. Traumatic dissection of the internal carotid artery at the atlantoaxial level, secondary to nonpenetrating injury. *Radiology* **1969**;93:41-49
 37. Gore I. Pathogenesis of dissecting aneurysm of the aorta. *Arch Pathol Lab Med* **1952**;53:121-142
 38. Guthrie W, Maclean H. Dissecting aneurysms of arteries other than the aorta. *J Pathol* **1972**;108:219-235
 39. Watson AJ. Dissecting aneurysm of arteries other than the aorta. *J Pathol* **1956**;72:439-449
 40. Lie TA. *Congenital anomalies of the carotid arteries*. Amsterdam: Excerpta Medica, **1967**:95-105
 41. Hardin CA, Snodgrass RG. Dissecting aneurysms of the internal carotid artery treated by fenestration and graft. *Surgery* **1964**;55:207-209
 42. Raphael HA, Bernatz PD, Spittell JA Jr, Ellis FH Jr. Cervical internal carotid aneurysms: treatment by excision and restoration of arterial continuity. *Am J Surg* **1963**;105:771-778
 43. McNeil DH Jr, Driesbach J, Marsden RJ. Spontaneous dissection of the internal carotid artery. *Arch Neurol* **1980**;37:54-55
 44. Burklund CW. Spontaneous dissecting aneurysm of the cervical carotid artery: a report of surgical treatment in two patients. *Johns Hopkins Med J* **1970**;126:154-159