



Providing Choice & Value

Generic CT and MRI Contrast Agents



FRESENIUS
KABI

CONTACT REP

AJNR

Dissolution of isobutyl 2-cyanoacrylate on long-term follow-up.

V R Rao, K R Mandalam, A K Gupta, S Kumar and S Joseph

AJNR Am J Neuroradiol 1989, 10 (1) 135-141

<http://www.ajnr.org/content/10/1/135>

This information is current as
of July 31, 2025.

Dissolution of Isobutyl 2-Cyanoacrylate on Long-Term Follow-up

V. R. K. Rao¹
K. Ravi Mandalam
A. K. Gupta
Sunil Kumar
Santhosh Joseph

Eight patients with arteriovenous malformations (AVMs) in the basal ganglionic and deep parietooccipital regions and one patient with an AVM in the shoulder region showed resorption of the isobutyl 2-cyanoacrylate cast and recanalization of the arteries after delayed follow-up angiography. All the AVMs were large, had multiple arterial pedicles, and revealed significant obliteration of the AVM immediately after embolotherapy. Although a 50–75% obliteration was achieved immediately after embolization, follow-up angiography 6–20 months later revealed almost the original status. The residual bucrylate cast was disproportionately small compared with the recanalized malformation in seven patients, while in two patients there was no evidence of bucrylate on plain films. Degradation of bucrylate probably is due to the lysosomal activity of the endothelial cells.

The results from our nine patients with some degree of resorption of isobutyl 2-cyanoacrylate and six with recanalized AVMs 6–20 months after embolization suggest that operable AVMs should be excised soon after embolotherapy and inoperable AVMs should be embolized as completely as possible.

In recent years isobutyl 2-cyanoacrylate (IBCA) has been widely used for super-selective embolization procedures. Little detail has been documented regarding the quantity, proportions of iophendylate or tantalum, and rate of delivery. Long-term angiographic follow-ups reported by Vinuela et al. [1] and Vinters et al. [2] have indicated progressive thrombosis in partially embolized arteriovenous malformations (AVMs) of large size. Concomitant formation of dural, pial, and medullary collaterals was also observed.

Our series of 17 patients with large and deep AVMs treated by variable composition and quantities of IBCA and iophendylate includes nine patients in whom partial and even complete resorption of IBCA was observed after an interval of 6–20 months.

Materials and Methods

Seventeen patients 12–46 years old had transcatheter superselective endovascular occlusive therapy with IBCA. Twelve had intracranial AVMs with or without dural vascular contributions. Two patients had large cirroid aneurysms of the scalp and another had an extensive paraspinal hamartomatous lesion. AVMs of the shoulder region and foot were also treated in one patient each (Table 1).

Through a nontapered 7-French polyethylene catheter in the appropriate brachiocephalic vessels, a 2.5-French Silastic microcatheter with a calibrated-leak balloon was propelled selectively into the feeding artery by means of a propulsion chamber. IBCA was mixed with iophendylate at an approximate ratio of 1:2 in 16 patients and at a ratio of 1:1 in one patient because of rapid flow (case 11). Tantalum, 1 g, was also mixed in the solution just before injection to enhance radiopacity. Because the majority of our patients were inoperable, long-term follow-up was performed radiographically and angiographically in nine patients for a period of 6–20 months.

Received November 18, 1987; accepted after revision April 18, 1988.

¹ All authors: Department of Radiology, Sree Chitra Tirunal Institute for Medical Sciences and Technology, Trivandrum 695011, India. Address reprint requests to V. R. K. Rao.

AJNR 10:135–141, January/February 1989
0195–6108/89/1001–0135
© American Society of Neuroradiology

TABLE 1: Angiography, Embolization, and Follow-up of Treated Arteriovenous Malformations (AVMs)

Embolization Mixture: Case No.	Age	Gender	Location of AVM	Feeding Arteries	Months Between Embolization and Follow-up Angiogram	Approximate Decrease of IBCA Cast (%)	Degree of Recanalization
0.5 ml IBCA and 1.0 ml iophendylate:							
1	32	F	R parietooccipital	Post. parietal & calcarine	15	75	Significant
2	30	F	Pineal	Post. cerebral	NF	—	—
3	24	M	R cerebellum	PICA, AICA, & occipital	14	10	Minimal
4	22	F	L cerebellum	PICA, sup. cerebellar, & AICA	12	25	NP
5	17	M	L basal ganglia	Ant. choroidal, lenticulostriate, & perforating	6	80	NP
6	14	M	L basal ganglia	Thalamoperforating & striate	6	90	Significant
7	12	F	R motor cortex	Central sulcus	8	10	Moderate
8	44	M	L basal ganglia	Post. choroidal, perforating, & striate	NF	—	—
9	17	M	R parietal	Post. parietal & occipital	NF	—	—
10	23	M	R temporal	Ant. temporal & middle meningeal	NF	—	—
0.5 ml IBCA and 0.5 ml iophendylate:							
11	20	M	R cerebellum	AICA, PICA, & occipital	NF	—	—
0.5 ml IBCA and 1.2 ml iophendylate:							
12	22	M	R temporal	Ant. choroidal & middle meningeal	NF	—	—
13	26	M	Cirroid aneurysm, scalp	Both sup. temporal, middle meningeal, & occipital	20	100	Complete
14	46	M	Cirroid aneurysm, scalp	Post. auricular & occipital	NF	—	—
15	23	M	Paraspinal	Multiple intercostal	15	10	NP
16	36	M	R shoulder	Humeral circumflex, acromioclavicular, & subscapular	12	100	Moderate
17	26	F	L foot	Dorsalis pedis and post. tibial	NF	—	—

Note.—IBCA = isobutyl 2-cyanoacrylate; R = right; L = left; Post. = posterior; Sup. = superior; Ant. = anterior; NF = no follow-up; NP = angiography not performed; PICA = posterior inferior cerebellar artery; AICA = anterior inferior cerebellar artery.

Results

The IBCA mixture reached satisfactorily into the nidus of all the arteries injected. There was no spill of IBCA into the venous circulation. However, there was reflux of IBCA into the normal cortical arteries in two patients (cases 2 and 6) without significant untoward effects. The size of the bucrylate cast decreased from 10% to 90% in seven patients, and completely disappeared in two patients. Delayed postembolization angiography revealed moderate to complete reconstitution of the AVMs. In addition to the reduction in the volume of the cast, the IBCA-opacified feeding arteries showed an actual shrinkage, as evidenced by the change in the configuration of the arterial loops and bends (case 1).

Representative Case Reports

Case 1

A 32-year-old woman was admitted for a seizure disorder. CT and angiography, performed after subarachnoid hemorrhage 3 years before, revealed a large AVM in the right parietooccipital lobe fed by the posterior parietal branch of the middle cerebral artery as well as by the calcarine branch of the posterior cerebral artery (Fig. 1). Under neuroleptic analgesia, transfemoral embolization was performed with IBCA. Through an 8-French check-flow sidearm arterial sheath, the right internal carotid artery was catheterized by a 7-French nontapered polyethylene catheter. A 2.5-French Silastic microcatheter with a No. 19 balloon with a calibrated leak at its tip was propelled into the posterior parietal branch of the middle cerebral artery. Preembolization angiography through the microcatheter measured an arterio-

venous transit time of 1 sec. Embolization was carried out with 0.6 ml of a mixture of 1 g of tantalum powder, 0.5 ml of IBCA, and 1.0 ml of iophendylate. An immediate postembolization angiogram revealed obliteration of 50% of the nidus and significant reduction in flow. A week later via the femoral approach the right posterior cerebral artery was catheterized from the left vertebral artery, and the calcarine branch was embolized with a 0.5-ml mixture of the IBCA, iophendylate, and tantalum powder. Immediate postembolization angiography of both left vertebral and right internal carotid arteries showed about 75% occlusion of the nidus and reduction in flow (Figs. 1C and 1D). The bulk of the IBCA deposit was in the nidus, with very little in the arterial trunk (Fig. 1E).

Plain films after 15 months showed about a 75% decrease in the IBCA cast (Fig. 1F). In particular, two sites on the feeding arterial loops and bends revealed striking shrinkage, resulting in shortening and closure of the curves of the artery. Repeat angiography showed recanalization of a major feeding artery and reconstitution of the AVM to its original dimensions (Figs. 1G and 1H). However, blood flow was markedly reduced, and attempts to propel the microcatheter into the feeding arteries through the carotid and vertebral arteries failed. Subsequently, the AVM was completely excised.

Case 6

A 14-year-old boy investigated for progressive right hemiparesis and one episode of subarachnoid hemorrhage was found to have a left thalamic AVM supplied by a large thalamoperforating artery and several posterior choroidal arteries (Fig. 2). Many striate arteries from the left middle cerebral artery were also contributing. From the vertebral artery the hypertrophied single thalamoperforating artery was catheterized by a 2.5-French microcatheter, and embolization

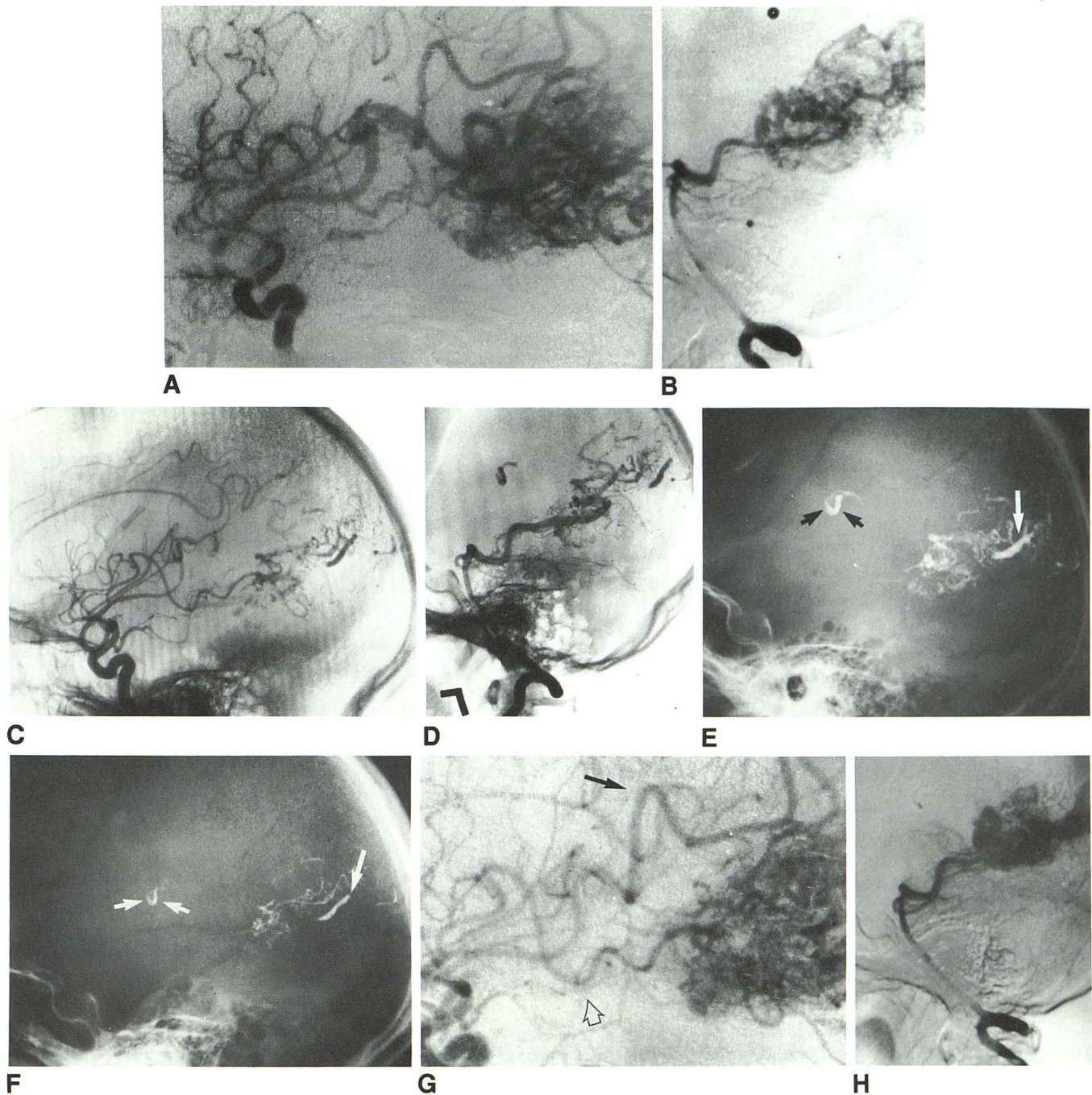


Fig. 1.—Case 1: Sequential angiograms.

A, Right carotid preembolization angiogram, lateral view. Posterior parietal and angular arteries supply arteriovenous malformation (AVM).

B, Vertebral angiogram, lateral view. Parietooccipital and calcarine arteries contribute to AVM.

C and D, Immediate postembolization right carotid and vertebral angiograms show significant reduction of AVM nidus.

E, Plain skull film, lateral view. Isobutyl 2-cyanoacrylate (IBCA) cast is seen in middle cerebral and posterior cerebral arterial territories (*long arrow*). A loop and segment of feeding arteries contain IBCA (*short arrows*).

F, Plain skull film 15 months later shows resorption and shrinkage of IBCA cast (*long arrow*). Closed arterial loop (*short arrows*) suggests contraction of vessel.

G and H, Follow-up angiograms of right carotid and vertebral arteries, lateral views. AVM is reconstituted. Recanalized branch of posterior parietal artery is noted (*solid arrow*). Hypertrophied posterior temporal branch is seen also (*open arrow*).

was performed by sandwiching 0.3 ml of the bucrylate mixture between 0.4 ml of 5% dextrose on either side in a 1-ml syringe. This technique was necessary to continuously flush the nidus with dextrose before injecting bucrylate, since the balloon was intentionally

not inflated and the jet was released by controlled injection. A mixture of 0.5 ml IBCA, 1.0 ml iophendylate, and 0.5 g tantalum powder was used. At the same session another microcatheter was used to catheterize a mildly enlarged posterior choroidal artery. During the

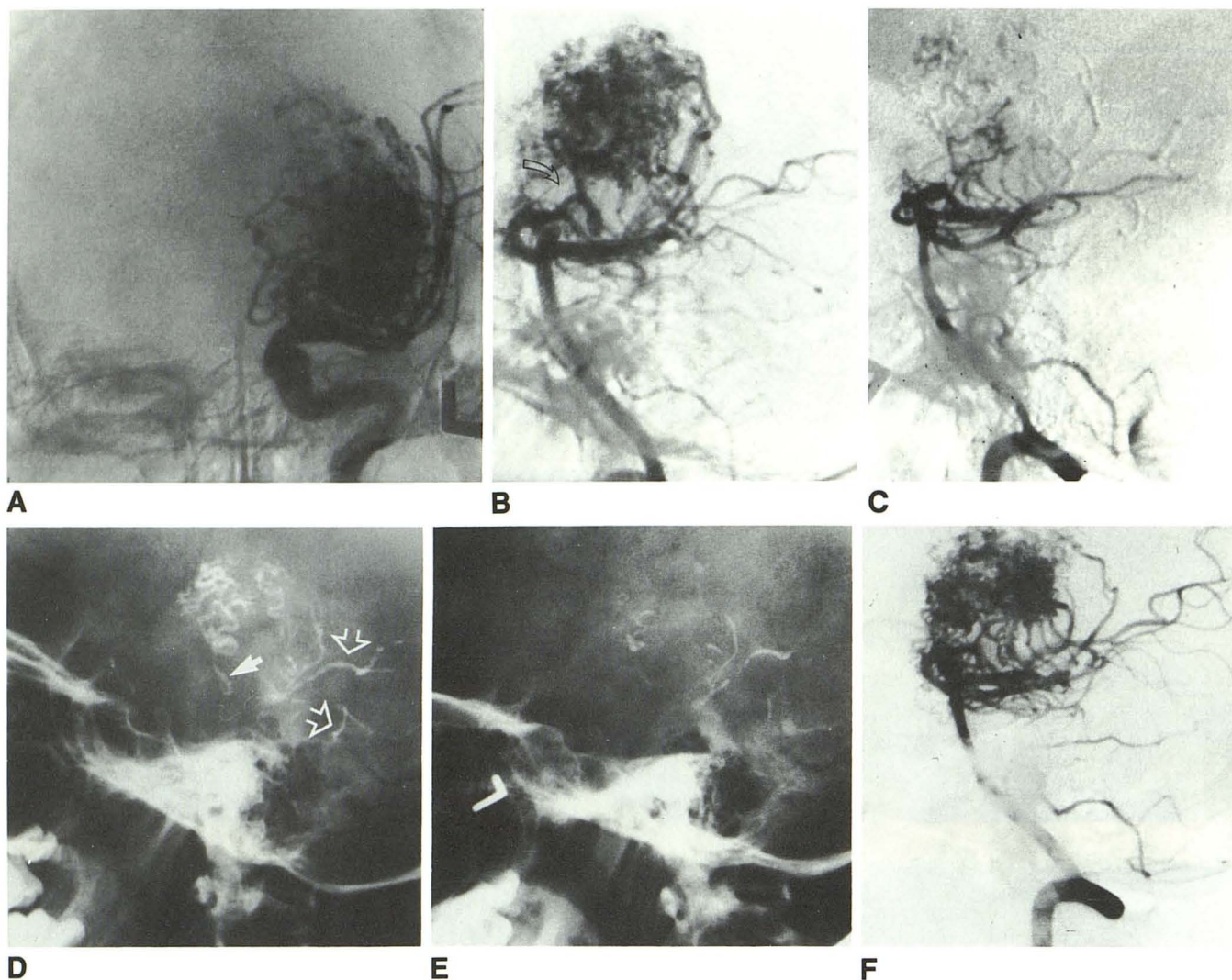


Fig. 2.—Case 6.

A and B, Preembolization carotid and vertebral angiograms. Multiple lenticulostriate arteries are seen supplying arteriovenous malformation (AVM). A single large thalamoperforating artery feeds AVM on vertebral angiogram (arrow).

C, Immediate postembolization angiogram shows remarkable reduction in size of AVM.

D and E, Plain films of skull. Immediate and follow-up (6 months) films show significant resorption of isobutyl 2-cyanoacrylate (IBCA). Cast in thalamoperforating artery (solid arrow) and reflux into cortical arteries (open arrows) are seen.

F, Follow-up vertebral angiogram, lateral view. Considerable reconstitution of AVM is seen. Many posterior choroidal arteries are hypertrophied.

injection of bucrylate, the catheter tip slipped into the main posterior cerebral artery and there was reflux of bucrylate into the cortical arteries (Fig. 2D). The patient had hemianopia before the procedure, but it did not continue. The nidus was reduced by about 50% (Fig. 2C). Six months later plain films revealed partial dissolution of the IBCA cast from a portion of the nidus as well as from the cortical arteries to an extent of 90% (Figs. 2D and 2E). Vertebral and carotid angiography showed remarkable reconstitution of the AVM, but reduced flow did not permit superselective catheterization (Fig. 2F).

Case 16

A 36-year-old man had a painless swelling at the back of the right shoulder region. There was a palpable thrill over the swelling on the wing of the scapula. The swelling was compressible and a bruit was heard. Selective axillary angiography revealed a hypertrophied posterior humeral circumflex artery, subscapular artery, acromial branch

of the suprascapular artery, and deltoid branch of the acromiothoracic artery. After balloon detachment into the posterior humeral circumflex artery, IBCA was injected into the deltoid branch of the subscapular artery. The smaller feeding arteries could not be selectively catheterized adequately for further embolization (Fig. 3). There was no visible cast of IBCA on the plain film of the right shoulder after 12 months (Fig. 3D). Repeat angiography showed residual AVM, though the embolized branch of the subscapular artery was not recanalized (Fig. 3E). The residual feeders were still inaccessible for embolization, and, because the lesion was extensive and deep-seated, repeat embolizations were considered for the future.

Discussion

Preembolization superselective angiography of AVMs clearly reveals the size of the nidus, arteriovenous transit time, and any functioning arterial branches distal to the cali-

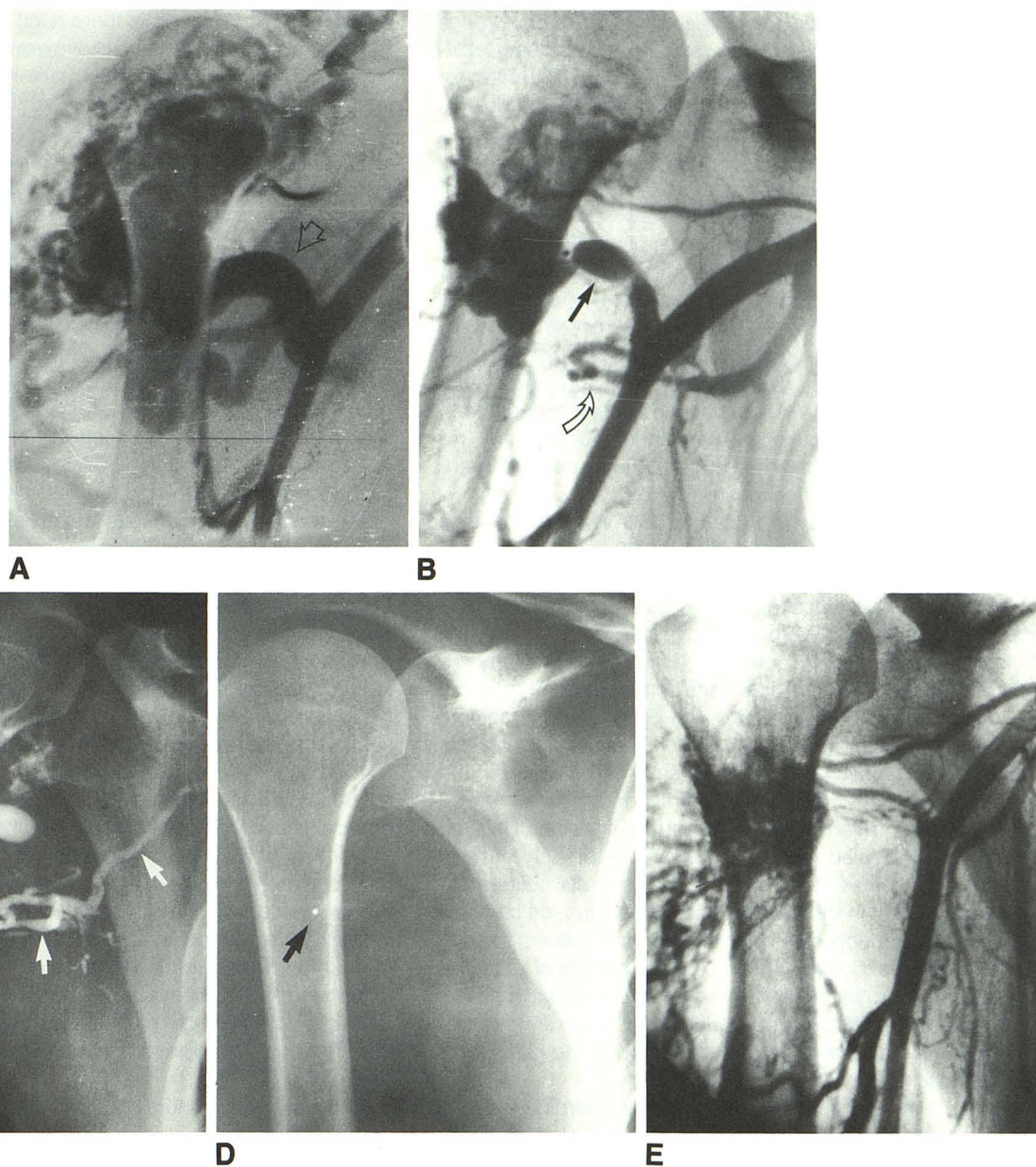


Fig. 3.—Case 16.

A and B, Pre- and postembolization axillary angiograms, anteroposterior views. Large posterior humeral circumflex artery (arrow) is seen feeding arteriovenous malformation (AVM). Balloon is shown occluding posterior humeral circumflex artery (straight arrow) and isobutyl 2-cyanoacrylate (IBCA) cast is seen in subscapular artery (curved arrow).

C, Plain film of right shoulder, anteroposterior view. Detached balloon and IBCA cast are seen (arrows).

D, Plain film of right shoulder after 12 months. There is no trace of IBCA. Clip of deflated balloon is seen (arrow).

E, Axillary angiogram. Long-term follow-up 12 months later shows residual AVM fed by deltoid and acromion branches, as well as by profunda brachii.

brated-leak balloon [3]. Complete obliteration of the nidus of the AVM is achieved by careful placement of the calibrated-leak balloon and accurate assessment of the arteriovenous transit time [4, 5]. Proper choice of the mixture of IBCA and iophendylate is essential to deliver the monomer precisely into the nidus, avoiding polymerization proximally in the feeding artery [6, 7]. Postembolization thrombosis in the nidus is the primary objective, but when embolization is incomplete in large AVMs the process of thrombosis may continue over a period of time until the nidus is obliterated. Distal propagation

of the thrombus into the draining veins was explained by Vinuela et al. [1] as the direct active thrombogenic effect of IBCA accentuated by a decrease in the circulation in the bed of the AVM and eventual stasis of blood. The abnormal permeability of the vascular channels and the regional inflammatory reaction were also incriminated in the acceleration of the process of thrombosis [2, 8].

Long-term follow-up of 30 patients treated by Vinuela et al. [9] revealed reconstitution of the AVM nidus and development of extensive collaterals in six patients. The development of

pial, meningeal, and medullary collaterals and reappearance of the nidus were related to the degree of preliminary obliteration of the AVM as well as to the proximity of delivery of IBCA to the nidus. The long-term radiographic and pathologic follow-up of 14 patients by Freeny et al. [10] included four living patients, and mention was made that only one of them did not show any change in the appearance of the IBCA cast at the end of 3 months. Radiographic follow-up in nine of our patients revealed remarkable resolution of the IBCA cast and even complete resorption in two patients. The extent of IBCA resolution did not relate to the interval from embolization to the follow-up angiogram, as evidenced in cases 3 and 15 (Table 1). Interestingly, in the AVM involving the shoulder region, though the IBCA cast completely disappeared at the end of 12 months, the AVM was not completely reconstituted. However, the flow through the partially embolized AVM remained reduced on delayed angiography, not permitting superselective catheterization (cases 1 and 6).

In our first patient, who had a large AVM with multiple feeding arteries, a reduction of about 75% was achieved by embolization at two sessions. IBCA was injected very close to the nidus in the calcarine artery, but a proximal feeding branch escaped embolization. A small quantity was also seen in the posterior parietal branch. Repeat angiography 15 months later showed not only considerable reduction in the flow but also resorption of part of the IBCA cast. In addition, an actual reduction in the caliber of the embolized vessels was evident. Deposit of IBCA in the small arterial loop of the feeding branch from the middle cerebral artery clearly showed evidence of resorption as well as diminution in caliber. Delayed angiography revealed recanalization of one branch immediately distal to the cast in the loop and the other still obliterated. Similarly, the cast in the vessel close to the vault, on comparison, showed reduction in length as well as caliber, thereby indicating a retraction in its volume. This additional observation on close scrutiny implies that there was reduction in the volume of "visible" IBCA cast in addition to "apparent" resorption. This may have been due to shrinkage of the nidus itself compounded by perivascular gliosis.

In case 6 the small striate and posterior choroidal arteries were not accessible to either IBCA or particulate embolic agents, and hypertrophy of these vessels was anticipated for a future embolization. Follow-up angiography 6 months later did not show a significant change in the caliber of the medial choroidal arteries, but resolution of IBCA from a portion of the nidus as well as from the posterior lateral choroidal and cortical arteries appeared on plain films.

Reports on the histology of bucrylate embolization have described a chronic inflammatory response [11, 12]. Varying degrees of collagenization, fibrosis, and mild lymphohistiocytic infiltrate with indistinct layers of normal vessel walls have been observed on light microscopy. There has been intense multilayer proliferation of cells immediately adjacent to the intraluminal bucrylate [13]. The giant cell reaction has been confined to the vessel lumen without any reactive changes in the media or adventitia [10, 14]. Electron microscopic studies have revealed disruption and stripping of endothelial cells by the polymer. Studies on a series of cyanoacrylate monomers established that IBCA has been the most slowly degrading

monomer [15]. Apparently there is no description of intracellular phagocytosis of bucrylate. However, persistence of IBCA within the lumen of the vessel as a refractile substance on light microscopy was documented by modified histologic stains. Partial dissolution of bucrylate, as seen in our patients, suggests disintegration and a possible phagocytic phenomenon associated with bucrylate that so far has been considered nonbiodegradable. In order to prove biodegradability it would be necessary to demonstrate electron-dense bodies (bucrylate) within the lysosomes of the endothelial cells.

The quantity of iophendylate used in all our patients was high, and it is not likely that iophendylate had dissociated from the bucrylate with reduction in the radiopacity of the cast. Recanalization of the cast and the full-blown appearance of the nidus as well as of the feeding arteries further emphasize the dissolution of the bucrylate matrix, either partially or in its entirety. Although IBCA-induced thrombosis is well recognized from histologic studies, persistence of occlusion of the feeding artery despite the invisibility of the IBCA cast in its lumen at repeat angiography indicates that the possibility of IBCA iophendylate dissociation cannot be ruled out altogether. Cromwell and Kerber [6] observed that mixing IBCA with iophendylate does not reduce the strength of the polymer or render it susceptible for earlier disintegration, nor does the iophendylate separate from IBCA. The bloodstream is mildly basic and the negative ion initiates polymerization. The convection currents disperse the iophendylate and expose IBCA to the base. Polymerization does not occur until the iophendylate is sufficiently dispersed by the processes of diffusion and convection. With an excess quantity of iophendylate in the vicinity of IBCA, polymerization is inhibited [7]. The interplay between the physical and chemical factors involved in the processes of diffusion and convection to disperse the iophendylate and the exposure of the IBCA to the base in the blood may have been inadequate due to the larger quantity of iophendylate used in our patients. The unaltered IBCA with tantalum powder might have had a transient oblitative effect on the nidus with delayed recanalization due to high flow in the AVMs.

In this study, a mixture of IBCA, iophendylate, and tantalum powder offered good radiopacity and immediate reduction in the size of the nidus of the AVM. However, partial or complete resorption of the IBCA cast was observed on delayed follow-up. In addition to actual resorption there appeared to be retraction of the nidus and shrinkage of the feeding vessel. It remains to be investigated whether the occluded vessel without an apparent IBCA cast within is due to the IBCA dissociated from iophendylate or IBCA-induced thrombosis. However, the documented evidence of the extent of recanalization in this report suggests that AVMs may be excised soon after embolotherapy to minimize blood loss, and inoperable ones may be embolized as completely as possible to reduce the sump effect and eventual steal phenomenon.

REFERENCES

1. Vinuela FV, Fox AJ, Debrun G, Drake CG, Peerless SJ, Girvin JP. Progressive thrombosis of brain arteriovenous malformations after embolization with isobutyl 2-cyanoacrylate. *AJNR* 1983;4:1233-1238

2. Vinters HV, Debrun G, Kaufmann JCE, Drake CG. Pathology of arteriovenous malformations embolized with isobutyl 2-cyanoacrylate (bucrylate). Report of two cases. *J Neurosurg* **1981**;55:819-825
3. Vinuela F, Fox AJ, Debrun G, Pelz G. Preembolization superselective angiography: role in the treatment of brain arteriovenous malformations with isobutyl 2-cyanoacrylate. *AJNR* **1984**;5:765-769
4. Debrun G, Vinuela F, Fox AJ, Drake CG. Embolization of cerebral arteriovenous malformations with bucrylate. Experience in 46 cases. *J Neurosurg* **1982**;56:615-627
5. Vinuela FV, Debrun GM, Fox AJ, Girvin JP, Peerless SJ. Dominant hemisphere arteriovenous malformations: therapeutic embolization with isobutyl 2-cyanoacrylate. *AJNR* **1983**;4:959-966
6. Cromwell LD, Kerber CW. Modification of cyanoacrylate for therapeutic embolization: preliminary experience. *AJR* **1979**;132:799-801
7. Spiegel SM, Vinuela F, Goldwasser JM, Fox AJ, Pelz DM. Adjusting the polymerization time of isobutyl 2-cyanoacrylate. *AJNR* **1986**;7:109-112
8. Tadvartthy SM, Moller JH, Amplatz K. Polyvinyl alcohol (Ivalon)—a new embolic material. *AJR* **1975**;125:609-616
9. Vinuela F, Fox AJ, Pelz D, Debrun G. Angiographic follow-up of large cerebral AVMs incompletely embolized with isobutyl 2-cyanoacrylate. *AJNR* **1986**;7:919-925
10. Freeny PC, Mennmeyer R, Kidd R, Bush WH. Long term pathologic follow-up of patients treated with visceral transcatheter occlusion using isobutyl 2-cyanoacrylate. *Radiology* **1979**;132:51-60
11. Kish KK, Rapp SM, Wilner HI, Wolfe D, Thomas LM, Barr J. Histopathologic effects of transarterial bucrylate occlusion of intracerebral arteries in mongrel dogs. *AJNR* **1983**;4:385-387
12. Vinters HV, Galil KA, Lundie MJ, Kaufmann JCE. The histotoxicity of cyanoacrylates. *Neuroradiology* **1985**;27:279-291
13. Mastri AR, Chous N. Neural and vascular reaction of cyanoacrylate adhesive: a further report. *Neurosurgery* **1982**;11:363-366
14. Vinters HV, Lundie MJ, Kaufmann JCE. Long term pathological follow-up of cerebral arteriovenous malformations treated by embolization with bucrylate. *N Eng J Med* **1986**;314:477-483
15. Lehman RAW, Hayes GJ, Leonard F. Toxicity of alkyl 2-cyanoacrylates. *Arch Surg* **1966**;93:441-446