

Generic Contrast Agents

Our portfolio is growing to serve you better. Now you have a *choice*.



FRESENIUS
KABI

[VIEW CATALOG](#)

AJNR

CT morphology of intrathecal lumbosacral nerve-root compression.

J T Wilmink

AJNR Am J Neuroradiol 1989, 10 (2) 233-248

<http://www.ajnr.org/content/10/2/233>

This information is current as
of May 10, 2025.

CT Morphology of Intrathecal Lumbosacral Nerve-Root Compression

J. T. Wilmink¹

Spinal CT scans and radiculograms of 100 patients who had undergone both examinations were studied with the aim of identifying morphologic CT features associated with compression of the intrathecal segment of the nerve root as demonstrated by radiculography. The interest for such a study lies in the fact that, in contradistinction to the distal, extrathecal root segment outlined by fat in the foramen, the proximal segment within the dural sac cannot be distinguished from the surrounding CSF by CT. CT features assessed consisted of deformation of the dural sac and displacement of the surrounding epidural fat. These features were compared with radiculographic signs of root involvement in the same location: kinking of the nerve root, local swelling of the root within the dural sac or the root sheath, and cutoff of root-sheath filling. In addition, a separate "expert opinion" verdict was given in each location as to the likelihood of compression of the intrathecal root segment on the basis of CT findings as confirmed or rejected by radiculography. A degree of correlation existed between CT and radiculographic features in clearly normal or abnormal locations, but there were some marked discrepancies. In borderline cases there were many discrepancies. The lack of agreement was confirmed by generally disappointing kappa values. The expert opinion, combining separate radiologic features into verdicts for CT and radiculography, did not lead to significantly better agreement as expressed by kappa, but less extreme discrepancies were seen. It proved to be possible, however, to distinguish locations with CT features likely to correlate well the radiculographic picture from those less likely to show good correlation. Such a distinction can guide the decision whether or not to perform confirmatory radiculography. False-positive locations were identified by questionnaire; CT and radiculographic features proved to differ only a matter of degree from the same features in presumably symptomatic locations.

CT and radiculographic findings in compression of the intrathecal segment of the nerve root are complementary. Correlating the two studies is of limited value because they provide different anatomic information.

The advent of high-resolution CT in the late 1970s has had a profound influence on the radiologic diagnosis of lumbosacral nerve-root compression. Beyond the fact that CT in these cases is less invasive than the other primary imaging technique of radiculography, CT also directly depicts the lesion compressing the nerve root, which radiculography cannot. Although narrowing of the spinal canal was previously known as a potential cause of nerve-root involvement [1-4], the high-resolution transverse sectional view of the spinal column provided by CT has brought about widespread realization of the frequency of spinal narrowing, often in combination with disk lesions, as an etiologic factor in sciatica. At the same time a better classification is possible of the type of narrowing as a guide to surgical therapy [5-14]. A number of studies have been devoted to comparison of the relative accuracies of CT and radiculography in predicting the anatomic situation later found at surgery (disk herniation, nerve-root compression, etc.) [15-19]. Unfortunately, with an occasional exception [20], exact radiologic features forming the basis for comparison are rarely specified. This point is important, because anatomic details can be demonstrated by either of the two techniques that are missed by the other.

Received April 27, 1988; accepted after revision November 25, 1988.

¹ Department of Neuroradiology, University Hospital, 59 Oostersingel, 9713 EZ Groningen, the Netherlands. Address reprint requests to J.T. Wilmink.

AJNR 10:233-248, March/April 1989
0195-6108/89/1002-0233
© American Society of Neuroradiology

For example, literature reports are unanimous with respect to the superiority of CT for detecting disk herniations at the L5-S1 level [18, 21-23]. The explanation usually given is that the wider epidural space between the disk and the dural sac at this level prevents all but the larger disk protrusions from impinging on the dural sac and thus becoming manifest radiculographically. The question of course is whether small lesions in this location, which can be demonstrated by CT and verified by surgery and which appear to be compressing only epidural fat and veins and not the nerve root, bear any relationship to the patient's symptoms (Fig. 1). A recent report [24] has indicated that abnormal spinal CT findings may be demonstrated in up to one in three asymptomatic individuals, occurring with even higher prevalence as age increases. This problem seems likely to become increasingly manifest as the resolving power of imaging techniques increases and the invasiveness (and thereby the "referral threshold") diminishes.

It could be said that CT is superior in depicting the *cause* of potential nerve-root involvement (disk herniation, spinal narrowing, scarring, neoplasm), while radiculography is better in assessing the *effects*. The appearance of the intrathecal cauda equina fibers in the dural sac and root sheaths is well demonstrated by radiculography, and radiologic signs such as deviation and stretching of roots, swollen roots, and cutoff of root-sheath filling appear to clearly indicate nerve-root involvement. CT does not provide such a direct image of the intrathecal portion of the nerve root, possessing insufficient resolution to distinguish the root from the surrounding CSF. Once the nerve root has departed from the subarachnoid space (after the termination of the root sheath), the situation becomes reversed and the root is invisible to radiculography

but well depicted by CT, surrounded by the epidural fat of the intervertebral foramen or sacral canal (Fig. 2).

As the intrathecal segment of the nerve root may be considered invisible to CT just as the extrathecal portion is to radiculography, and as nerve-root compression in the intrathecal segment is much more common than in the extradural distal or foraminal course, CT would appear to be at a disadvantage. However, CT can demonstrate deformation of the dural sac and root sheath, and in many cases the presence or absence of intrathecal nerve-root involvement may be assumed from the degree of deformity of these structures. Such interpretation does not present any great difficulty when the CT picture is clearly normal or severely abnormal, but there are many borderline situations in which the dural sac is somewhat indented or deformed, and if it is impossible to say with any confidence whether the nerve root within is being compressed or has escaped compression. It is the aim of this study to explore this border zone, establish its magnitude, and ascertain whether certain specific morphologic changes in and around the dural sac as assessed by CT are of value in predicting the likelihood of intrathecal nerve-root involvement as visualized by radiculography.

Materials and Methods

One hundred plain spinal CT examinations performed consecutively in our department between March and December 1985 were studied. They demonstrated a local or generalized disk bulge, narrow-appearing spinal canal, deformation of the dural sac, and/or obliteration of the epidural fat ventrolateral to the dural sac. CT examinations

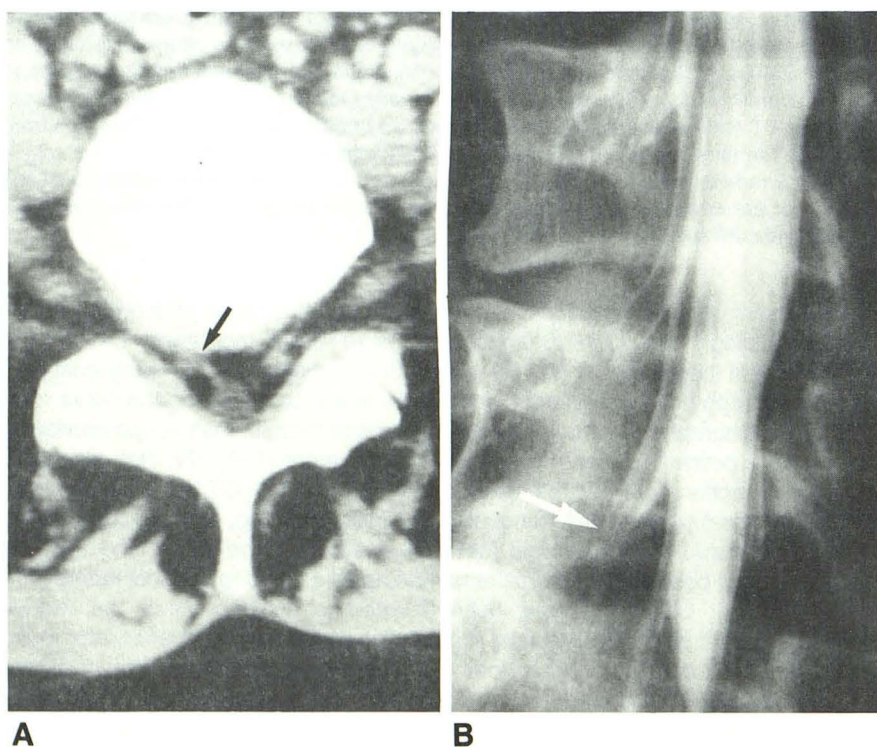


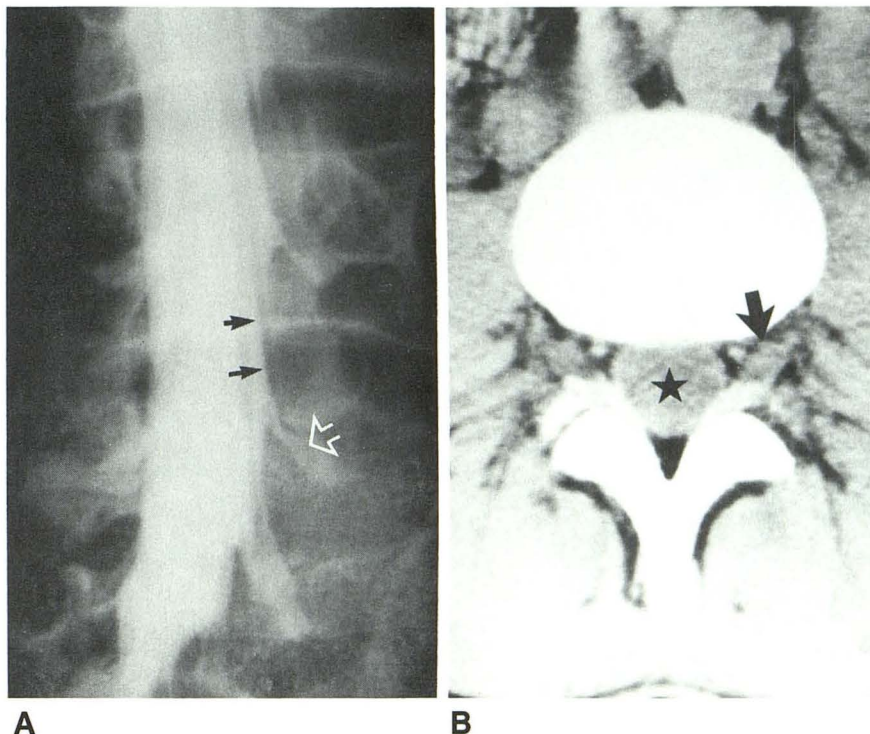
Fig. 1.—Patient with left sciatica due to L4-L5 herniation (not shown).

A, CT scan shows right L5-S1 disk protrusion displacing epidural fat in lateral part of spinal canal, but not compressing S1 nerve-root sheath (arrow).

B, Radiculogram confirms lack of root-sheath compression (arrow).

Fig. 2.—A, Intrathecal segment of nerve root (solid arrows) well depicted on radiculogram at level of disk and lateral recess, but root is lost to view after termination of root sheath (open arrow), usually at foraminal entrance.

B, CT shows more distally located spinal root ganglion (arrow). However, CT does not provide image of individual cauda equina fibers within dural sac (asterisk).



routinely involved the L4–L5 and L5–S1 levels, with additional levels being scanned when considered necessary on clinical grounds.

Patients had been referred because of suspected lumbosacral nerve root compression; in addition to CT, a water-soluble radiculogram had been obtained within the 6-month period before or after CT in our department or elsewhere, and neither surgery nor chemo-nucleolysis had been performed in the intervening period. In 14 cases, the period between the two studies was less than 1 week; in 38 cases, it was 1–4 weeks; in 38 cases, it was 4–12 weeks; and in 10 cases, it was 12–26 weeks. A number of patients involved in this study have had spinal surgery. The surgical findings were not included in this analysis because the aim of this study was not to assess the ability of CT to demonstrate disk herniation or spinal narrowing, which can be verified by surgery. This question has been addressed in previous studies. The present CT assessment with regard to involvement of the nerve root within the dural sac is much less easily verifiable by surgery.

CT was performed with a Tomoscan 310 scanner with contiguous 4.5-mm sections. Both CT scans and radiculograms had to be of adequate image quality; cases were also excluded when nerve-root compression occurred distal to the root sheath and the radiculogram was completely normal.

In the 100 cases studied, a total of 204 locations were identified where CT indicated possible nerve-root involvement. These locations were distributed over four disk levels: L2–L3, one location; L3–L4, 20; L4–L5, 117; and L5–S1, 66.

CT (and radiculographic) morphology of root involvement varies according to the level at which compression is applied:

1. At the supraaxillary level, above the point of emergence of the root sheath from the dural sac, compression in an anteroposterior direction will flatten or collapse the ventrolateral portion of the dural sac, thus decreasing its transverse dural diameter and displacing the adjacent epidural fat. This tends to cause inward kinking of the intrathecal nerve root, and sometimes root swelling. The root sheath fills normally (Fig. 3).

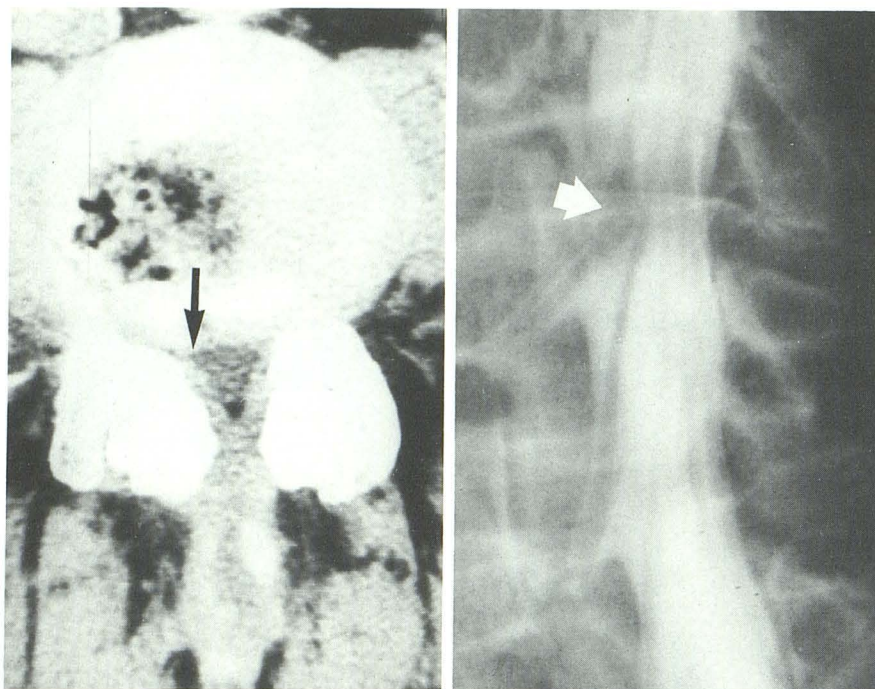
2. At the axillary level, at or below the point of origin of the root sheath, compression will lead to flattening of the emerging root sheath and displacement of the surrounding fat. Contrast filling of the root sheath is interrupted and the nerve root shows scallionlike widening over the last few millimeters above the site of compression (Fig. 4).

If CT at the level of compression showed flattening of the root sheath in the epidural fat lateral to the dural sac as in Figure 4, or if the first CT section below the level of compression showed the root sheath clearly separated from the dural sac, the site of involvement was classified as axillary. In all other cases the classification was supraaxillary. Supraaxillary involvement was seen 96 times and axillary involvement 108 times. A single lesion may compress the root sheath at the axillary level, and also indent the adjacent dural sac. For practical reasons these were classified as root-sheath involvement only unless dural deformity was very marked and there appeared to be supraaxillary involvement of the next emerging root.

The following CT features were considered indicative of intrathecal nerve-root involvement and were rated according to specific scoring rules.

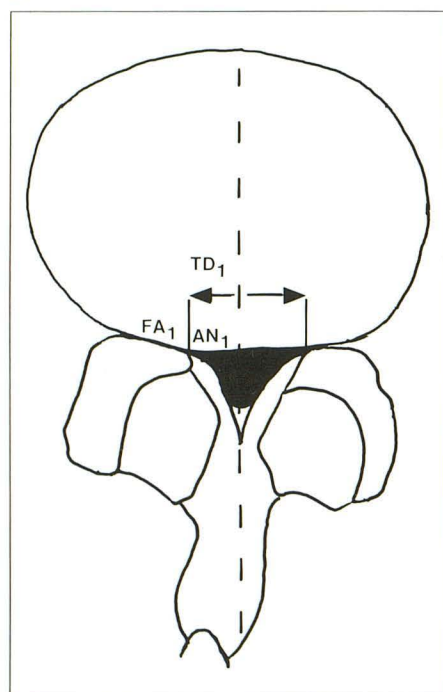
1. TD_1 : decrease in the transverse diameter of the dural sac by collapse of the ventrolateral angle (in cases with supraaxillary involvement). The maximum lateral extent of the dural sac is measured and compared with the opposite side in unilateral involvement, superior and inferior levels in bilateral involvement. Reduction is expressed as a percentage, and TD_1 is scored 1 for reduction by 0–19%, 2 for reduction by 20–29%, 3 for reduction by 30–39%, and 4 for reduction by 40% or more (Figs. 3, 5A and 5B).

2. TD_2 similarly indicates compression of the nerve-root sheath in cases with axillary involvement. The root sheath is considered involved if surrounding epidural fat has been obliterated and the root sheath itself deformed or flattened. In this case, the farthest laterally extending dural structure is measured, and that measurement is compared with the contralateral side, superior or inferior level. Percentage reduction of TD_2 is scored in a fashion similar to TD_1 (Figs. 4 and 5C).

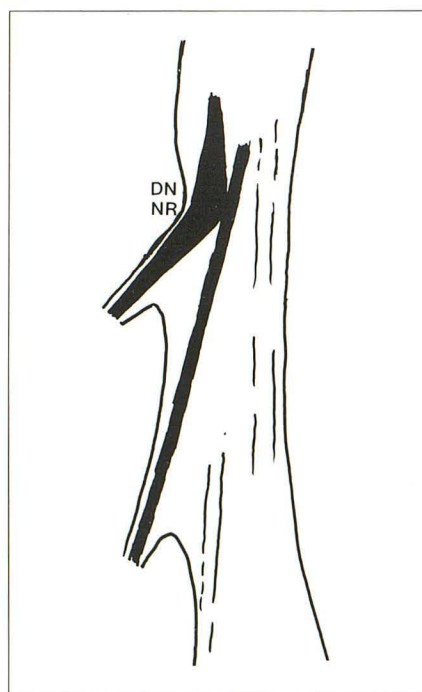


A

B



C



D

Fig. 3.—Supraaxillary L5 root involvement by combination of facet hypertrophy and degenerative L4–L5 disk bulging. See key for abbreviations.

A, Ct scan shows flattening of ventrolateral angles of dural sac, most pronounced on right (arrow).

B, Radiculogram shows inward kinking and swelling of right L5 root (arrow), with normal root-sheath filling.

C and D, Tracings of CT and radiculographic images illustrate rating features. TD₁ can be measured as shown, but reduction in transverse diameter of dural sac cannot be assessed by comparing abnormal with normal sides, as there are bilateral abnormalities. Comparison, therefore, is made with transverse dural diameter at more cranial and caudal levels. AN₁ is rated 5, as ventrolateral angle of dural sac is acute and dural surfaces are inwardly convex. FA₁ is rated 3, as fat, normally present adjacent to dural sac at disk level, is obliterated. Radiculographic rating for DN is 5, as marked inward kinking of L5 root is present; NR is rated 5 because L5 root is swollen to more than twice its original diameter. (See text.) Normal S1 root is traced in black.

Key to Abbreviations Used in Figures 3–5 and 7

AM	amputation or cutoff of root-sheath filling
AN ₁	flattening of ventrolateral angle of dural sac
AN ₂	flattening of emerging root sheath
DN	deviation or kinking of nerve root within dural sac
FA ₁	disappearance of epidural fat adjacent to dural sac
FA ₂	disappearance of epidural fat surrounding root sheath
NR	swelling of nerve root proximal to site of involvement
RG	radiculography
TD ₁	decrease in transverse diameter of dural sac
TD ₂	decrease in lateral extension of root sheath

3. AN₁: flattening of the ventrolateral angle of the dural sac in cases with supraaxillary involvement. A score of 1 is given for a rounded ventrolateral aspect of the dural sac, 3 when the angle is no longer rounded but the adjacent dural surfaces are flat or outwardly convex, and 5 when the angle is flattened and adjacent dural surfaces are inwardly convex (Fig. 6). Scores 2 and 4 are given when there is difficulty in deciding between 1 and 3 and 3 and 5, respectively.

4. AN₂: flattening of emerging root sheath in cases with axillary involvement. A score of 1 is given when the root sheath is not deformed, 3 when flattened, and 5 when obliterated. Scores 2 and 4 are again awarded in transitional cases (Figs. 4 and 5C).

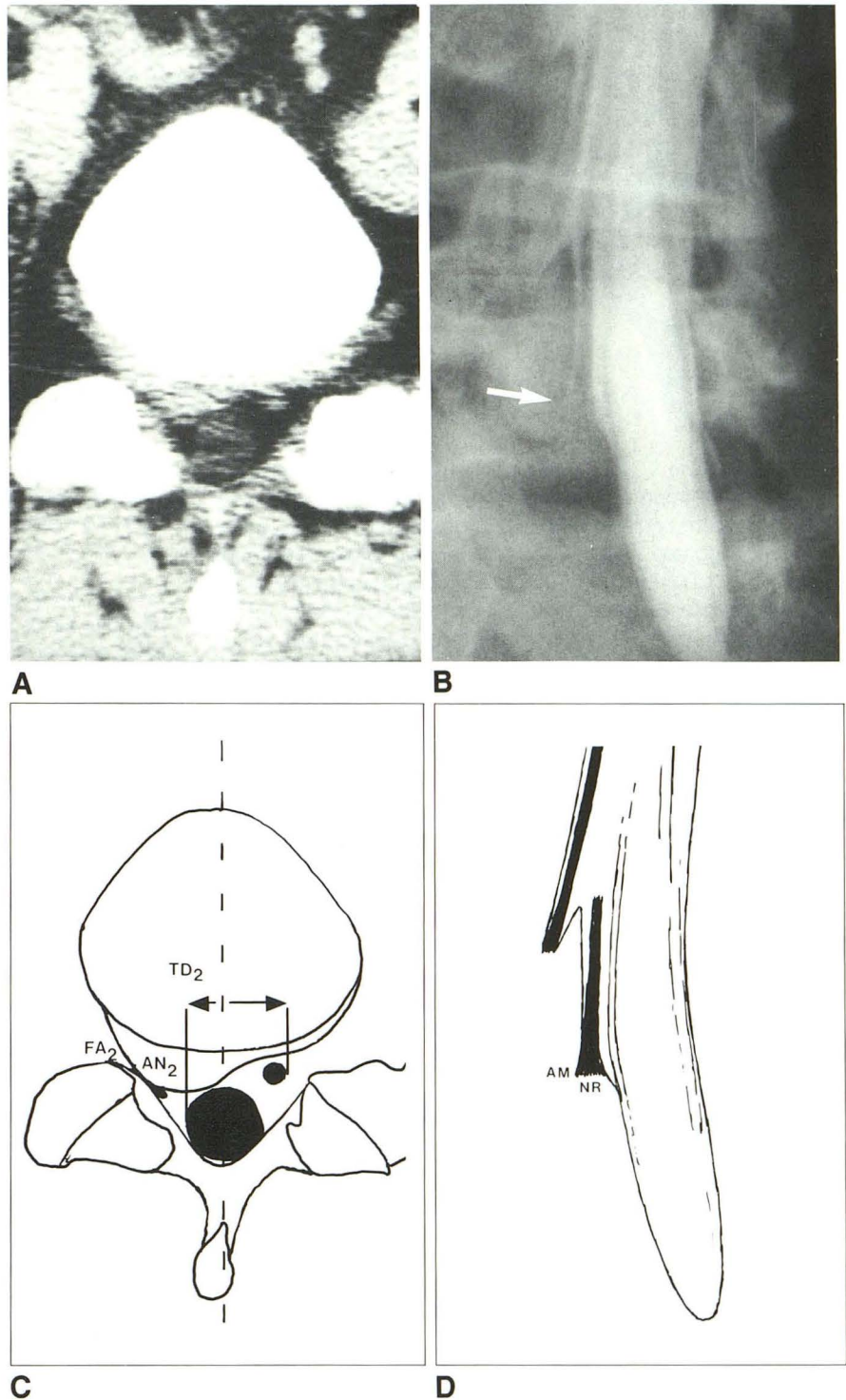
5. FA₁: obliteration of epidural fat ventrolateral to the dural sac in case of supraaxillary involvement. Fat is normally present at the level of the disk and the intervertebral foramen and is absent in the lateral

Fig. 4.—Axillary S1 root involvement by right L5-S1 disk herniation. See key for abbreviations.

A, CT scan shows right S1 root can no longer be distinguished from herniated diskal mass. No deformation of dural sac.

B, Radiculogram shows cutoff of root-sheath filling and swelling of distal right S1 root segment (arrow).

C and D, Tracings of CT and radiculographic images illustrate rating features. TD_2 can be measured as shown, and is reduced by 44% on right; thus, rating is 4 (see text). AN_2 is rated 5, as root sheath is no longer visible. FA_2 is rated 3, as fat around root sheath is obliterated. AM is rated 5 because no filling of root sheath can be seen; NR is rated 5 because distal S1 root segment is swollen to twice its proximal diameter. Normal L5 root is traced in black.



recess. A score of 1 is given when fat is present, 3 when fat is unilaterally absent or bilaterally absent at a level where it is normally present, and 2 in transitional cases (Figs. 3, 5A, and 5B).

6. FA_2 is similarly used to rate obliteration of fat around the root sheath in cases with axillary involvement (Figs. 4 and 5C).

7. NC_1 and NC_2 : nerve-root swelling distal to site of supraaxillary and axillary compression, respectively. A score of 1 is given when

the root in question is equal to or smaller than its contralateral counterpart and a score of 3 when larger. NC_1 and NC_2 are not rated in bilateral lesions, as symmetric roots then could be due to bilateral swelling.

The CT assessment was matched against the radiculographic rating of the nerve root in the same location, also quantified according to scoring rules.

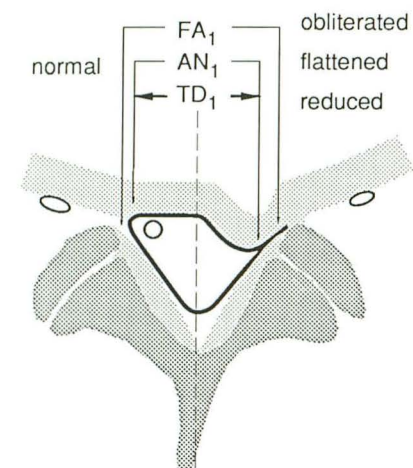
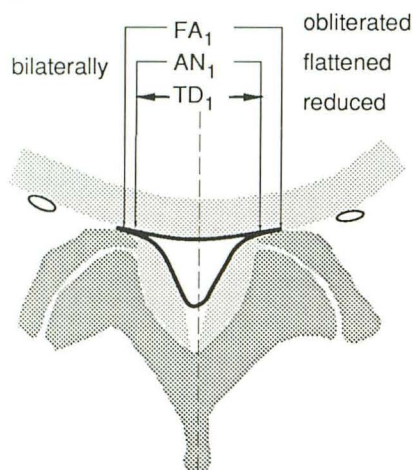
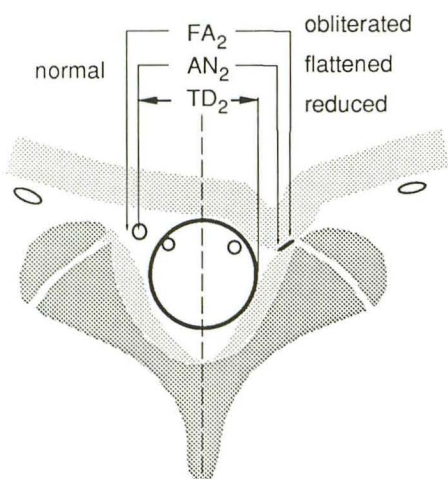
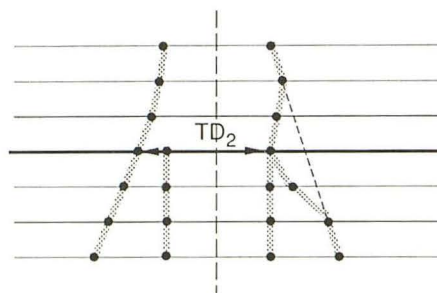

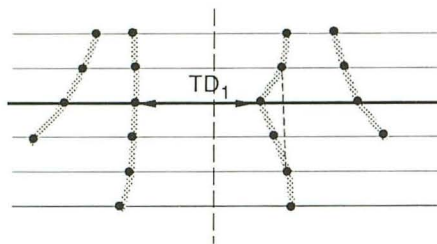
**A****B****C**

Fig. 5.—Schematic illustration of rating features. See key for abbreviations.

A, Unilateral compression at supraaxillary level. Obliteration of fat adjacent to dural sac (FA₁) and flattening of ventrolateral angle of dural sac (AN₁) are assessed by inspection. Reduction of transverse diameter of dural sac (TD₁) is measured by comparison with normal side. TD₁ measurements at several levels can be used to reconstruct lateral contours of dural sac and emerging roots, as seen at right.

B, Bilateral supraaxillary compression, left-right comparison now cannot be used to measure TD₁, and reduction in transverse dural diameter must be gauged on reconstructed diagram at right.

C, Unilateral compression at axillary level. Obliteration of fat around emerging root (FA₂) and flattening of root (AN₂) are assessed by inspection. Reduction of transverse diameter TD₂ is here expressed by measuring to lateral dural border; as nerve root is flattened and invisible, dural border is most laterally extending structure.

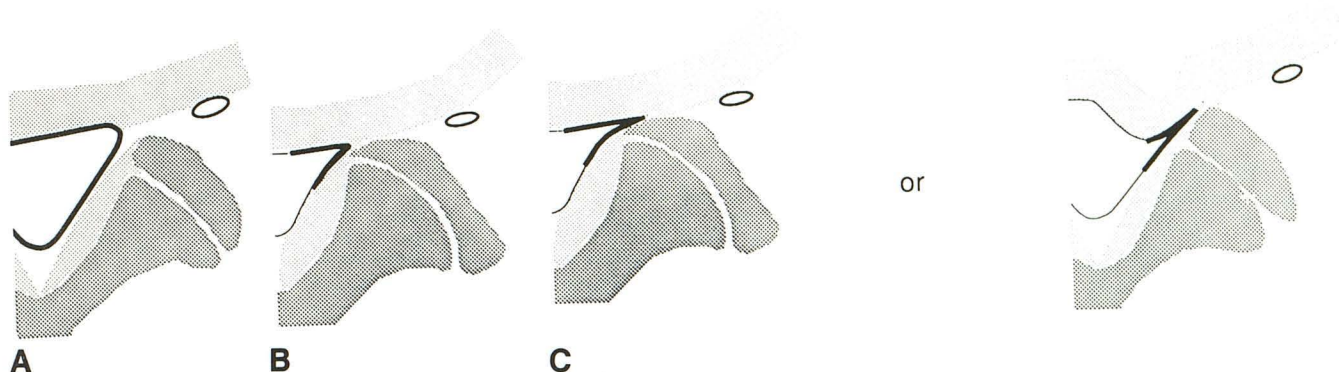


Fig. 6.—Scoring rules for AN_1 . See key for abbreviations. A, $AN_1 = 1$. B, $AN_1 = 3$. C, $AN_1 = 5$.

1. DN : inward angular deviation of the nerve root within the dural sac (supraaxillary involvement). A score of 1 is given when definitely no deviation is present, of 3 when definite but not severe deviation exists, and of 5 when there is marked inward kinking of the root. Scores 2 and 4 are reserved for transitional cases (Fig. 3).

2. AM : amputation or cutoff of root-sheath filling as compared with contralateral root sheath in unilateral axillary involvement and with adjacent levels in bilateral involvement. A score of 1 is given when root-sheath filling is normal, 3 when filling is reduced, and 5 when there is (virtually) complete cutoff. Scores 2 and 4 are awarded in transitional cases (Fig. 4).

3. NR_1 and NR_2 : nerve-root swelling within the dural sac and the root sheath, respectively, proximal to the site of compression. A score of 1 is given when no swelling exists, 3 if the root is swollen to less than twice its original diameter, and 5 if the root diameter is increased to twice or more the diameter of its proximal segment. Scores 2 and 4 are awarded in transitional cases (Figs. 3 and 4).

In order to assess the reproducibility of the rating method, the rating procedure was repeated in 10 cases selected at random.

Some months after the initial assessment, CT and radiculographic images of the 204 locations were again scrutinized separately. This time no analysis of isolated features was attempted, but an "expert opinion" was formulated with regard to the likelihood of nerve-root compression as assessed by CT and confirmed or repudiated by radiculography (the author reviews the majority of the approximately 800 spinal CT scans and 300 radiculograms obtained yearly in the neuroradiology department). CT studies were graded in a four-point scale, ranging from 1 (root involvement highly unlikely) through 2 (root involvement rather unlikely) and 3 (root involvement rather likely) to 4 (root involvement highly likely). Radiculographic studies were graded separately, also on a four-point scale: grades 1 (normal aspect of root), 2 (insignificant root abnormality), 3 (root significantly abnormal), and 4 (root severely abnormal). This process was repeated after some weeks.

As noted, each CT study contained on average of two locations in which nerve-root involvement could be surmised on the basis of the above criteria. Some form of clinical corroboration was considered necessary. Questionnaires were mailed to all 100 patients whose radiographs had been studied. Patients were asked to indicate on which side (if any) they had never had symptoms. In this way it was hoped that false-positive CT and radiculographic features could be established.

Results

Ratings from the separate CT and radiculographic features are cross-tabulated in Table 1. Ratings lacking from the

tabulations are those in which either the CT or the radiculographic features lacked sufficient detail to permit a confident rating, or in which bilaterally occurring lesions made a rating impossible solely on the basis of left-right comparison. The latter was frequently the case for CT feature NC.

The ideal correlation would take the shape of a cluster of points along a line running from top left (both techniques normal) to lower right (both techniques abnormal). As can be seen, such an ideal grouping was far from realized. As can also be seen in Table 1, the proportions between normal and abnormal findings vary with, in general, a higher incidence of normal findings in supraaxillary locations (left two columns DN and NR_1) and relatively more abnormal findings in axillary locations (right two columns, AM and NR_2). In order to correct for agreement due to chance resulting from this, Cohen's kappa was calculated for each cross-tabulation. This statistical procedure is set out in more detail in the Appendix. The calculated kappa values confirm that agreement above that due to chance appears at best fair.

Measurements of the transverse area of the dural sac proved to vary widely not only between individuals but also between various levels in one individual. It proved possible to relate the radiculographic appearance of a total or subtotal CSF block with a minimum value for the transverse area of the dural sac at L3–L4 or L4–L5 of about 40 mm² (Table 2).

The expert opinion ratings are cross-tabulated in Table 3. The material is presented separately for supraaxillary and axillary locations. It can be seen that the agreement between judgments on the integral CT and radiculographic pictures does not appear greatly superior to that between isolated CT and radiculographic features. At best it can be said that the ratings spread less widely from the ideal diagonal running from top left to bottom right than in the cross-tabulations given in Table 1. In other words the discrepancies appear quantitatively less severe in the expert opinion ratings. Kappa values calculated from these cross-tabulations are also presented in the Appendix.

Intraobserver consistency for rating separate CT and radiculographic features, and also for the expert opinion rating, is given in Table 4. Complete agreement for separate radiculographic features is rather low at 65%, but for ratings of the integral CT and radiculographic pictures, intraobserver consistencies are identical (78% complete agreement).

TABLE 1: Cross-tabulations of Ratings Comparing Isolated CT and Radiculographic Features

CT Features	Radiculographic Features																			
	Vs TD ₁ , AN ₁ , FA ₁ , NC ₁ (Supraaxillary)										Vs TD ₂ , AN ₂ , FA ₂ , NC ₂ (Axillary)									
	DN					NR ₁					AM					NR ₂				
	1	2	3	4	5	1	2	3	4	5	1	2	3	4	5	1	2	3	4	5
TD:																				
1	23	4	8	0	5	28	7	4	1	0	9	1	5	0	3	6	2	6	0	3
2	1	1	0	0	2	3	0	1	0	0	1	0	0	0	2	0	2	0	0	1
3	1	0	3	0	12	4	3	5	1	2	2	1	0	0	12	2	4	3	1	5
4	0	1	0	1	3	0	0	1	0	0	5	5	3	0	38	2	7	6	6	23
AN:																				
1	11	0	1	0	0	9	2	0	0	0	8	4	3	0	0	5	5	2	0	2
2	15	0	2	0	4	13	3	3	0	1	6	0	1	0	8	3	2	6	1	3
3	3	4	3	0	7	7	5	4	0	0	2	1	0	0	15	1	2	2	3	10
4	1	1	3	0	5	2	1	3	2	0	5	0	2	0	12	1	1	8	0	6
5	1	2	3	1	12	4	3	5	1	2	2	2	1	0	26	0	6	4	4	14
FA:																				
1	23	0	4	0	1	23	3	2	0	0	7	0	2	0	4	4	3	3	0	0
2	0	1	1	0	0	1	0	1	0	0	3	0	1	0	3	1	1	2	1	2
3	8	6	7	1	27	12	10	14	2	4	15	7	3	0	55	7	13	17	6	30
NC:																				
1	4	1	1	0	0	3	2	1	0	0	2	0	0	0	5	1	0	1	1	2
2	0	0	0	0	0	0	0	0	0	0	1	0	0	0	8	0	2	1	1	4
3	1	0	0	0	0	1	0	0	0	0	3	2	1	0	21	2	6	4	3	9

Note.—Rating scores of 1–5, 1–4, and 1–3 are described in the text, with 1 being clearly normal and 5, 4, and 3, respectively, being clearly abnormal. TD₁ = decrease in transverse diameter of dural sac; TD₂ = decrease in lateral extension of root sheath; AN₁ = flattening of ventrolateral angle of dural sac; AN₂ = flattening of emerging root sheath; FA₁ = disappearance of epidural fat adjacent to dural sac; FA₂ = disappearance of epidural fat surrounding root sheath; NC₁ and NC₂ = swelling of nerve root distal to site of involvement; DN = deviation or kinking of nerve root within dural sac; AM = amputation or cutoff of root-sheath filling; NR₁ and NR₂ = swelling of nerve root proximal to site of involvement.

TABLE 2: Radiculographic Findings in Individuals with a Decrease in the Transverse Area of the Dural Sac

Case No.	Transverse Area (mm ²)	Level	Block on Radiculogram	CT Appearance		
				Disk Herniation	Disk Bulging	Canal Narrowing
8	48	L4–L5	– (waisting)	–	+	++
9	32	L4–L5	+	++	–	++
14	26	L4–L5	+	–	–	++
25	41	L4–L5	– (contrast thinning)	++	–	+
26	40	L4–L5	+	–	+	++
51	23	L4–L5	+	–	+	++
56	20	L3–L4	+	–	+	++
56	30	L4–L5	+	–	+	++
60	41	L4–L5	– (contrast thinning)	++	–	–
62	27	L3–L4	+	–	+	++
67	11	L3–L4	+	+	–	++
80	58	L4–L5	– (lateral indentation)	++	–	+
81	40	L4–L5	+	++	–	+
82	60	L4–L5	– (slender dural sac)	–	–	–
84	48	L4–L5	– (lateral indentation)	–	–	++ ^a
86	57	L4–L5	– (waisting)	–	+	++
88	30	L3–L4	+	–	+	++
88	14	L4–L5	+	–	–	++ ^a
90	26	L4–L5	+	+	–	++
91	12	L4–L5	+	+	–	++
94	34	L4–L5	– (lateral indentation)	++	–	+

Note.—The transverse area of the dural sac at the level of compression was decreased to 60 mm² or less. The critical factor for a CSF block at these levels appears to consist of reduction in the transverse area of the dural sac to 40 mm² or less, with the exception of case 94. Under CT appearance, + = moderate, ++ = severe.

^a Together with spondylolisthesis.

TABLE 3: Cross-tabulations of "Expert Opinion" Ratings

CT	Radiculography											
	Supraaxillary (n = 95)				Axillary (n = 108)				All Locations (n = 203) ^a			
	1	2	3	4	1	2	3	4	1	2	3	4
1	10	5	1	0	3	1	0	0	13	6	1	0
2	5	14	8	1	1	8	4	2	6	22	12	3
3	0	11	9	7	4	13	21	14	4	24	30	21
4	0	0	2	22	0	2	8	27	0	2	10	49

Note.—A score of 1 is clearly normal; a score of 4 is clearly abnormal.

^a One CT location was judged unsuitable for rating.

TABLE 4: Intraobserver Consistency in Rating CT and Radiculographic Features

Variable	No. (%)			
	Complete Agreement	Disagreement		
		1 Point	>1 Point	Shift
Isolated features:				
CT (n = 76):				
TD	17	0	0	2
AN	9	9	1	0
FA	17	1	0	1
NC	15	1	0	3
Total	58 (76)	11 (15)	1 (1)	6 (8)
Radiculography (n = 57):				
DN	15	2	1	1
AM	12	2	3	2
NR	10	6	2	1
Total	37 (65)	10 (18)	6 (10)	4 (7)
"Expert opinion":				
CT (n = 203) ^a	158 (78)	21 (10)		24 (12)
Radiculography (n = 204)	160 (78)	26 (13)		18 (9)

Note.—Agreement was assessed between the first and second ratings for isolated CT and radiculographic features (133 ratings repeated in 10 of 100 cases in 19 locations) and for expert opinion (all ratings repeated in 203 and 204 locations in 100 cases). Disagreement of 1 or >1 point indicates the extent of disagreement on the rating scale. Opposite Isolated Features, the shift column reflects a shift in opinion as to suitability of location for scoring. Opposite Expert Opinion, the shift column indicates a shift of one or more points, crossing the borderline between normality and abnormality. TD = decrease in transverse diameter of dural sac or in lateral extension of root sheath; AN = flattening of ventrolateral angle of dural sac or of emerging root sheath; FA = disappearance of epidural fat adjacent to dural sac or surrounding root sheath; NC = swelling of nerve root distal to site of involvement; DN = deviation or kinking of nerve root within dural sac; AM = amputation or cutoff of root-sheath filling; NR = swelling of nerve root proximal to site of involvement.

^a One location was later judged to be unsuitable for rating.

Table 5 contains the locations presenting false-positive radiologic features occurring on the asymptomatic side, as well as the CT, radiculographic, and expert opinion ratings of these features. An analysis of the rating profiles for symptomatic and asymptomatic locations can be found in Figure 7.

It can be seen that asymptomatic locations can present significantly abnormal radiographic findings, albeit less frequently than presumably symptomatic ones.

Discussion

Radiculography and CT currently are the imaging techniques used most widely in the diagnosis of lumbosacral nerve-root-compression syndromes. As mentioned earlier, the two methods both have strong and weak points and are to some extent complementary. The choice between the two as the first examination in the workup before an operation to relieve sciatica is often determined by logistical factors. When there is no ready access to a high-resolution CT scanner, radiculography usually will be performed first. CT can then be reserved for the following eventualities:

1. Cases in which radiculography is normal and distal-root compression in a lateral location is suspected. An incidence for lateral root compression of up to 11.7% has been reported [25].

2. Cases in which radiculography shows root involvement, and a form of narrowing of the spinal canal, by itself or in combination with a disk lesion, is suspected. One literature report [3] indicates that in only about one-third of all cases is nerve-root compression due solely to disk herniation. Recognition of possible concomitant narrowing is of special importance when a "closed" procedure such as chemonucleolysis is being contemplated.

When there is sufficient CT capacity, this examination, because it is less invasive, must be considered the first imaging examination of choice. A CT finding of a large disk herniation or a marked degree of spinal narrowing makes further radiologic examination unnecessary. Radiculography may be performed as an adjunct in two situations:

1. When CT yields normal findings, and an intradural lesion at a higher level is suspected. A large herniation that completely flattens the dural sac and fills the entire spinal canal also may appear normal (Fig. 8).

2. When CT demonstrates a small disk herniation or some degree of spinal narrowing, the clinical significance of which is equivocal.

It was hoped to reduce the number of equivocal CT findings in the second group by establishing criteria based mainly on

TABLE 5: Asymptomatic Locations Yielding False-Positive Features

Variable	No. of Ratings by Score									
	Supraaxillary (n = 18)					Axillary (n = 12)				
	1	2	3	4	5	1	2	3	4	5
CT features:										
TD	12	0	1	1		TD	2	0	3	5
AN	0	4	8	2	4	AN	3	2	2	2
FA	6	1	10			FA	1	1	9	
NC	1	0	0			NC	0	1	3	
Radiculographic features:										
DN	5	4	5	0	2	AM	5	2	1	0
NR	7	3	4	0	2	NR	1	4	3	0
"Expert opinion":										
CT	1	9	6	2		CT	0	4	8	0
RG	3	10	1	4		RG	0	4	8	0

Note.—On the rating scale, 1 is clearly normal and the highest number (3, 4, or 5, respectively) is clearly abnormal. Some features (notably NC) were often unsuitable for rating (see text). TD = decrease in transverse diameter of dural sac or in lateral extension of root sheath; AN = flattening of ventrolateral angle of dural sac or of emerging root sheath; FA = disappearance of epidural fat adjacent to dural sac or surrounding root sheath; NC = swelling of nerve root distal to site of involvement; DN = deviation or kinking of nerve root within dural sac; AM = amputation or cutoff of root-sheath filling; NR = swelling of nerve root proximal to site of involvement; RG = radiculography.

deformation of the dural sac correlating with radiculographic features known to be associated with intrathecal nerve-root compression. The cross-tabulations in Table 1 comparing isolated CT features with isolated radiculographic features show that in many cases there is grouping of scores in the top left corner of the tabulation (both techniques normal) as well as in the lower right corner (both techniques abnormal). In clinical practice these cases are not difficult. The problems arise in the intermediate gradings of the CT parameters. Radiculographic grades scatter markedly from the ideal diagonal running from top left to bottom right. Many cases are grouped in the lower left corner (CT abnormal, radiculography normal) as well as the upper right corner (CT normal, radiculography abnormal). The cases in which these discrepancies occurred were scrutinized further. In one case the disk fragment appeared to have migrated in the period between the two examinations; in one instance, nerve-root involvement was due to a bone spur, an eventuality with which the scoring system was not designed to cope. Postoperative scarring in another case provided the same problem. Classification was difficult when congenital variations such as conjoined roots were present, and inevitably scoring errors were made. The intake criteria for the study had excluded cases in which far-lateral root compression was present and radiculography was normal. In five cases with a laterally migrated fragment, however, radiculography was marginally or moderately abnormal and CT severely so. In these cases the mismatch was the result of the essentially complementary nature of the information provided by the two techniques.

Figure 9 shows an example of relatively minor CT asymmetry. However, in this case, the radiculographic aspect of the root on one side is abnormal and on the other normal. This illustrates how difficult it can be to assess whether a certain shape of the dural sac is likely to be accompanied by radiculographic signs associated with root compression.

It is possible that with a different population, a better correlation might be found between CT and radiculographic features. In the current group, the majority (94%) underwent radiculography as the first examination and CT as a confirmatory study. As discussed above, this would tend to bias the composition of the patient group toward two diagnostic categories, both unfavorable for an optimal correlation: (1) migrated disk fragments, in which radiculography underestimates the lesion, and (2) spinal narrowing, in which CT is performed to assess the dimensions of the spinal canal. In the latter case the shape of the dural sac often is hard to ascertain, especially when there is a total CSF block due to either severe narrowing or a combination of narrowing and disk lesion.

It was hoped that the expert opinion assessments, comparing a judgment formed from multiple CT features with one formed from multiple radiculographic features, would show better agreement than when isolated CT and radiculographic features were compared. This proved not to be the case, as Table 3 shows.

Further analysis of Table 3 reveals that conclusive CT verdicts are given rather more frequently in positive cases (61/140 or 44%) than in negative ones (20/63 or 32%) and with almost equal frequency in supraaxillary locations (40/95 or 42%) as compared with axillary ones (41/108 or 38%).

Table 3 can be divided horizontally into two halves: CT indicates root involvement highly or rather unlikely on the one hand (63 cases) and highly or rather likely on the other (140 cases). When root involvement is considered highly unlikely (20 of 63 cases), radiculography is clearly abnormal in only one case. When root involvement as assessed by CT seems rather unlikely (43 of 63 cases), radiculography shows no significant root abnormality in 28 cases and abnormality in 15. On the other hand, when CT indicates root involvement to be highly likely (61 of 140 cases), radiculography shows

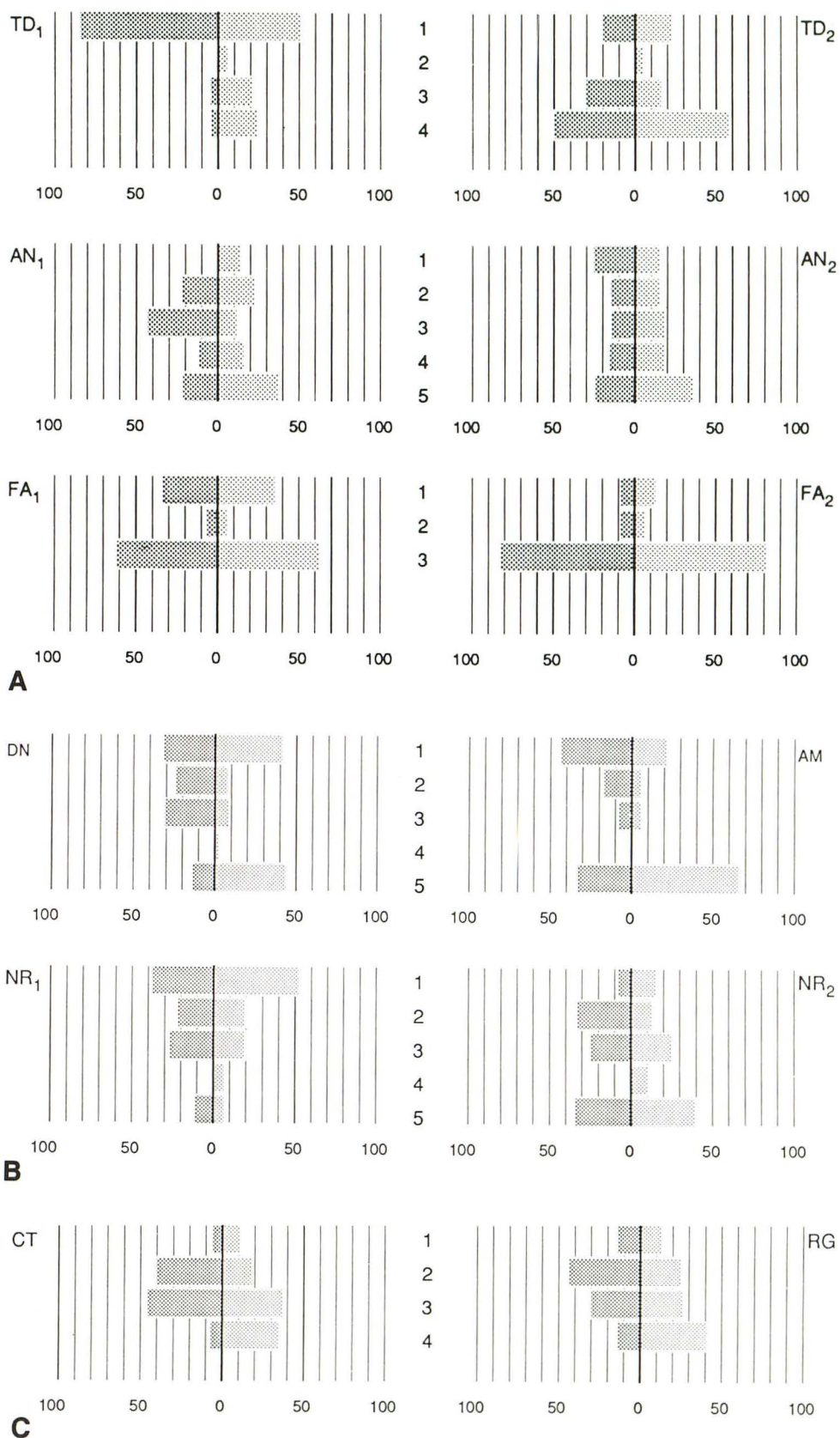
Fig. 7.—Distribution of rating grades in asymptomatic and symptomatic locations. See key for abbreviations.

A, Isolated CT features.

B, Isolated radiculographic features.

C, "Expert opinion" ratings.

Vertical columns in center of figures indicate rating grades (from clearly normal to clearly abnormal) of various features. Length of horizontal shaded bars indicates percentage of verdicts per rating grade. To facilitate comparison, distribution of percentages in asymptomatic locations is displayed adjacent to symptomatic ones (asymptomatic locations, dark-shaded bars to left of zero line; symptomatic locations, lighter-shaded bars to right). Thus, in CT features FA₁ and FA₂, for example, asymptomatic and symptomatic locations are indistinguishable, while in the "expert opinion" gradings, asymptomatic locations are generally assigned lower CT and radiculographic scores than symptomatic ones are.



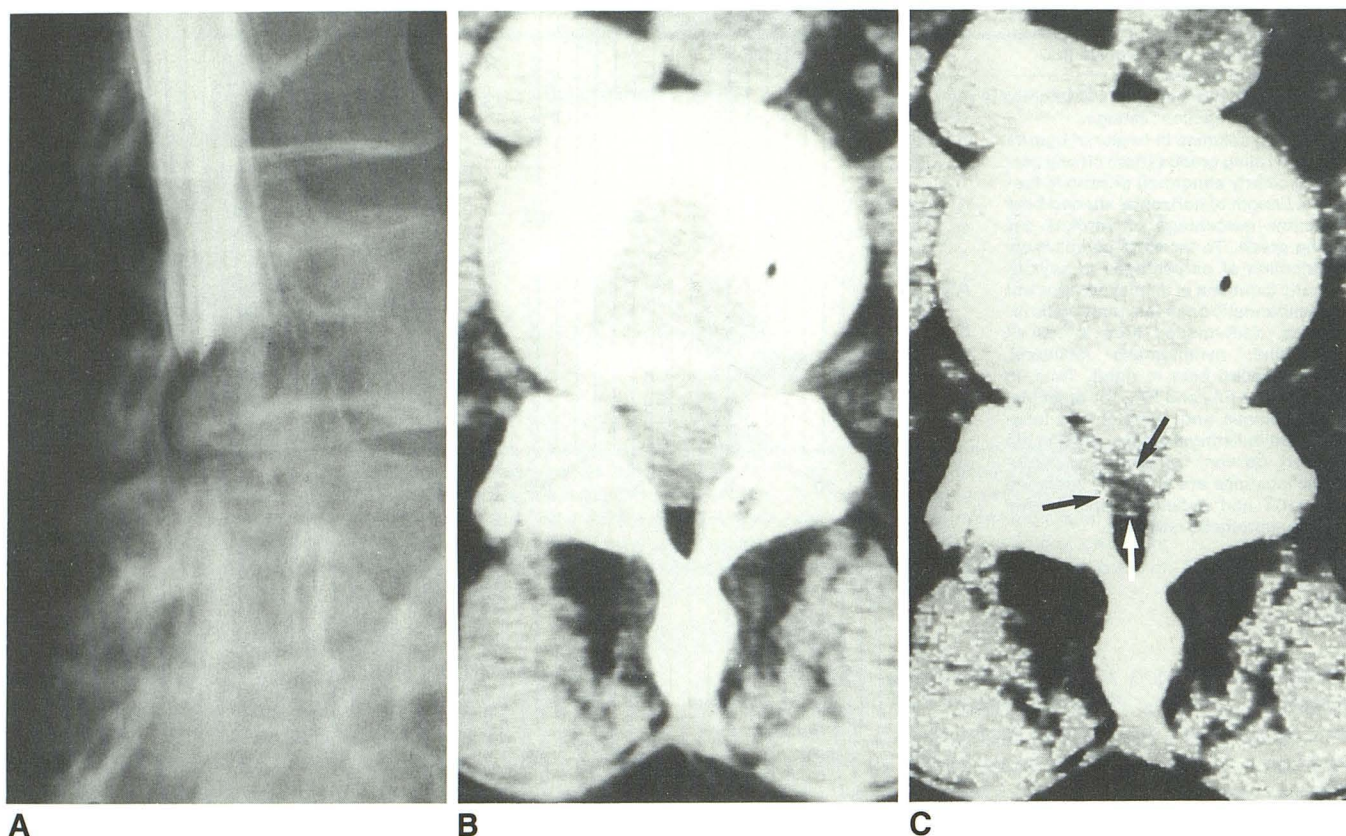


Fig. 8.—Patient with left sciatica and without right-sided symptoms.

A and B, Large L4–L5 herniation causes complete radiculographic block (A) block that may be overlooked on CT scan (B).
C, Level-detection technique can be useful in identifying collapsed dural sac (arrows).

no significant root abnormality in two cases, and when root involvement appears rather likely on the basis of CT (79 of 140), radiculography confirms this in 51 cases and repudiates it in 28. Expressing this in a different way, assessment of 203 CT locations led to a conclusive verdict in 81 cases. In three cases this verdict was erroneous. In 122 cases a verdict was given that was not conclusive. Radiculography would be considered necessary in these cases, and the radiculographic data confirmed the CT verdict in 79 cases and contradicted this verdict in 43 cases.

Intraobserver consistency (Table 4) does not differ greatly between assessment of isolated CT features and the expert opinion rating, with isolated radiculographic features performing rather less well. There is a body of literature addressing the problem of intraobserver consistency and an extensive review is given by Koran [26]. In an article on the same subject, Garland [27] remarks on how difficult it can be for an observer to accept the fact of his own inconsistency. Interobserver variability is likely to be even greater, but this aspect was not considered relevant to the theme of this study.

In this study, radiculography is implicitly regarded as the "gold standard" for establishing the presence or absence of nerve-root compression within the dural sac, as opposed to the extrathecal segment. As mentioned, CT abnormalities can

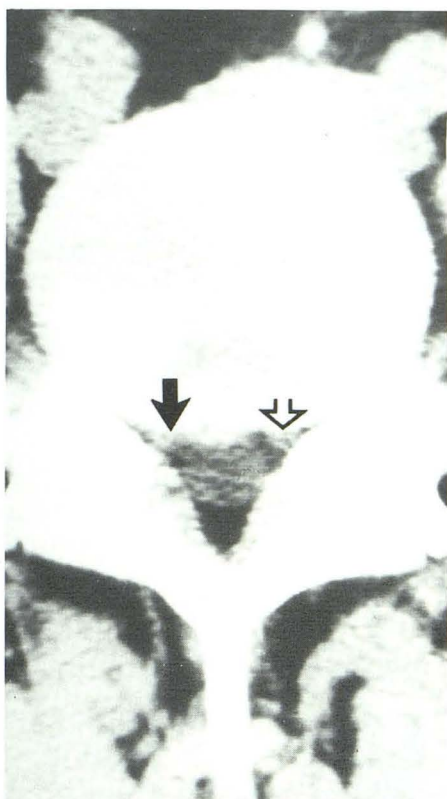
occur in a substantial percentage of individuals who are asymptomatic for low back pain or sciatica, but the same has been reported for radiculographic as well as for postmortem studies [24, 28–32]. Patients in the current study group were asked to indicate on which side they had never experienced symptoms, and 34 of 100 were able to do so, thus yielding a total of 30 locations on the asymptomatic side where abnormal radiologic features were seen. There is no proof that the remaining 173 locations were all correct positive, as radiologic signs may occur coincidentally on the symptomatic side that are etiologically unrelated to the complaints. Table 5 shows that false-positive findings occur rather more frequently above the level of emergence of the nerve root from the dural sac than at the axillary level, and Figure 7 illustrates that the severity of grading of isolated CT and radiculographic features, as well as of expert opinion assessments, in general is somewhat lower in the asymptomatic locations than in the others, with the exception of CT features FA₁ and FA₂ and radiculographic features NR₁ and NR₂. It could be said that, although asymptomatic locations can show an abnormal radiologic appearance, this appearance is likely to be less severely abnormal than that in symptomatic locations. In 25 of 30 false-positive locations there proved to be bilateral radiologic lesions with only unilateral clinical signs, and in one

Fig. 9.—Patient with right sciatica without left-sided symptoms: Almost symmetric contour of L5–S1 disk, in combination with transverse spinal narrowing due to massive facets.

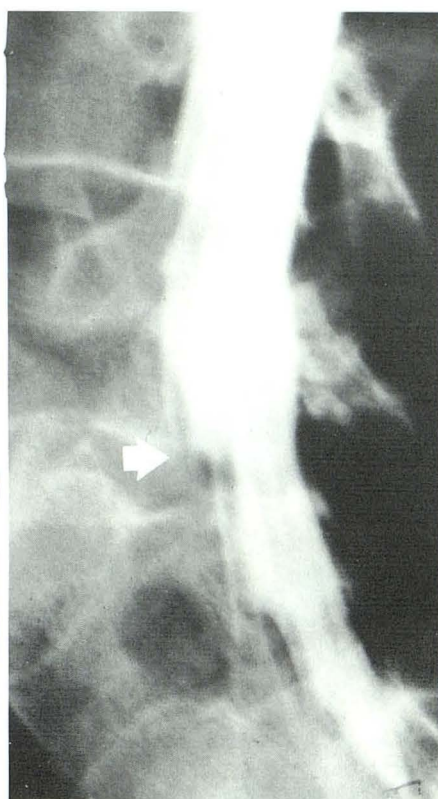A, CT scan shows slightly more flattening of right emerging S1 root (solid arrow) compared with left (open arrow).

B and C, Radiculograms show interruption of root-sheath filling on right (arrow) as compared with normal aspect of root sheath on left (open arrow).

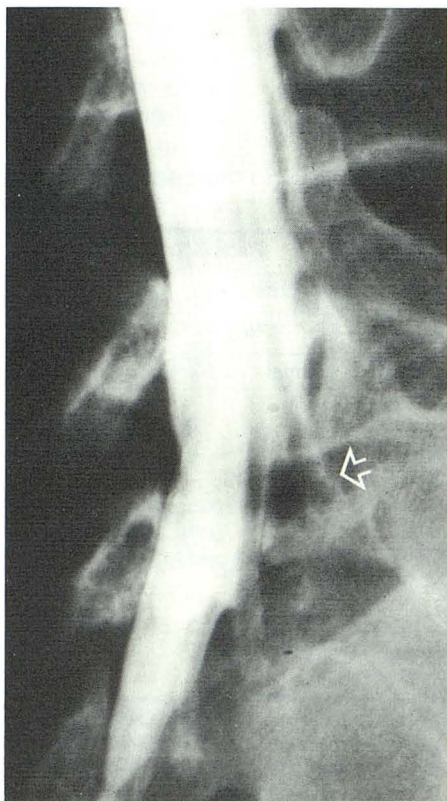
D, CT diagnosis is aided by swelling of right S1 root distal to site of compression (arrow), a CT sign that occasionally is helpful (see Table 1).



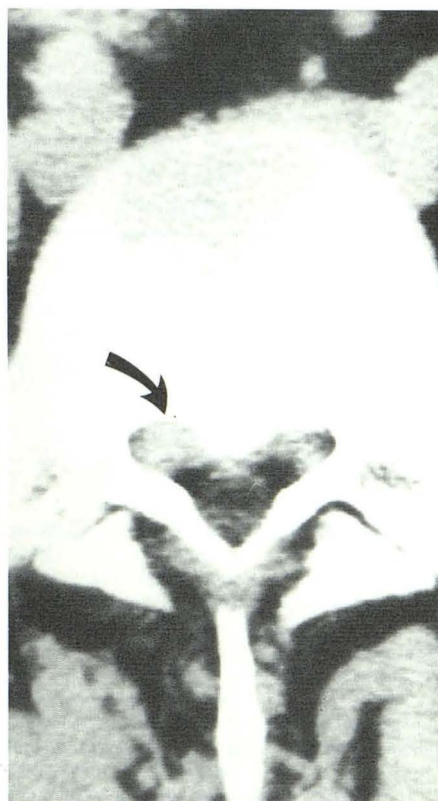
A



B



C



D

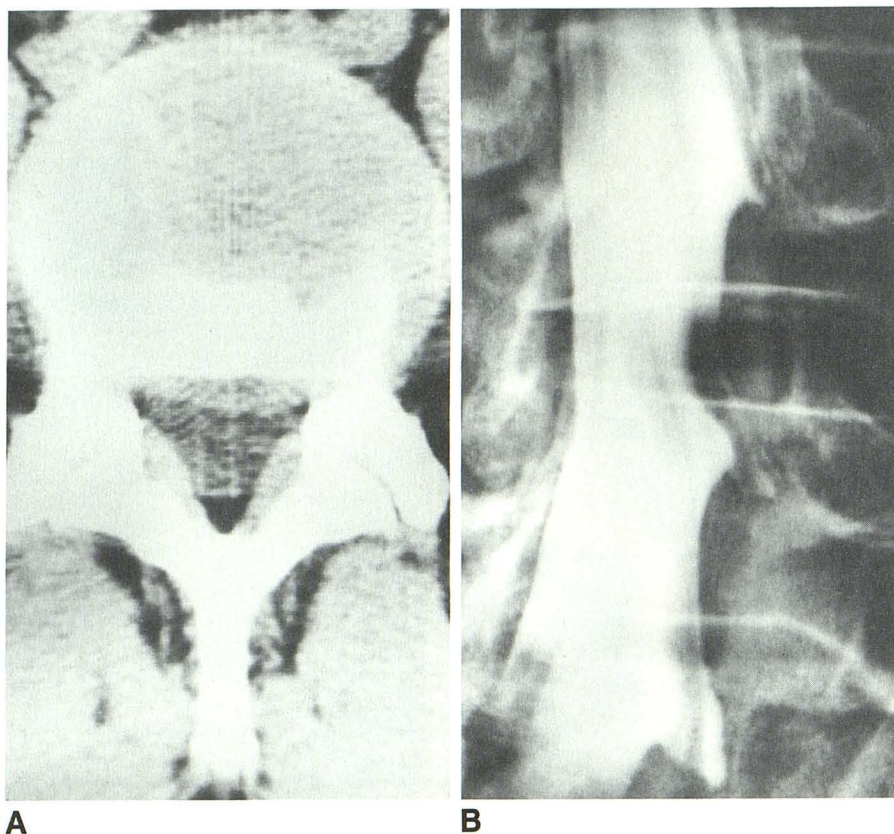


Fig. 10.—Patient with right sciatica due to L5–S1 herniation (not shown) denied left-sided symptoms.

A, CT shows mild disk protrusion at L4–L5 on left, and only minimal deformity of dural sac.

B, Radiculogram shows some inward kinking of left L5 root.

TABLE 6: CT and Radiculographic Features Cross-tabulated by Normal and Abnormal Categories

CT Features	Radiculographic Features							
	Vs TD ₁ , AN ₁ , FA ₁ (Supraaxillary)				Vs TD ₂ , AN ₂ , FA ₂ (Axillary)			
	DN		NR ₁		AM		NR ₂	
	Normal	Abnormal	Normal	Abnormal	Normal	Abnormal	Normal	Abnormal
TD:								
Normal	29	15	38	6	11	10	10	10
Abnormal	2	19	7	9	13	53	15	44
Kappa	0.49		0.43		0.31		0.23	
AN:								
Normal	26	7	27	4	18	12	15	14
Abnormal	12	34	22	17	12	56	11	51
Kappa	0.52		0.29		0.42		0.35	
FA:								
Normal	24	6	27	3	10	10	9	8
Abnormal	14	35	22	20	22	58	20	53
Kappa	0.49		0.35		0.18		0.20	

Note.—Normal categories combine images rated 1 and 2 in Table 1; abnormal categories combine images rated 3 or more in Table 1. No kappa values are shown for CT feature NC because the data were unsuitable. (See the Appendix.) TD = decrease in transverse diameter of dural sac or in lateral extension of root sheath; AN = flattening of ventrolateral angle of dural sac or of emerging root sheath; FA = disappearance of epidural fat adjacent to dural sac or surrounding root sheath; NC = swelling of nerve root distal to site of involvement; DN = deviation or kinking of nerve root within dural sac; AM = amputation or cutoff of root-sheath filling; NR = swelling of nerve root proximal to site of involvement.

case even a complete radiculographic block (Fig. 8). In the five remaining cases the false-positive radiologic findings were unilateral (Fig. 10). Four of these five cases had radiologic findings on the same side as clinical symptoms at another disk level, and in one case there were clinical symptoms exclusively present on the one side and radiologic findings exclusively on the other.

In conclusion, the expectation at the commencement of the study that it would be possible to improve the assessment by CT of the state of the intrathecal nerve root by correlating CT features with radiculographic features known to be associated with intrathecal nerve-root compression was realized only very partially. A number of reasons for this can be given, the most important being the fact that the anatomic information provided by the two techniques overlaps only partially, and is largely complementary.

In the present study CT on its own allowed a definitive expert opinion as to the presence or absence of intrathecal nerve-root compression in about 40% of 203 locations assessed. This verdict showed a positive correlation with the radiculographic findings in about 96%. In the remaining 60% of locations the CT image allowed a tentative verdict only, and confirmation as to the presence or absence of intrathecal root involvement by radiculography would be considered necessary in order to visualize the intrathecal root segment directly. The tentative CT verdict correlated much less well with the radiculographic findings, showing agreement in about 65%. Therefore, it appears that, although correlation between CT and radiculographic judgments as expressed in values of kappa are far from impressive, it is possible to select those CT scans likely to show a high degree of correlation with the radiculogram requiring no further confirmation. The intraobserver consistency in such a selection procedure amounts to 90%, which compares well with what is known from the literature on judgments of this type. Although radiculography is considered to reliably depict the state of the intrathecal nerve root, severe radiculographic signs of nerve-root involvement were found in four of 30 locations known to be asymptomatic on the basis of clinical data, and less severe but still significant signs in nine. In the same 30 locations, root involvement on the basis of CT findings was considered highly likely in two locations and rather likely in 14.

ACKNOWLEDGMENTS

I wish to thank Gerda Weltevrede for typing the numerous revisions of the manuscript, Egbert Knol for help in tabulating and evaluating the results, Leo van der Wee for methodological advice, Cees Minnis for photographic illustrations, and Douwe Buiter for diagrams.

Appendix: Statistics

Kappa (K) is a statistic variable developed by Cohen [33] to measure agreement between observations taking into account the degree of agreement by chance. A kappa value of 0 indicates that any agreement present is purely due to chance, and a value of 1 indicates perfect agreement. In practice, kappa values between 0.60 and 0.80 appear acceptable, and values below 0.40 should be

regarded with caution. It is worth stressing that a high value for kappa indicates that there is good agreement between observations, but not necessarily that these observations are correct.

In order to assess the agreement between the CT and radiculographic observations set out in Table 1, simplified two-point rating scales were used to construct the cross-tabulations seen in Table 6. The three-, four-, and five-rating scales were reduced to two points (normal and abnormal) by selecting a cutoff point between ratings 2 (questionably normal/abnormal) and 3 (abnormal). Thus, ratings 1 and 2 are called normal; ratings 3 or higher, abnormal.

The calculated values for kappa set out in Table 6 indicate an agreement between CT and radiculographic features above that due to chance, which is fair at best.

Kappa values were also calculated for agreement between expert opinion verdicts on the CT and radiculographic picture, respectively. For supraaxillary locations this value amounted to 0.43; for axillary locations, to 0.34; and for all locations, to 0.39. These values are not distinctly superior to those calculated for agreement between isolated CT and radiculographic features.

REFERENCES

- Verbiest H. A radicular syndrome from developmental narrowing of the lumbar vertebral canal. *J Bone Joint Surg [Br]* 1954;36-B:230-237
- Ehni G. Effect of certain degenerative diseases of the spine, especially spondylosis and disk protrusion, on the neural contents, particularly in the lumbar region. *Mayo Clin Proc* 1975;50:327-338
- Paine KWE, Haung PWH. Lumbar disc syndrome. *J Neurosurg* 1972;37:75-82
- Epstein BS, Epstein JA, Jones MD. Lumbar spinal stenosis. *Radiol Clin North Am* 1977;15:227-239
- Hammerschlag SB, Wolpert SM, Carter BL. Computed tomography of the spinal canal. *Radiology* 1976;121:361-367
- Sheldon JJ, Sersland T, LeBorgne J. Computed tomography of the lower lumbar vertebral columns. *Radiology* 1977;124:113-118
- Lee BCP, Kazam E, Newman AD. Computed tomography of the spine and spinal cord. *Radiology* 1978;128:95-102
- Burton CV, Heithoff KB, Kirkaldy-Willis W, Ray CD. Computed tomographic scanning and the lumbar spine: II. Clinical considerations. *Spine* 1979;4:356-368
- Verbiest H. The significance and principles of computerized axial tomography in idiopathic developmental stenosis of the bony lumbar vertebral canal. *Spine* 1979;4:369-378
- Roub LW, Drayer BP. Spinal computed tomography: limitations and applications. *AJR* 1979;133:267-273
- Ciric I, Mikhael MA, Tarkington JA, Vick NA. The lateral recess syndrome. *J Neurosurg* 1980;53:433-443
- Dorwart RH, Genant HK. Spinal stenosis. *Radiol Clin North Am* 1983;21:301-325
- Rosa M, Capellini C, Canevari MA, Prosetti D, Schiavoni S. CT in low back and sciatic pain due to lumbar canal osseous changes. *Neuroradiology* 1986;28:237-240
- Penning L, Wilmink JT. Posture dependent bilateral compression of L4 or L5 nerve roots in facet hypertrophy: A dynamic CT-myelographic study. *Spine* 1987;12:488-500
- Haughton VM, Eldevik OP, Magnaes B, et al. A prospective comparison of computed tomography and myelography in the diagnosis of herniated lumbar discs. *Radiology* 1982;142:103-110
- Raskin SP, Keating JW. Recognition of lumbar disk disease: comparison of myelography and computed tomography. *AJNR* 1982;3:215-221, *AJR* 1982;139:349-355
- Moufarrij NA, Hardy RW Jr, Weinstein MA. Computed tomographic, myelographic, and operative findings in patients with suspected herniated lumbar discs. *Neurosurgery* 1983;12:184-188
- Teplick JG, Haskins ME. CT and lumbar disc herniation. *Radiol Clin North Am* 1983;21:259-288
- Bell GR, Rothman RH, Booth RE, et al. A study of computer-assisted

- tomography. II. Comparison of metrizamide myelography and computed tomography in the diagnosis of herniated lumbar disc and spinal stenosis. *Spine* **1984**;9:552-556
20. Schipper J, Kardaun JWPF, Braakman R, van Dongen KJ, Blaauw G. lumbar disk herniation: diagnosis with CT or myelography? *Radiology* **1987**;165:227-231
21. Williams AL, Haughton WVM, Syvertsen A. Computed tomography in the diagnosis of herniated nucleus pulposus. *Neuroradiology* **1980**;135:95-99
22. Anand AK, Lee BCP. Plain and metrizamide CT of lumbar disk disease: comparison with myelography. *AJNR* **1982**;3:567-571
23. Fries JW, Abodeely DA, Vijungco JG, Yeager VL, Gaffey WR. Computed tomography of herniated and extruded nucleus pulposus. *J Comput Assist Tomogr* **1982**;6(5):874-887
24. Wiesel SW, Tsourmas N, Feffer HL, Citrin CM, Patronas N. A study of computer assisted tomography. I. The incidence of positive CAT scans in an asymptomatic group of patients. *Spine* **1984**;9:549-551
25. Abdullah AF, Ditto EW, Byrd EB, Williams R. Extreme-lateral lumbar disc herniations. *J Neurosurg* **1974**;41:229-234
26. Koran LM. The reliability of clinical methods, data and judgements. *N Engl J Med* **1975**;293:642-646, 695-701
27. Garland LH. Studies on the accuracy of diagnostic procedures. *AJR* **1959**;82:25-38
28. Falconer MA, McGeorge M, Begg AC. Observations on the cause and mechanism of symptom-production in sciatica and low-back pain. *J Neurol Neurosurg Psychiatry* **1948**;11:13-26
29. McRae DL. Asymptomatic intervertebral disc protrusions. *Acta Radiol (Stockh)* **1956**;46:9-27
30. Hamer J. Asymptomatic protrusions and prolapses of lumbar intervertebral discs. A post-mortem myelographic study of 50 cases. International Congress Series no. 287. *Mod Aspects Neurosurg* **1971**;3:80-82
31. Hitselberger WE, Witten RM. Abnormal myelograms in asymptomatic patients. *J Neurosurg* **1968**;28:204-206
32. Wilberger JW, Pang D. Syndrome of the incidental herniated lumbar disc. *J Neurosurg* **1983**;59:137-141
33. Cohen J. A coefficient for agreement for normal scales. *Educ Psychol Meas* **1960**;20:37-46

The reader's attention is directed to the Editorial "Radiologic Aspects of Low Back Pain and Sciatic Syndromes" on page 451 of this issue.