



## **Transvenous embolization of dural fistulas involving the cavernous sinus.**

V V Halbach, R T Higashida, G B Hieshima, C W Hardin and H Pribram

*AJNR Am J Neuroradiol* 1989, 10 (2) 377-383

<http://www.ajnr.org/content/10/2/377>

This information is current as of July 3, 2025.

# Transvenous Embolization of Dural Fistulas Involving the Cavernous Sinus

Van V. Halbach<sup>1</sup>  
 Randall T. Higashida<sup>1</sup>  
 Grant B. Hieshima<sup>1</sup>  
 Carl W. Hardin<sup>1</sup>  
 Henry Pribram<sup>2</sup>

Because of the risks associated with arterial embolization of cavernous dural fistulas, we have sought an alternative method to promote fistula closure. Thirteen patients underwent transvenous embolization as a treatment for symptomatic cavernous dural fistulas. All procedures were performed from a femoral vein access through the inferior petrosal sinus or basilar plexus. In five patients the inferior petrosal sinus was not angiographically demonstrable; however, embolization was still possible through this route in two patients. The embolic agents used were detachable balloons in one patient, coils alone in five, coils and liquid adhesives in four, coils plus silk sutures in one, silk sutures alone in one, and liquid adhesives alone in one. Nine patients had follow-up angiograms, which showed complete obliteration of the fistulas and complete resolution of related symptoms. One patient had complete resolution of clinical symptoms but refused follow-up angiography. Another patient had 50% decrease in fistula flow on the follow-up angiogram and improvement in clinical symptoms. Two patients had complete fistula obliteration after embolization and progressive improvement in symptoms but follow-up angiograms had not been obtained. Follow-ups ranged from 1 to 97 months (mean, 15 months). Two complications were related to this treatment. An embolic stroke followed transient placement of a balloon in the internal carotid in one patient, and a second patient developed transient visual loss when the venous outflow pathways were occluded before fistula closure. The fistula was immediately closed with complete recovery of vision.

With recent advances in microcatheter and embolic agent technology, transvenous closure of cavernous dural fistulas is now possible. We use this method as the primary treatment of symptomatic cavernous dural fistulas requiring treatment.

Dural arteriovenous fistulas (AVFs) are rare, accounting for 10–15% of all intracranial malformations [1]. Fistulas involving the cavernous sinus region occur most often in elderly women [2] and frequently present with chemosis, proptosis, and ophthalmoplegia. Visual loss can result, especially if thrombosis of venous outflow pathways has occurred [3]. Surgical approaches to the cavernous dural AVFs have involved placement of thrombogenic material into the sinus to promote thrombosis and closure [4, 5]. More recently, transarterial embolization has evolved as an effective therapy [6–8]. Some patients who have undergone prior surgical ligations and proximal embolizations, or who have anatomic variations, may not have safe arterial pathways for transarterial embolization. Compression therapy has been described as an effective treatment in selected patients [9, 10]; however, clinical symptoms may mandate more aggressive forms of therapy [11]. We have devised an alternative treatment for patients with symptomatic cavernous dural AVFs. This technique involves the placement of thrombogenic material within the cavernous sinus from a transvenous approach to promote thrombosis and closure of the fistula. This article describes the technique, results, and complications in 13 patients treated by this technique.

Received February 17, 1988; accepted after revision May 26, 1988.

<sup>1</sup> Department of Radiology, Neurointerventional Radiology Section, L352, University of California, San Francisco, Hospitals, 505 Parnassus Ave., San Francisco, CA 94143. Address reprint requests to V. V. Halbach.

<sup>2</sup> Department of Radiology, University of California, Irvine, Medical Center, Irvine, CA 92668.

**AJNR 10:377–383, March/April 1989**  
 0195–6108/89/1002–0377

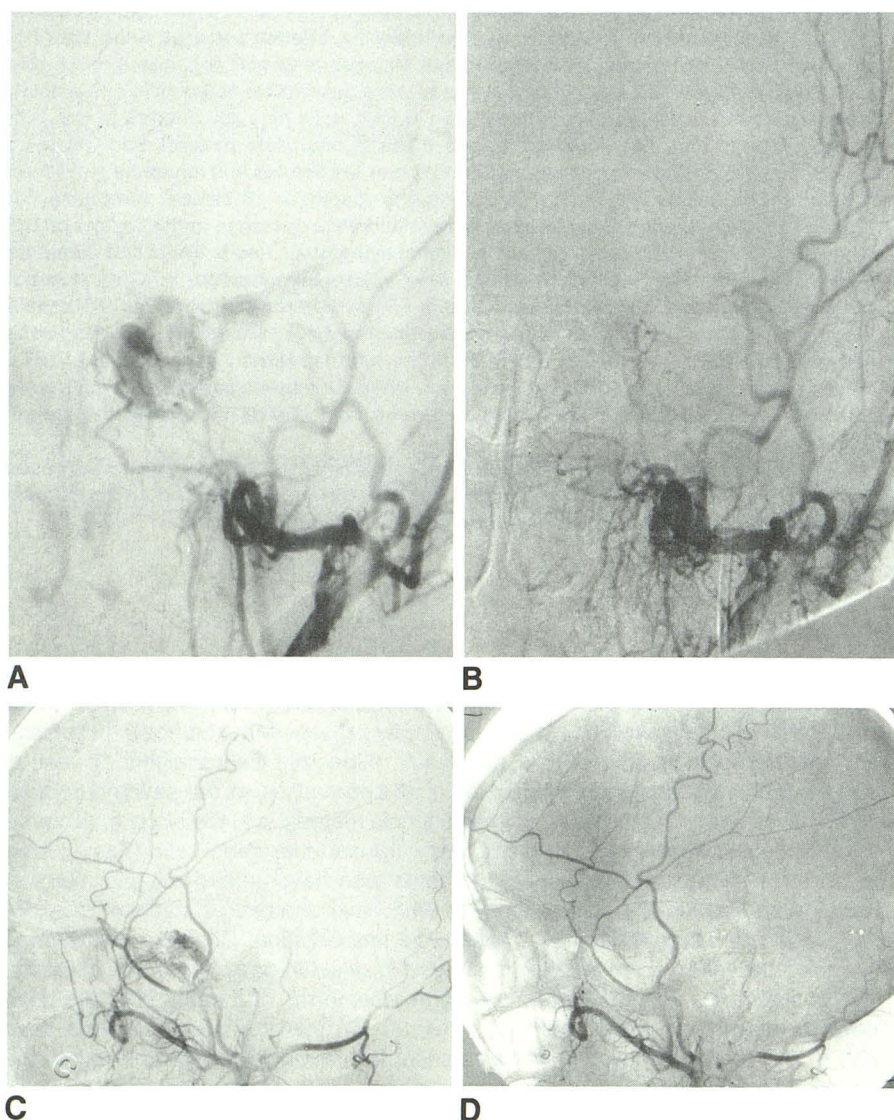
© American Society of Neuroradiology



**TABLE 1: Summary of Cavernous Dural Arteriovenous Fistulas Treated by Transvenous Embolization**

Case No.	Age	Gender	Supply	Location	Venous Access	Embolic Agent	Outcome	Follow-up (months)
1	68	F	L internal & external carotid	L	R IPS	Balloon	Cure	97
2	19	F	L internal & external carotid	L	L IPS	IBCA	Cure	28
3	62	M	L & R internal & external carotid	L & R	L & R IPS	Coils	Cure	13
4	68	F	L & R internal & external carotid	L	L IPS	Coils	50% obliterated	12
5	72	F	L internal & external carotid	L	L IPS	Coils + IBCA	Cure	12
6	61	F	L & R internal & external carotid	L	R IPS	Coils + IBCA	Clinical cure	11
7	51	F	L & R internal & external carotid	L	L & R IPS	Coils + IBCA	Cure	7
8	62	M	L & R internal & external carotid	L	L IPS	Coils, 0.025 in. (0.064 cm)	Cure	6
9	32	M	R internal & external carotid	R	R IPS	Coils	Cure	5
10	66	F	L & R internal & external carotid	L	L IPS	Silk	Cure	3
11	44	M	L external carotid	L	L IPS	Coils & silk	Clinical improvement	3
12	53	M	L & R internal carotid; L external carotid	L	L IPS	Coils	Cure	2
13	83	F	L & R internal & external carotid	L & R	R IPS	Coils & IBCA	Clinical improvement	1

Note.—Complications occurred in only two patients: embolic stroke in case 5 and transient visual loss in case 6. R = right; L = left; IPS = inferior petrosal sinus; IBCA = isobutyl 2-cyanoacrylate.



**Fig. 1.—Case 8: 62-year-old man with pain, proptosis, and bruit.**

**A,** Left external carotid injection, anteroposterior view, shows supply to left cavernous dural fistula.

**B,** Same vessel after coil embolization from inferior petrosal route shows obliteration of fistula.

**C,** Right external carotid injection, lateral view, shows supply to same fistula.

**D,** Same vessel after embolization shows obliteration of supply. (Fig. 1 legend is continued on the opposite page.)



## Materials and Methods

The patients' age, gender, fistula location, arterial supply, venous access, embolic agents, outcome, follow-up, and complications are summarized in Table 1. Symptoms that prompted treatment were pain (10 patients), chemosis (nine patients), proptosis (eight patients), bruit (eight patients), ophthalmoplegia (five patients), and severe visual loss (two patients). Thirteen patients with dural AVFs involving the cavernous sinus were treated by transvenous embolization. The procedure was performed from a femoral vein access in all patients. A 7-French catheter was navigated to the origin of the inferior petrosal sinus draining the fistula. In five patients (cases 1, 6, 7, 9, and 10), an inferior petrosal sinus on the ipsilateral side was not angiographically demonstrable by arterial angiography. In two cases (cases 6 and 10), a pathway through the thrombosed sinus could be found by gentle manipulation with the guidewire and catheter. In case 9, a small catheter was navigated up the basilar clival plexus for the initial embolization. Two subsequent embolization procedures involved crossing the midline through a transsellar vein to reach the involved sinus. This contralateral approach was used in cases 1, 6, 7, and 13.

Eleven patients underwent a single embolization procedure, one patient had two procedures (case 5), and one patient had three procedures (case 7). Three patients (cases 3, 5, 7, and 12) had prior transarterial embolization without improvement. Case 8 had a contralateral dural fistula treated by liquid adhesives 3 years previously. In case 1 a balloon was navigated from a contralateral approach across the midline and inflated to produce fistula occlusion. The remaining 12 cases had small catheters placed coaxially through a 7-French catheter into the inferior petrosal sinus or jugular bulb. All 13 patients underwent complete angiography to elucidate the fistula site and supply. In cases 6–13, catheters were positioned in the external carotid artery to help delineate the venous pathways with roadmapping techniques.\* Roadmapping was not available or not needed in the earlier cases. The external carotid was chosen for roadmapping because of the increased safety of leaving a catheter on perfusion drip between injections vs placement in the internal carotid artery. In cases 2, 7, and 8, a 3-French Teflon catheter† was placed

\* Diansonics, Inc., Salt Lake City, UT.

† Cook, Inc., Bloomington, IN.

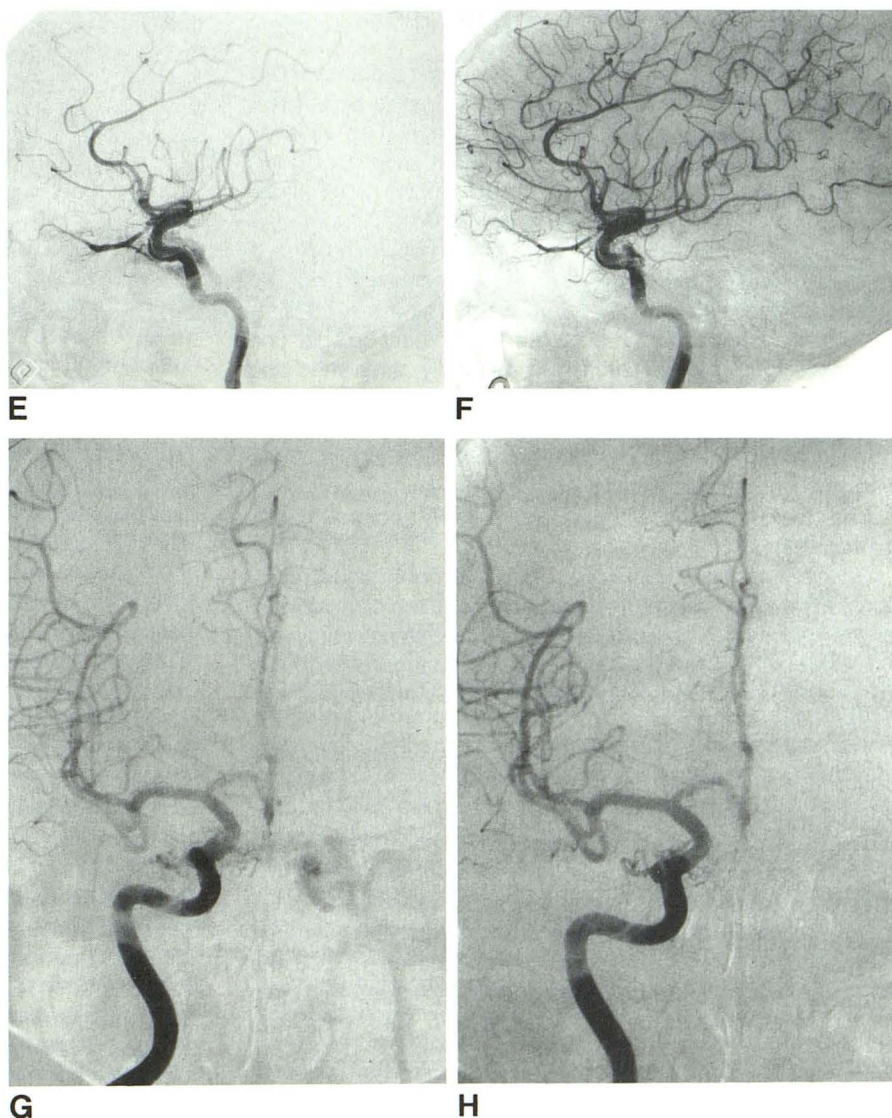


Fig. 1.—(Continued.)

E, Left internal carotid injection, lateral view, shows supply to left dural fistula.

F, Same vessel after embolization shows occlusion of fistula. Feeding arteries still opacify without shunting to vein.

G, Right internal carotid injection, anteroposterior projection shows supply to left cavernous fistula.

H, Same vessel after embolization shows occlusion of supply.



into the cavernous sinus and liquid adhesives or 0.025-in. (0.064 cm) Gianturco minicoils were deposited (Cook, Inc.). In cases 3–7 and 11–13, gold or platinum coils<sup>†</sup> ranging in diameter from 0.010 to 0.018 in. (0.025 to 0.046 cm), were placed through a 3-French Tracker catheter. Isobutyl 2-cyanoacrylate<sup>‡</sup> was used additionally in cases 5–7 and 13 and silk suture (4-0 size) in case 11. In case 10, multiple pieces of silk suture (4-0 size) were injected into the fistula site as the only embolic agent. In case 9, a 4.2-French Tracker catheter (Target Therapeutics) was used to place 0.025-in. (0.064-cm) minicoils into the fistula site.

During the injection of liquid adhesives in case 5, a balloon was positioned transiently in the internal carotid artery to prevent reflux of embolic material through the cavernous dural collaterals. Reflux into the carotid artery was noted on contrast injection of the cavernous sinus in this case only.

Follow-up angiograms were obtained in nine patients, refused in two, and have not yet been performed in two. The patients were followed clinically with ophthalmologic and neurologic examinations at 3- and 6-month intervals. Cure was defined as complete angiographic obliteration and total resolution of signs and symptoms related to the fistula.

## Results

Thirteen patients underwent a total of 17 transvenous embolization procedures. Complete angiographic and clinical cure was achieved in nine patients. Case 8 (Fig. 1) is an example of a dural fistula located in the left cavernous sinus with bilateral internal and external carotid supply. After placement of coils into the fistula site alone, complete thrombosis was achieved. In case 6, the patient had complete resolution of clinical symptoms but refused a follow-up angiogram. In case 4, the postembolization angiogram showed a 50% reduction in fistula flow. The patient's ophthalmoplegia and chemosis resolved. Her bruit was markedly diminished and she refused follow-up angiography. Two patients had complete fistula obliteration, as shown on postembolization angiograms, and marked improvement in their clinical symptoms but have not yet had a follow-up angiogram.

The follow-up period ranged from 1 to 97 months (mean, 15 months).

Despite placing material into the cavernous sinus (coils, liquid adhesives, silk sutures, and balloons), the development or the aggravation of cranial nerve palsies was not observed. For example, in case 9 (Fig. 2), the patient's third and sixth nerve palsies resolved despite placing 28 Gianturco coils into the involved sinus.

Two complications were related to transvenous embolization. In the first patient (case 5) coils were placed transvenously into the involved cavernous sinus. Her symptoms improved, but a follow-up angiogram 3 days later demonstrated residual fistula. A small catheter was negotiated into the cavernous sinus. When contrast material was injected, reflux into the carotid artery was observed through the cavernous dural feeders. To prevent reflux of embolic agent into the carotid, a balloon was positioned transiently across the origin of the dural branches of the carotid artery. The fistula was

then obliterated with a small injection of liquid adhesives. Despite anticoagulation with systemic heparin, the patient developed aphasia after deflation of the balloon, presumably from thrombus formation. The patient subsequently improved and has a mild receptive aphasia.

The second complication occurred in case 6, a patient with bilateral fistulas and severe venous occlusive disease (Figs. 3E and 3F). The catheter was advanced into the left cavernous sinus (Fig. 3D), and coil emboli were placed within the right cavernous sinus. Coils were then placed into the left cavernous sinus, at which time the patient developed severe left orbital pain, increased intraocular pressure (>40 mm Hg), and rapidly declining vision to the point of light perception only. A small amount of liquid adhesive was immediately injected, obliterating the remaining fistula. The patient's pain resolved, the intraocular pressure diminished, and the patient's vision returned to baseline. The mechanism for this acute emergency was related to aggravation of venous occlusive disease. Although the patient had bilateral fistulas, the majority of the fistula was located on the left side with the primary venous drainage to the right cavernous sinus (Figs. 3B and 3C). After closure of the right cavernous fistula and this critical venous drainage pathway, the remaining left cavernous sinus venous pressure rose to dangerous levels, resulting in severe ocular symptoms.

## Discussion

Symptomatic cavernous fistulas can be treated with a number of techniques. Compression therapy has been shown to be effective in selected patients [9, 10]. Transarterial embolization has emerged as a safe and effective treatment [6, 7]; however, in some patients hemodynamic constraints (prior embolization, ligation, vascular anomalies) may increase supply from internal carotid dural branches. Although embolization of these branches can be performed [8], the risk of embolic reflux and stroke makes this pathway less desirable. Transvenous embolization of direct cavernous fistulas has been shown to be effective [12–14]. Surgical procedures have been devised to place copper wires or thrombogenic material within the cavernous sinus to promote thrombosis [4, 5], but complications of cranial nerve injury have been reported [15]. Transvenous embolizations of dural fistulas have been described from a superior ophthalmic approach [16]. Our experience with the treatment of direct fistulas has taught us several disadvantages of this anterior venous approach. The superior ophthalmic vein can have an abrupt angulation and narrowing where it exits the superior orbital fissure [17, 18], making retrograde catheterization difficult. If the superior ophthalmic vein is injured, retroorbital hemorrhage can occur or venous drainage can be directed into intracranial pathways, increasing the risks of neurologic complications [3, 7]. Generally, the catheterization of the superior ophthalmic vein requires operative exposure. Although transvenous catheterization of the inferior petrosal vein may cause subarachnoid bleeding if ruptured [14], advances in guidewire and catheter technology have markedly reduced this risk. In

<sup>†</sup> Target Therapeutics, Mountain View, CA.

<sup>‡</sup> Ethicon, Inc., Somerville, NJ.



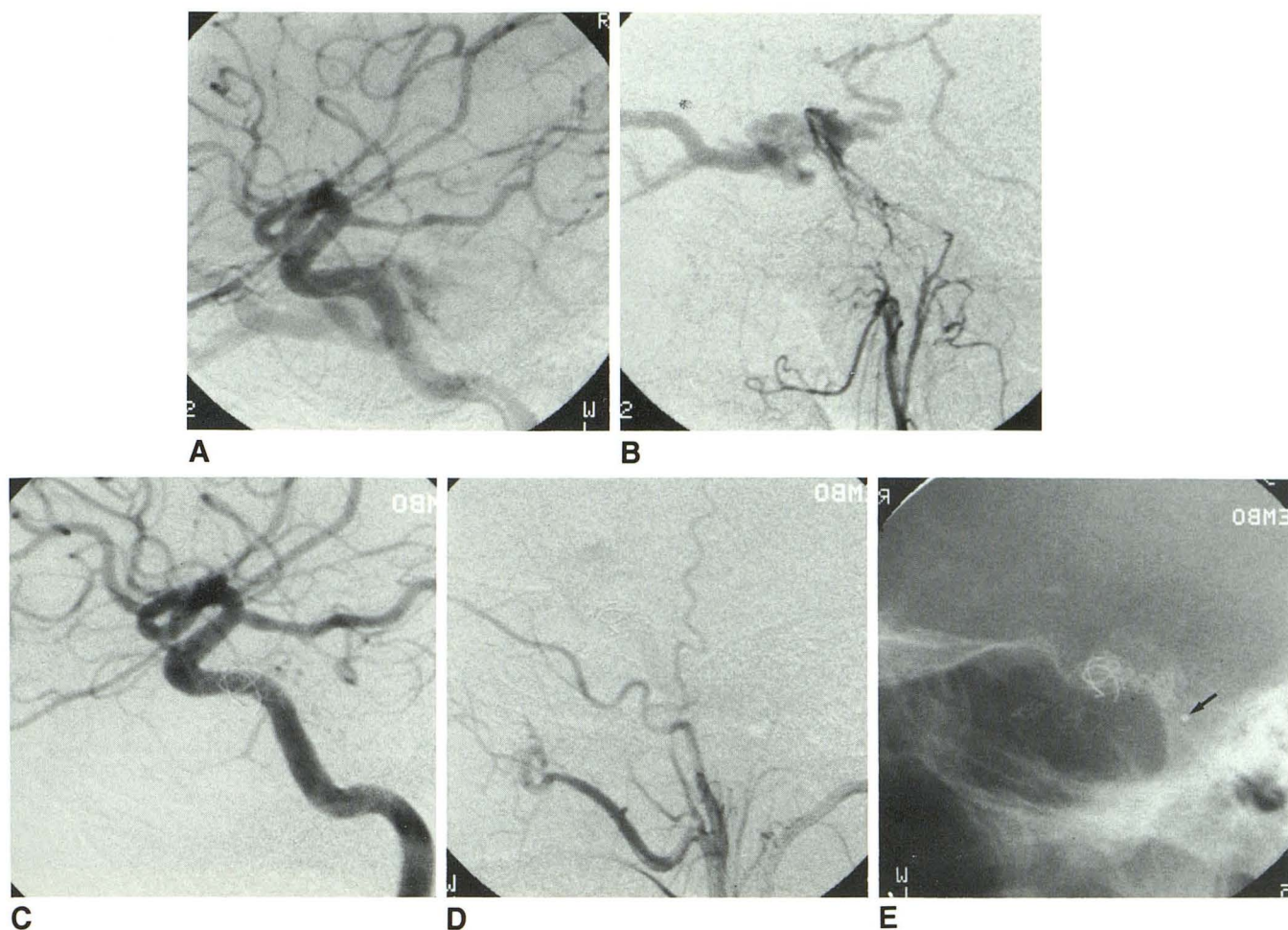


Fig. 2.—Case 9: 32-year-old man with right proptosis, chemosis, and third and sixth nerve palsies secondary to cavernous dural fistula.  
 A, Right internal carotid angiogram, lateral view, shows cavernous dural fistula supplied by internal carotid artery.  
 B, Right ascending pharyngeal injection, lateral view, shows supply from neuromeningeal branch (hypoglossal and jugular divisions) coursing toward cavernous dural fistula. Note cortical venous drainage; inferior petrosal sinus is not identified.  
 C, Right internal carotid angiogram after coil embolization from inferior petrosal route shows obliteration of fistula.  
 D, Right external carotid angiogram after embolization shows complete occlusion of fistula.  
 E, Plain lateral skull film shows 28 Gianturco coils in cavernous sinus. Tracker catheter tip (arrow).

two patients in this series, an inferior petrosal sinus was not angiographically demonstrable by arterial angiography (Fig. 3C); however, catheterization was possible in both instances. Balloons, coils, and liquid adhesives were used as embolic agents in our series. Balloons are the least attractive, requiring large-diameter catheters (and venous pathways) to facilitate placement. Although effective in our earliest case, we prefer to use coils, silk sutures, or liquid adhesives for most cavernous dural fistulas. Coils are an attractive embolic agent. Their thrombogenicity and opacity aid in accurate deposition within the cavernous sinus. Unlike liquid adhesives, coils, if properly sized, will not migrate to undesired sites. Silk sutures can be delivered through small catheters; they are highly thrombogenic but difficult to opacify, making accurate localization difficult. Liquid adhesives have an advantage over balloons, silk sutures, and coils in their ability to permeate small inter-

stices within the cavernous sinus. However, they can flow into unwanted venous pathways or retrograde through arterial feeders into the carotid artery. With all embolic agents, care must be taken to occlude the fistula site. Aggravation of symptoms after occlusion of venous pathways is well described [19] and undoubtedly the source of the transient complications in case 6. Recognition of this potentially devastating occurrence is important; an accurate delineation of the fistula site is critical for successful treatment. Great care must be maintained with this treatment to place the embolic agent within the site of the fistula while preserving the venous drainage pathways.

Both Houser et al. [20] and Chaudhary et al. [21] have presented evidence that some dural fistulas are a result of dural sinus thrombosis with subsequent recanalization resulting in an arteriovenous connection. It is ironic that some



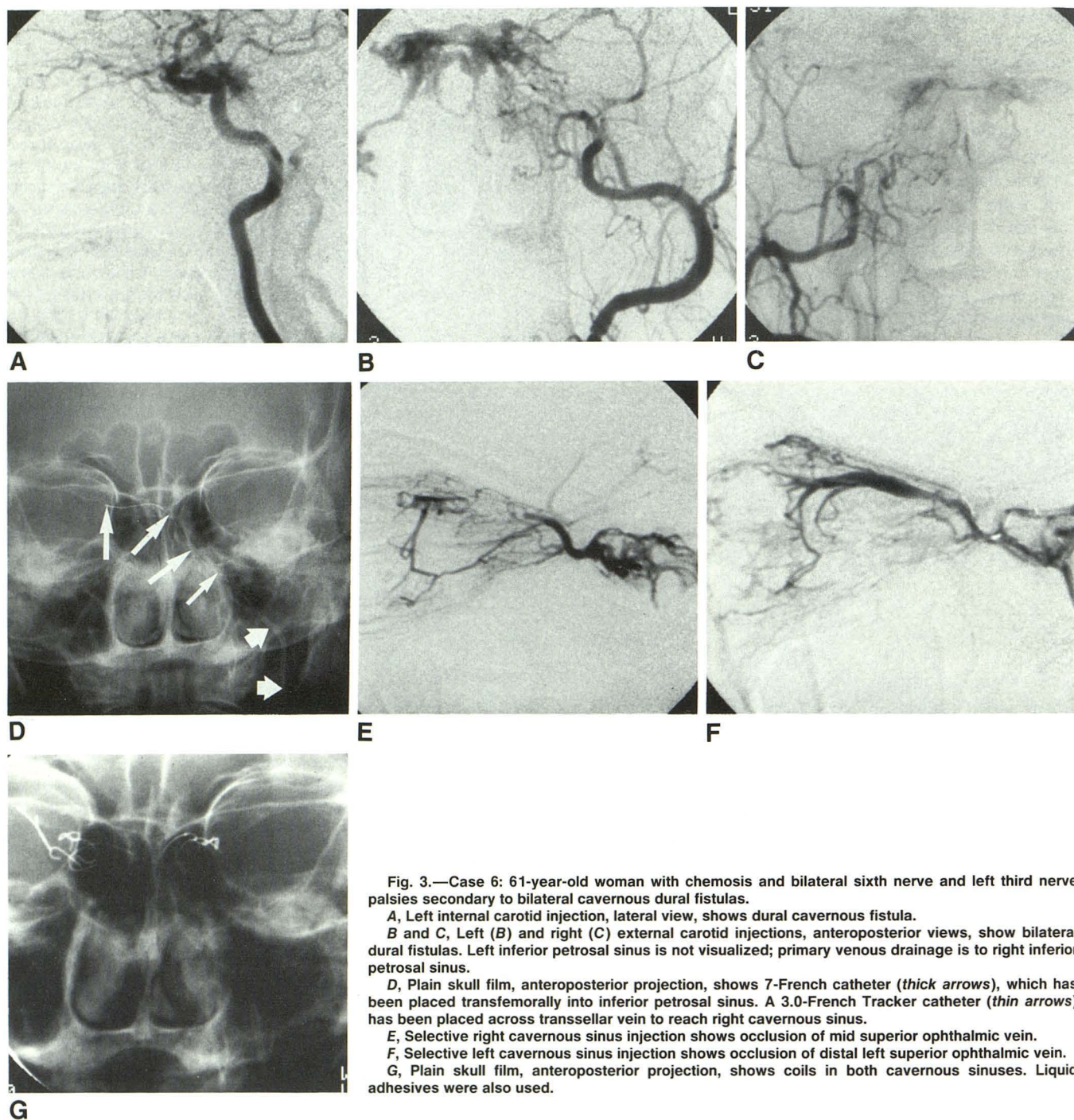


Fig. 3.—Case 6: 61-year-old woman with chemosis and bilateral sixth nerve and left third nerve palsies secondary to bilateral cavernous dural fistulas.

A, Left internal carotid injection, lateral view, shows dural cavernous fistula.

B and C, Left (B) and right (C) external carotid injections, anteroposterior views, show bilateral dural fistulas. Left inferior petrosal sinus is not visualized; primary venous drainage is to right inferior petrosal sinus.

D, Plain skull film, anteroposterior projection, shows 7-French catheter (thick arrows), which has been placed transforamally into inferior petrosal sinus. A 3.0-French Tracker catheter (thin arrows) has been placed across transsellar vein to reach right cavernous sinus.

E, Selective right cavernous sinus injection shows occlusion of mid superior ophthalmic vein.

F, Selective left cavernous sinus injection shows occlusion of distal left superior ophthalmic vein.

G, Plain skull film, anteroposterior projection, shows coils in both cavernous sinuses. Liquid adhesives were also used.

treatments involve rethrombosis of the involved sinus. The use of a permanent embolic agent is important to prevent recanalization of the fistula.

Dural AVFs can present with a wide variety of signs and symptoms including headaches, proptosis, ophthalmoplegia, chemosis, bruit, and visual loss. The decision to treat an individual patient must take into account the natural history of the disease and the potential risks and benefits of a

therapeutic method. We currently place all eligible patients on compression therapy [9, 10] as their initial treatment technique. In patients who fail or are excluded from compression therapy and have signs or symptoms that justify the risk of treatment, we now prefer to perform a transvenous rather than transarterial embolization.

The results of our series suggest that transvenous occlusion of dural cavernous fistulas is an effective treatment.

Long-term follow-up and comparison with more established treatment methods are important to determine the role of this treatment. Continued advances in microcatheters and embolic agents should improve the efficacy and reduce the complications.

## REFERENCES

1. Newton TH, Cronqvist S. Involvement of the dural arteries in intracranial arteriovenous malformations. *Radiology* **1969**;93:1071-1078
2. Newton TH, Hoyt WF. Dural arteriovenous shunts in the region of the cavernous sinus. *Neuroradiology* **1970**;1:71-81
3. Lasjaunias P, Ming C, Brugge KT, Atul T. Neurological manifestations of intracranial dural arteriovenous malformations. *J Neurosurg* **1986**;64:724-730
4. Mullan S. Experiences with surgical thrombosis of intracranial berry aneurysms and carotid cavernous fistulas. *J Neurosurg* **1974**;41:657-670
5. Hosobuchi Y. Electrothrombosis of carotid cavernous fistula. *J Neurosurg* **1975**;42:76-85
6. Lasjaunias P, Halimi P, Lepez-Ibor L, Sichez JP, Hurth M, Tribollet ND. Traitement endovasculaire des malformation vasculaires dures (MVD) pures spontanees. *Neurochirurgie* **1983**;30:207-223
7. Vinuela F, Fox AJ, Debrun GM, Peerless SJ, Drake CG. Spontaneous carotid-cavernous fistulas: clinical, radiological, and therapeutic considerations. *J Neurosurg* **1984**;60:976-984
8. Halbach VV, Higashida RT, Hieshima GB, Hardin C. Embolization of branches arising from the cavernous portion of the internal carotid artery. *AJNR* **1989**;10:143-150
9. Higashida RT, Hieshima GB, Halbach VV, Bentson JR, Goto K. Closure of carotid cavernous sinus fistulae by external compression of the carotid artery and jugular vein. *Acta Radiol [Suppl]* (Stockh) **1986**;369:580-583
10. Halbach VV, Higashida RT, Hieshima GB, Reicher M, Norman D, Newton TH. Treatment of dural fistulae involving the cavernous sinus: results in 30 patients. *Radiology* **1987**;163:443-447
11. Halbach VV, Hieshima GB, Higashida RT, Reicher M. Carotid cavernous fistula: indications for urgent therapy. *AJNR* **1987**;8:627-633, *AJR* **1987**;149:587-593
12. Manelfe C, Berenstein A. Treatment of carotid cavernous fistulas by venous approach. *J Neuroradiol* **1980**;7:13-21
13. Debrun G, Lacour P, Vinuela F, Fox A, Drake CG, Caron JP. Treatment of 54 traumatic carotid-cavernous fistulas. *J Neurosurg* **1981**;55:678-692
14. Halbach VV, Higashida RT, Hieshima GB, Hardin C, Yang P. Transvenous embolization of direct carotid cavernous fistulas. *AJNR* (in press)
15. Mullan S. Treatment of carotid cavernous fistulas by cavernous sinus occlusion. *J Neurosurg* **1979**;50:131-144
16. Labbe D, Courtheoux P, Rigot-Jolivet M, Compere JF, Theron J. Bilateral dural carotid-cavernous fistula. Its treatment by way of the superior ophthalmic vein. *Rev Stomatol Chir Maxillofac* **1987**;88(2):120-124
17. Wolff E. *The anatomy of the eye and orbit including the central connections, development, and comparative anatomy of visual apparatus*. London: Lewis, **1954**
18. Hanafey WN, Rosen L, Weidner W, Wilson GH. Venography of the cavernous sinus, orbital veins and the basal venous plexus. *Radiology* **1965**;84:751-753
19. Inagawa T, Yano T, Kamiya K. Acute aggravation of traumatic carotid-cavernous fistula after venography through the inferior petrosal sinus. *Surg Neurol* **1986**;26(4):383-386
20. Houser OW, Cambell JK, Sundt TM. Arteriovenous malformations affecting the transverse dural venous sinus: an acquired lesion. *Mayo Clin Proc* **1979**;54:651-661
21. Chaudhary MY, Sachdev VP, Cho SH, Weitzer I, Puljic S, Huang YP. Dural arteriovenous malformation of the major venous sinuses: an acquired lesion. *AJNR* **1982**;3:13-19