

Generic Contrast Agents

Our portfolio is growing to serve you better. Now you have a *choice*.



FRESENIUS
KABI

[VIEW CATALOG](#)

AJNR

Production of experimental aneurysms at a surgically created arterial bifurcation.

M D Forrest and G V O'Reilly

AJNR Am J Neuroradiol 1989, 10 (2) 400-402

<http://www.ajnr.org/content/10/2/400.citation>

This information is current as
of May 8, 2025.

Production of Experimental Aneurysms at a Surgically Created Arterial Bifurcation

Mark D. Forrest¹ and Gerald V. O'Reilly

Several techniques have been used to produce experimental berry aneurysms in animals. Intracranial aneurysms have developed spontaneously in rats made hypertensive and fed on a lathyrogen diet [1]. Aneurysms have been induced on canine carotid arteries by the intramural injection of sclerosing agents [2]. However, the majority of experimental aneurysms have been manufactured surgically by grafting a vein pouch or vein patch onto the wall of an artery, resulting in a sidewall aneurysm [3–5]. This article describes a surgical method for producing an aneurysm in rabbits at an arterial bifurcation in the common carotid artery, a vessel similar in size to the proximal human middle cerebral artery. The model resembles a berry aneurysm both dynamically and radiographically, and is useful for developing endovascular therapeutic techniques.

Materials and Methods

New Zealand white rabbits weighing 4–5 kg were anesthetized with intramuscular ketamine,* 35 mg/kg, and xylazine,† 5 mg/kg. Each surgical procedure was performed under sterile conditions with the aid of an operating microscope.

A midline incision was made in the rabbit's neck extending from the manubrium sterni to the level of the angle of the jaw. A 2-cm segment of the right external jugular vein or one of its tributaries (the anterior or posterior facial veins) was isolated and any side branches ligated. The proximal end of the segment was divided transversely, while the distal end was divided obliquely. A 5-mm longitudinal cut was made in the V-shaped tail at the distal end of the segment (Fig. 1A). The vein segment was then placed in heparinized saline (20 IU/ml) at room temperature. A 6-cm length of the left common carotid artery was exposed and any branches proximal to the origin of the left internal carotid artery were ligated. The carotid artery was then ligated at the proximal end of the exposure. An atraumatic vascular clamp was placed 1 cm distal to the ligature. The artery was divided and a wedge of vessel was cut from the medial corner of the clamped distal portion of the artery (Fig. 1B).

The right common carotid artery was now exposed and the left carotid artery lifted over the trachea to meet it. A 6-mm-long elliptical arteriotomy [6] was made in the right carotid artery. A partial end-to-side anastomosis of the left carotid artery to the arteriotomy was

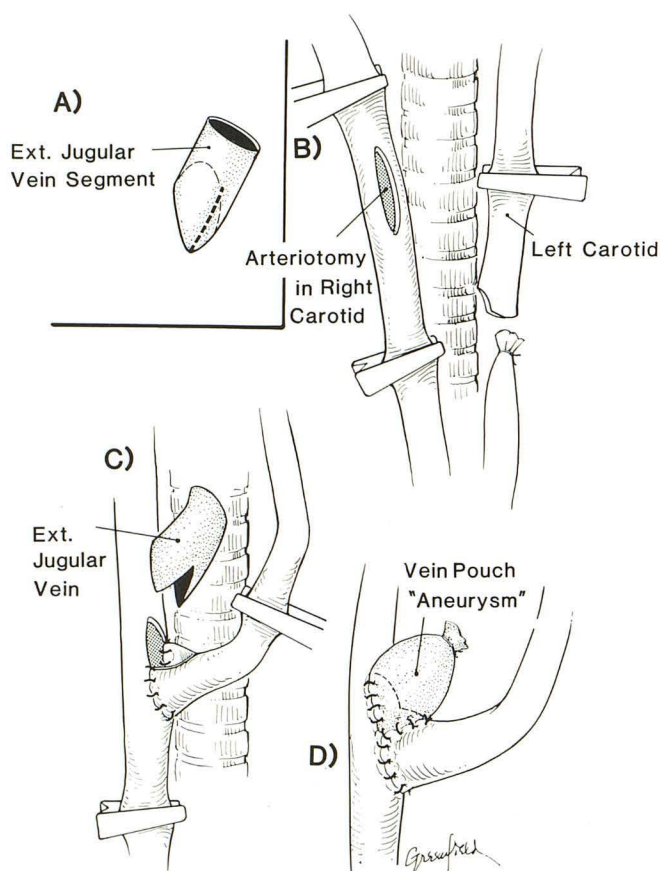


Fig. 1.—Illustrations depicting stages of grafting vein pouch to surgically constructed arterial bifurcation.

- A, 5-mm cut (dotted line) is made in V-shaped end of vein segment.
- B, Wedge is cut from medial corner of left common carotid artery and elliptical arteriotomy made in right common carotid artery.
- C, Partial end-to-side anastomosis of left common carotid artery to right common carotid artery is performed by using interrupted 10-0 monofilament nylon sutures.
- D, Vein segment is sutured to notch formed by anastomosis and open end of vein ligated with 5-0 silk suture to create aneurysm dome.

* Ketalar, Parke-Davis, Morris Plains, NJ.

† Rompun, Miles Laboratories, Inc., Elkhart, IN

Received March 25, 1988; accepted after revision June 21, 1988.

This work was supported by U.S. Public Health Service grant R01 HL29672 from the National Institutes of Health.

¹ Both authors: Department of Radiology, Harvard Medical School, and Beth Israel Hospital, 330 Brookline Ave., Boston, MA 02215. Address reprint requests to G. V. O'Reilly.

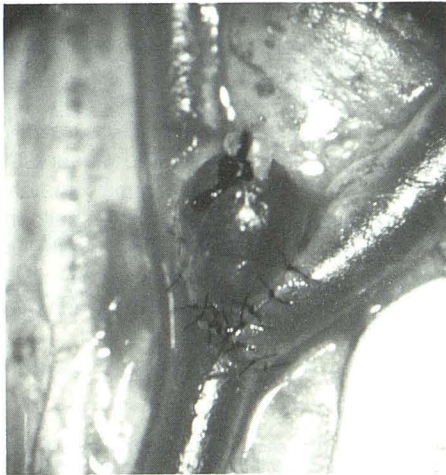


Fig. 2.—Experimental aneurysm at arterial bifurcation on rabbit carotid artery immediately after surgical production. Aneurysm is 4 mm long and 3 mm wide.

performed by using interrupted 10-0 monofilament nylon sutures (Fig. 1C). The vein segment was then sutured to the notch formed by the anastomosis (Fig. 1D). The free end of the vein segment was ligated with 5-0 silk, creating the dome of the aneurysm. All the clamps were then removed to allow filling of the vein pouch with blood (Fig. 2). A small polyethylene sheet was folded over the anastomosis site to control minor bleeding from the suture line. Once bleeding ceased, the sheet was removed. Any ligated side branches on the vein pouch were coated with a very small drop of cyanoacrylate glue.[†] This strengthened the ligated side branch to reduce the risk of its rupture. Care was taken not to apply the adhesive to the aneurysm wall. After the procedure the rabbit was placed on a heating pad for an hour.

Transfemoral carotid angiography was performed on each rabbit at a time varying from 1–10 weeks after aneurysm construction (Fig.

3). The aneurysm model was used to develop endovascular laser techniques of aneurysm ablation being studied in our laboratory [7].

Results

Three hours of surgical time were needed to construct each arterial bifurcation and aneurysm. Despite both carotid arteries being clamped simultaneously for at least 1 hr during the procedure, no neurologic complications ensued in any of the rabbits due to excellent compensatory blood flow to the brain through the vertebral arteries. Forty-five experimental aneurysms were constructed and 35 rabbits survived, all but one having a patent aneurysm. No signs of morbidity were present in the surviving rabbits. Seven rabbits died from hemorrhagic pneumonia within 2 days of the surgery. Two rabbits died from postoperative bleeding in the neck caused by a rupture of the vein pouch at the site of a ligated side branch. One rabbit died from a hemorrhage at the anastomosis site due to an inadequate number of sutures.

Angiography demonstrated spontaneous aneurysm thrombosis in one rabbit. In a second rabbit the left carotid artery was found to be occluded, although the aneurysm itself was patent. Both these complications were detected 1 week after the surgery. By angiography the dimensions of the 34 patent aneurysms ranged from 3.5–12 mm in length and 3–8 mm in width. An external jugular vein graft produced an aneurysm 4–8 mm wide. A segment of the anterior or posterior facial veins produced an aneurysm 3–5 mm wide. Most aneurysm necks were 2–3 mm in diameter (range, 2–5 mm). No noticeable change in aneurysm size or shape was identified between the operative and angiographic appearances, although serial angiography was not performed. The majority of the aneurysms were subjected to endovascular laser treatment within

[†] Bucrylate, Ethicon, Inc., Somerville, NJ.

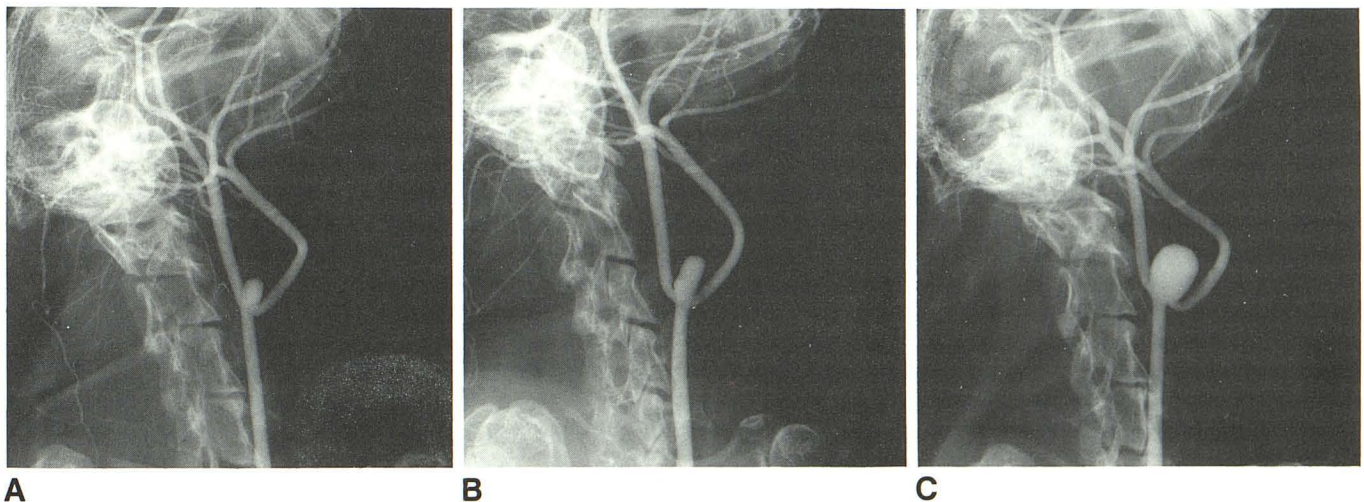


Fig. 3.—Transfemoral right common carotid arteriography in three rabbits (oblique projection) demonstrating patent vein pouch aneurysm at arterial bifurcation formed by surgical anastomosis of common carotid arteries.

A, Aneurysm is 5 mm long and 3 mm wide.

B, Aneurysm is 8 mm long and 4 mm wide.

C, Aneurysm is 10 mm long and 8 mm wide.

1 or 2 weeks of production, but some were left untreated for as long as 10 weeks.

Discussion

The availability of an experimental aneurysm situated at an arterial bifurcation is important because this is the site of many human intracranial berry aneurysms. Until now such an aneurysm model has been difficult to produce because of significant animal morbidity and aneurysm thrombosis [3, 8]. Our model has demonstrated low morbidity and consistent aneurysm patency, which we believe is related to the method of surgical anastomosis. The elliptical arteriotomy in the recipient vessel and the wedge cut from the corner of the mobilized artery provided a suitably wide orifice through which blood could flow into and out of the vein pouch, as well as into the transposed left carotid artery. By using this technique we have created experimental aneurysms of various diameters ranging from 3–10 mm. We selected the rabbit model because its common carotid arteries were similar in caliber to vessels of the human circle of Willis.

Two fatal aneurysm ruptures occurred early in our series, which, while adding a realistic quality to the model, were undesirable. The problem was subsequently corrected by applying a minute drop of liquid polymer to the weak portions of the pouch (i.e., the ligated side branches) at the time of surgery. All the aneurysms without immediate surgical complications remained patent until the time of treatment, in some instances for as long as 10 weeks. This compares favorably with the best results obtained in previous work, in which we demonstrated the effectiveness in sustaining aneurysm pa-

tency for 7 weeks by using an elliptical as opposed to a linear arteriotomy in the parent vessel [6].

Our bifurcation aneurysms were anatomically positioned to be accessible for subsequent treatment by intravascular catheter techniques. Small-diameter catheters could be readily navigated under fluoroscopic control into the aneurysm necks. The catheter lengths employed were approximately the same as those for a direct carotid approach in the balloon treatment of human berry aneurysms [9]. These features make the model suitable for the development of new methods of aneurysm ablation, as well as for practicing detachable balloon techniques of aneurysm occlusion.

REFERENCES

1. Hashimoto N, Handa H, Hazama F. Experimentally induced cerebral aneurysms in rats. *Surg Neurol* 1978;10:3–8
2. McCune WS, Samadi A, Blades B. Experimental aneurysms. *Ann Surg* 1953;138:216–218
3. Stehbens WE. Experimental production of aneurysms by microvascular surgery in rabbits. *Vasc Surg* 1973;7:165–175
4. Nishikawa M, Yonekawa Y, Matsuda I. Experimental aneurysms. *Surg Neurol* 1976;5:15–18
5. Young PH, Yasargil MG. Experimental carotid artery aneurysms in rats: a new model for microsurgical practice. *J Microsurg* 1982;3:135–146
6. O'Reilly GV, Utsunomiya R, Rumbaugh CL, Colucci VM. Experimental arterial aneurysms: modification of the production technique. *J Microsurg* 1981;2:219–223
7. O'Reilly GV, Forrest MD, Clarke RH, Schoene WC. Intravascular laser coagulation of experimental aneurysms. *Acta Radiol [Suppl]* (Stockh) 1986;369:586–590
8. Nishikawa M, Smith RD, Yonekawa Y. Experimental intracranial aneurysms. *Surg Neurol* 1977;7:241–244
9. Romodanov AP, Shcheglov VI. *Advances and technical standards in neurosurgery*. Wein: Springer-Verlag, 1982:25–49