



Get Clarity On Generics

Cost-Effective CT & MRI Contrast Agents



FRESENIUS
KABI

WATCH VIDEO

AJNR

Venous pressure measurements in vein of Galen aneurysms.

R G Quisling and J P Mickle

AJNR Am J Neuroradiol 1989, 10 (2) 411-417

<http://www.ajnr.org/content/10/2/411>

This information is current as
of August 23, 2025.

Venous Pressure Measurements in Vein of Galen Aneurysms

Ronald G. Quisling¹
J. Parker Mickle

Venous pressures were measured within the vein of Galen aneurysm/straight sinus complex in 15 patients with Galenic arteriovenous fistulae and vein of Galen aneurysms. Pressures exceeded normal (<5 cm of H₂O) in each instance, ranging between 9 and 55 cm of H₂O. Measured values exceeding 20 cm of H₂O were associated with an increased occurrence of brain calcification. Mean venous pressures were relatively higher in the patients with thalamic arteriovenous malformations, and relatively lower in patients with true vein of Galen fistulae and choroidal type malformations. A pressure gradient across the straight sinus was measured in one patient and suspected in three others when disproportionate dilatation of the vein of Galen occurred in the presence of a small or normal-sized straight sinus. No clear relationship existed between levels of venous pressure elevation and degree of ventriculomegaly. Refractory heart failure occurred only in neonates with choroidal type fistulae and no apparent venous outflow obstruction.

It is likely that the degree of venous pressure elevation reflects the hemodynamic significance of arteriovenous shunt, provided it is interpreted in context with the current clinical status and the angioarchitecture of the Galenic fistula. Such data may assist in the timing of embolotherapy. Patients with lower venous pressure are not likely to develop brain calcification or seizures, and therefore can tolerate transtorcular embolotherapy staged at wider intervals.

Galenic vascular malformations are typically associated with ectasia of the vein of Galen, the straight sinus, and often the torcula Herophyle [1–4]. Such vascular ectasia has been attributed to a combination of increased blood volume delivered through the arteriovenous shunt, and to increased venous pressure due in part to transmitted arterial pressures through the arteriovenous shunt and in part to obstruction to the egress of venous blood from the cranium [5]. Elevated pressure within the dural venous sinuses contributes to elevated pressure in the cerebral veins, ultimately hindering cerebral hemodynamic balance by narrowing the arteriovenous pressure differential [6, 7]. This article examines the interrelationships between elevated venous pressure within the vein of Galen aneurysm/straight sinus complex and variations in vein of Galen morphology, angioanatomy of venous outflow structures, complexity of the matrix of the Galenic vascular malformations, brain calcification, and overt heart failure. The long-term results of transtorcular embolization are currently under investigation [7]; however, preliminary data suggest that correlation between the level of venous pressure within the Galenic aneurysm/straight sinus complex and specific angiographic features of arteriovenous shunt as well as patterns of venous egress may provide insight into the physiology of these Galenic fistulae and may ultimately determine the need for transarterial or transtorcular embolotherapy.

Materials and Methods

Fifteen patients ranging in age from newborn to 10 years (Table 1), with retrothalamal fistulae and Galenic/straight sinus ectasia underwent transtorcular catheterization prior to

Received January 13, 1988; accepted after revision September 8, 1988.

¹ Both authors: Departments of Radiology (Neuroradiology Section) and Neurosurgery, University of Florida Medical Center, Gainesville, FL 32610. Address reprint requests to R. G. Quisling, Box J-374, JHMHC-Shands Radiology, Gainesville, FL 32610.

AJNR 10:411–417, March/April 1989
0195–6108/89/1002–0411
© American Society of Neuroradiology

wire coil embolization. In this procedure, the patient's head is positioned in a horizontal, lateral, decubitus position, and percutaneous needle puncture of the torcular Herophile is performed through either a posterior fontanel (if open) or through a small craniectomy site overlying the torcula. A guidewire is positioned within the straight sinus and a 6.3-French endhole catheter is placed into the vein of Galen by using a Seldinger technique. The relationship of the tip of the catheter to the central lumen of the vein of Galen aneurysm is confirmed by injection of contrast medium under direct fluoroscopic control. An intraaneurysmal pressure measurement is then made by

connecting a saline-loaded manometer to the catheter hub and centering the manometer base at the level of the torcula. Mean arterial blood pressure for all the infants and children at the time of venous pressure measurements ranged from 80–85 mm of Hg. Mean pressure for neonates was lower, ranging from 40–50 mm of Hg. All patients were studied, at least initially, while under general anesthesia. In one patient, venous pressures were measured in the mid-torcula as well as in the Galenic aneurysm/straight sinus region.

In both the straight sinus and the vein of Galen, the cross-sectional diameter increases in response to the increased blood volume passing through the Galenic fistula. They increase, however, in disparate amounts. Therefore, for purposes of comparison, it is necessary to introduce separate grading systems for both the morphologic appearance of the vein of Galen aneurysm/straight sinus complex (Fig. 1) and the angioarchitecture of the Galenic fistula matrix (Fig. 2).

The relative degree of ectasia of the vein of Galen compared with the straight sinus is determined by measuring the cross-sectional diameters of both, correcting for magnification, and presenting them as a proportion. The vein of Galen dilates the same as or more than the straight sinus in every case. For comparative purposes these morphologic relationships are grouped into four categories (Table 2) in the following manner: grade 1—the degree of ectasia of the straight

TABLE 1: Relationship Between Age and Venous Pressure

Age	No.	Venous Pressure (cm of H ₂ O)	
		Mean	Range
Newborn to 1 month	4	30	16–45
1 month to 2 years	5	32	18–45
Greater than 2 years	6	33	19–55
Normal venous pressure		<5	

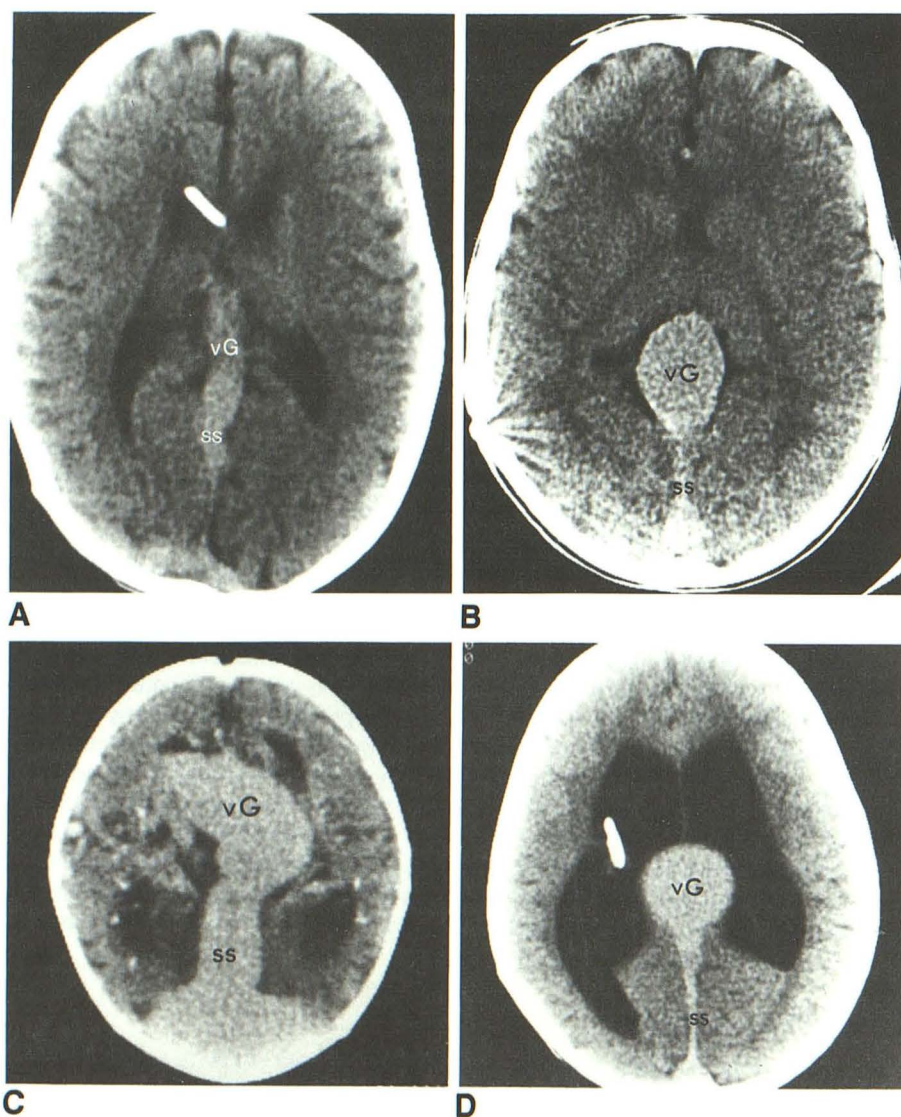


Fig. 1.—Grading system for relationship between vein of Galen aneurysm and straight sinus.

A, Grade 1—vein of Galen aneurysm (vG) and straight sinus (SS) have increased proportionately and minimally in size (compared with approximated normal).

B, Grade 2—vein of Galen aneurysm and straight sinus have increased mildly to moderately in size but often at a disparate rate.

C, Grade 3—vein of Galen and straight sinus have substantially increased in size.

D, Grade 4—vein of Galen aneurysm has markedly enlarged while straight sinus has remained nearly normal in size, a disproportionate increase.

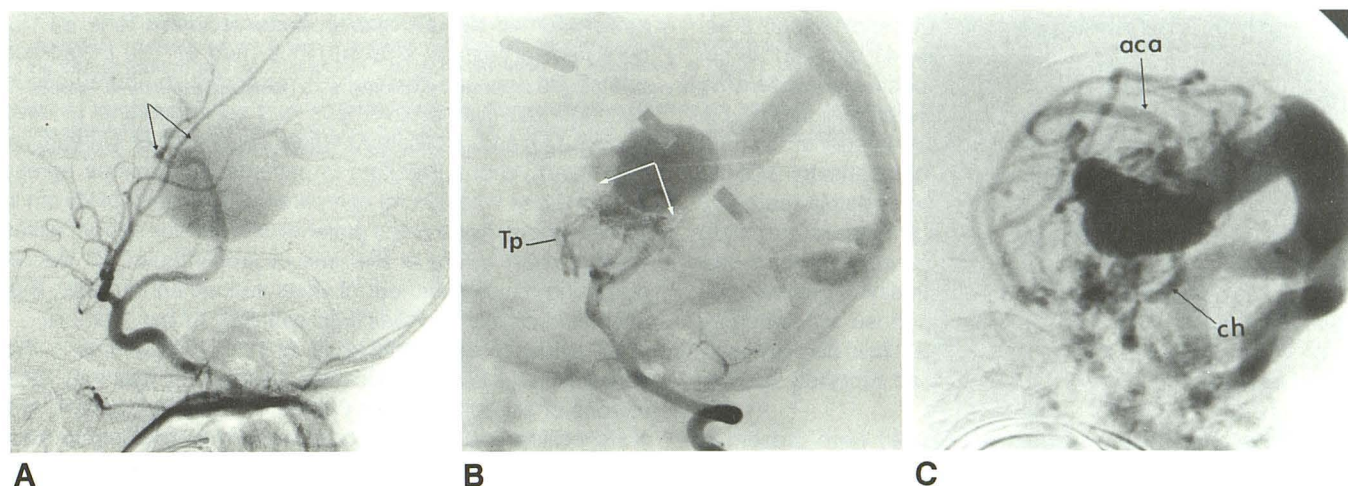


Fig. 2.—Grading system for the angioarchitecture of the Galenic arteriovenous malformations.

A, Category 1—the matrix of category 1 fistulae is relatively simple (arrows). Fewer than five and usually only one vessel contribute to the fistula. This type represents the “true” Galenic fistula. The angiomatous matrix size (when present) is less than 1 cm in length, as determined on either anteroposterior or lateral projection cerebral angiograms. The feeding vessels are usually unilateral.

B, Category 2—the matrix (arrows) of category 2 malformations is moderately complex. The predominant feeding arteries are mainly thalamoperforating (Tp), and usually arise bilaterally. The angiomatous matrix is 1–2 cm in size. No major cerebral cortical vessels contribute to the nidus of the fistula.

C, Category 3—these are the most complex fistulae. Their blood supply arises mainly from choroidal (ch) and cerebral cortical vessels, usually branches of the anterior cerebral arteries (aca). Vessels arise bilaterally. The matrix size exceeds 2 cm in most cases. The nidus of the fistula is composed of an angiomatous arteriocapillary matrix as well as direct arterial to vein fistulae.

TABLE 2: Relationship Between Relative Ectasia of the Galenic Aneurysm, the Straight Sinus, and Venous Pressure

Grade	Aneurysm: Straight Sinus	No.	Venous Pressure (cm of H ₂ O)	
			Mean	Range
1	Both minimally enlarged	1	9–>24	
2	Both moderately enlarged	5	38	18–55
3	Both markedly enlarged	5	41	22–55
4	Marked enlargement of the vein of Galen aneurysm but straight nearly normal in size	4	28	13–55

sinus is proportionate to the vein of Galen aneurysm, and both are only minimally enlarged; grade 2—the vein of Galen dilates more than the straight sinus, and both are moderately increased in size; grade 3—the vein of Galen and straight sinus dilate substantially, and both are markedly increased in size; and grade 4—the vein of Galen enlarges significantly (the classic vein of Galen aneurysm), while the straight sinus remains normal, small (stenotic appearing), or even unopacified by angiography.

The spectrum of retrothalamal vascular malformations includes direct arteriovenous fistulae and complex vascular malformations with choroidal or thalamic and/or leptomeningeal blood supply. For purposes of this article, all types are described generically as Galenic fistulae or arteriovenous shunts. None of the cases in this series had dural contributors to the arteriovenous shunt. These Galenic fistulae are categorized (Table 3) by using arteriographic criteria according to size and complexity of their angiomatous matrix, in the following manner. Category 1 includes true Galenic fistulae, in which there is either a direct arteriovenous communication or at best a small angiomatous matrix. The matrix size (measured in either anteroposterior or lateral projection of the cerebral angiogram) is less than 1 cm

TABLE 3: Galenic Fistulae Complexity

Type	Matrix Size (cm)	Angioarchitecture	No.	Venous Pressure (cm of H ₂ O)	
				Mean	Range
Category 1	<1	<5 feeders, usually unilateral	4	26	20–45
Category 2	1–2	>5 feeders and no ACA	5	41	24–55
Category 3	>2	>5 feeders and ACA	6	35	19–55

Note.—ACA = anterior cerebral artery.

and has fewer than five feeding vessels. These are uncomplicated fistulae in which the feeding arteries are often unilateral in origin. Category 2 includes deep thalamic vascular malformations. These Galenic fistulae have a matrix that is typically 1–2 cm in size that is supplied mainly by thalamoperforating arteries. They do not have primary leptomeningeal feeding arteries. Contributing vessels often originate bilaterally. Category 3 includes Galenic fistulae that have an angiomatous capillary network typically greater than 2 cm in size that are fed mainly by choroidal and anterior cerebral arteries.

Results

The mean venous pressure in the 15 patients in this series was 32 cm of H₂O, with a range of 9–55 cm. Mean venous pressures are compared with age categories in Table 1. It is evident that venous pressures do not substantially differ across age groups, since each category contains pressures ranging from minimally elevated to substantially elevated. None of the venous pressure readings even remotely approached normal values (<5 cm of H₂O).

Correlation between fistula complexity and venous pressure (Table 3) revealed values of 26 cm, 41 cm, and 33 cm of H₂O for categories 1, 2, and 3, respectively. Moderately complex fistulae (category 2) presented with the highest mean venous pressure. None of the patients in categories 1 and 2 exhibited symptoms of overt cardiac decompensation. Of the six patients with the most complex type of fistula (category 3), four were neonates and all of these presented with high-output heart failure. Although cardiac failure was not a predominant presenting symptom in the remaining patients, virtually every case in this series, including those with category 1 or 2 type fistulae, had evidence of at least mild cardiomegaly on chest radiographs. This is higher than reported in other series [2].

Venous abnormalities (and/or anomalies) were present in nine of 15 patients (Table 4). In each, some degree of real (a definable venous stenosis) or relative stenosis (implied by evidence of retrograde and/or collateral venous drainage) was apparent. Venous abnormalities included straight sinus ste-

nosis (four of 15), transverse sinus occlusion (one of 15), persistent accessory straight sinus (two of 15), retrograde orbital vein drainage (three of 15), retrograde temporal venous drainage into dilated cavernous and sphenoparietal sinuses (four of 15), and duplicated straight sinus (one of 15) (Fig. 3). The mean venous pressure in patients with venous egress abnormalities was 40 cm, compared with a mean of 25 cm in those without. None of the patients with venous abnormalities were in heart failure at the time of presentation. Of the six remaining patients without obvious venous abnormality, four of six had clinical and radiologic evidence of heart failure.

CT evidence of chronic brain injury in the patients in this series includes brain calcification (seven of 15 patients), focal regions of encephalomalacia (three of 15), see Figure 4, and nonspecific sulcal dilatation compatible with mild cortical atrophy (15 of 15). Venous pressure exceeded 20 cm of H₂O in all patients with brain calcification. The degree of dystrophic calcification ranged from subtle to extensive (Table 5). Most commonly, the calcification was deposited in white matter either adjacent to the lateral ventricular surface or near the arcuate fibers at the gray/white matter junction. Serial pretherapy CT studies were available in only one patient (4 years old); these demonstrated a striking progressive deposition of brain calcification (Fig. 5).

The relationship between venous pressure and aneurysm/straight sinus morphology is presented in Table 2. The venous pressure in the single grade 1 patient was measured originally at 9 cm of H₂O. This patient was not embolized, because the venous pressure was less than 20 cm (the apparent minimum level before brain calcification occurs) and the patient was virtually asymptomatic (other than cranial brain bruit). After a 12-month interval, CT revealed an increase in straight sinus size, and repeat torcular pressure measurement was 24 cm.

TABLE 4: Relationship Between Venous Pressure and Venous Abnormalities

Venous Abnormality	No.	Venous Pressure (cm of H ₂ O)	
		Mean	Range
None	6	25	9-45
Accessory straight sinus	2	40	35-45
Stenotic dural sinuses (straight or transverse)	5	41	19-55
Collateral venous drainage (orbital or cavernous sinus)	5	39	18-55

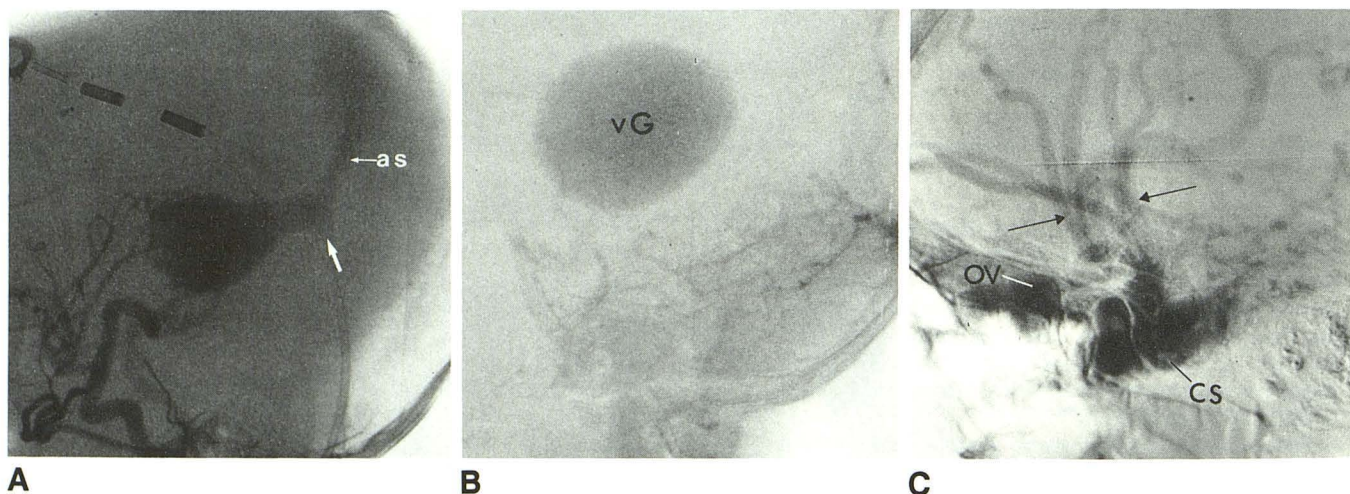


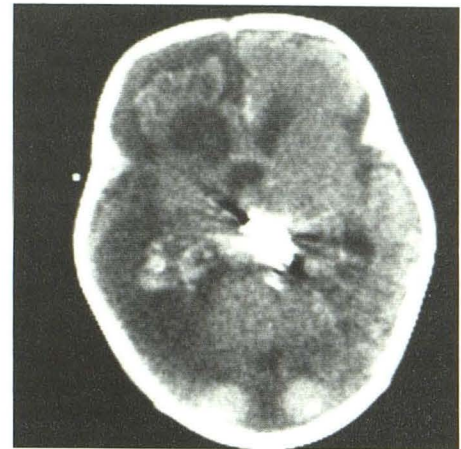
Fig. 3.—Variations in venous drainage associated with Galenic fistulae.

A, Accessory straight sinus. Anomalies of the vein of Galen venous egress occurred in seven cases. In this example there is occlusion of the straight sinus (arrow) and concomitant drainage through an accessory (or embryonic) straight sinus (as).

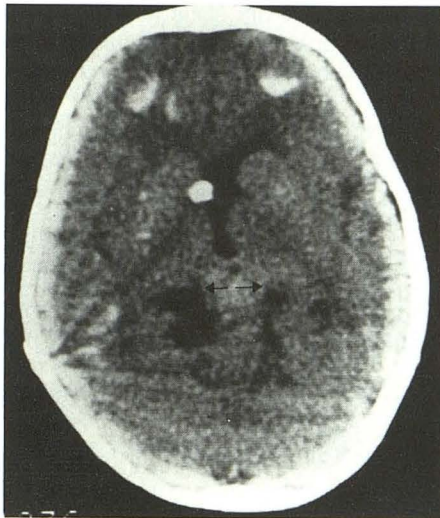
B, Stenosis of the straight sinus. Stenosis of the straight sinus in the presence of a substantially enlarged vein of Galen (vG) occurred in four of 15 cases. In this instance, the straight sinus was never clearly opacified in any phase of the angiogram; yet, a transtorcular catheter could be passed easily through the straight sinus. This suggests that the straight sinus may have developed a muscular layer with vasospastic capability.

C, Retrograde venous drainage. Retrograde venous drainage through temporal and Sylvian veins into the cavernous sinus and orbital veins occurred in five of 15 cases. Of these, venous egress from the cavernous sinus was limited entirely to drainage through the orbital veins, as in this example. In this case, prominent temporal veins (arrows) drain into a dilated cavernous sinus (CS) before exiting through enlarged orbital veins (OV).

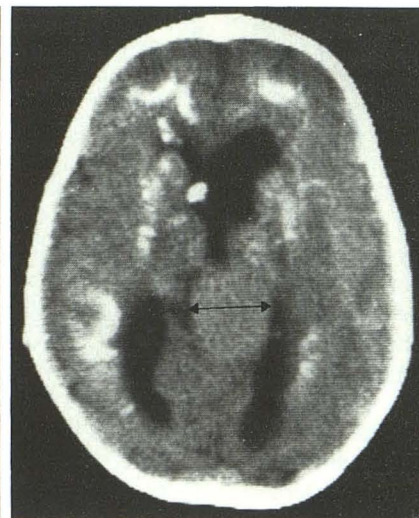
Fig. 4.—Encephalomalacia associated with a Galenic malformation. Brain ischemia related to altered cerebrovascular perfusion in patients with Galenic fistulae causes variable injuries, including diffuse central and cortical atrophy, brain calcification (as illustrated in Fig. 5), and varying degrees of encephalomalacia. CT in this newborn patient with a category (type) 3 fistula demonstrates extensive right cerebral encephalomalacia. Conceivably, such changes could be in part developmental, but are more likely to be related to fistula-induced oligemia in the right cerebral hemisphere. The unilaterality of the changes remains unexplained.



4



A



B

Fig. 5.—Progressive brain calcification associated with a Galenic malformation.

A and B, CT in 1980 (not shown) demonstrated hydrocephalus and only subtle brain calcification. CT in 1983 (A) demonstrated deposition of calcium in the frontal white matter. CT in 1984 (when patient presented for embolotherapy) demonstrated a substantial increase in the extent of brain calcification (B) including periventricular and subcortical locations. The rate of calcium deposition appears to be more rapid in the latter year than occurred between 1980 and 1983. Measured pressure within the vein of Galen aneurysm in 1984 was 50 cm of H₂O. This nonlinear progression of brain calcification suggests that a critical balance between arterial and venous pressures is exceeded, which then allows dystrophic calcification to proceed. The rim of increased cortical density in A is artifactual. Cross-sectional diameter of vein of Galen (arrows) demonstrates a progressive increase roughly proportional to the increase in brain calcification.

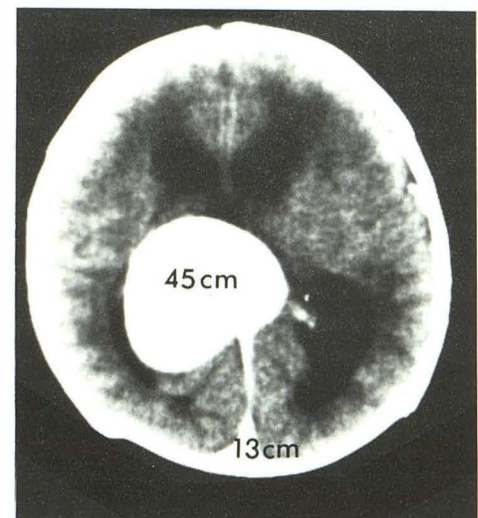


Fig. 6.—Example of grade 4 vein of Galen aneurysm/straight sinus complex. CT scan demonstrates grade 4 aneurysm/straight sinus complex with markedly enlarged vein of Galen aneurysm but a relatively normal straight sinus. Venous pressure (in cm of H₂O) is 45 cm within vein of Galen aneurysm and 13 cm within torcula. This size disparity indicates the presence of a pressure gradient across the straight sinus. None of the patients with this complex displayed evidence of brain calcification.

Mean venous pressure in aneurysm/straight sinus grades 2 and 3 was 38 cm and 41 cm, respectively. Patients with grade 4 aneurysm/straight sinus complex had mean venous pressure of 28 cm. A venous pressure gradient (45 cm vs 13 cm) was documented between the aneurysm and the torcula in one patient with a grade 4 aneurysm/straight sinus complex (Fig. 6). This patient is one of four who demonstrated a small diameter, relatively stenotic-appearing straight sinus. On the basis of similarities in clinical behavior and angiographic features, it is suspected that a pressure gradient across the straight sinus exists in these patients.

Discussion

Increased blood flow through Galenic fistulae can result in diminished cerebral perfusion, a mechanism usually indicted as the cause of the neurologic sequelae associated with Galenic fistulae [2, 8, 9]. Although ischemia may be the ultimate mechanism for brain injury, underperfusion can result from either focal oligemia (diminished flow in a specific arterial territory), generalized oligemia (cerebral "steal" phenomenon related to preferential flow through the fistula), or a decreased arteriovenous pressure gradient (secondary to chronically

TABLE 5: Relationship Between Venous Pressure and Brain Calcification

Calcification	No.	Venous Pressure (cm of H ₂ O)	
		Mean	Range
1/4 (none)	8	24	16–55
2/4 (minimal)	4	37	35–45
3/4 (moderate)	1	35	
4/4 (extensive)	2	52	50–55

elevated cerebral venous pressure). Capillary-level cerebral perfusion is directly proportional to arteriovenous pressure differences and inversely proportional to vascular resistance [10]. In patients with Galenic fistulae, decreased perfusion pressure must occur to some extent because of the elevated venous pressure in the context of normal arterial pressures. In addition, regional arteriovenous shunting reduces the overall cerebrovascular resistance, which in turn produces a compensatory high-output cardiac state. When the heart begins to decompensate, arterial perfusion pressure and stroke volume decrease, further diminishing cerebral perfusion [11]. The sequelae of chronic ischemia combined with marginal cardiac status accounts for many of the clinical symptoms in patients with vein of Galen fistulae, particularly seizures and failure to thrive. Since a vital component of perfusion physiology relates to the arteriovenous pressure differences, this study was undertaken to evaluate the relationship between vein of Galen/straight sinus venous pressure measurements and several radiologically documentable parameters; namely, complexity of the fistula matrix, aneurysm/straight sinus size relationships, ventriculomegaly, venous structural abnormalities, occurrence of brain calcification, and frequency of refractory heart failure.

The mean venous pressure in the 15 patients in this series does not differ significantly by age (Table 1). Thus, categorization of Galenic arteriovenous shunts by age alone does not reveal insight into hemodynamic significance. Simple fistulae have lower mean venous pressures (26 cm) than do more complex fistulae. However, the most complex arteriovenous malformations, choroidal (category 3) fistulae (Table 3) with cerebral artery contributors, have lower mean pressures (35 cm) than the category 2 fistulae (41 cm). The explanation for this is multifactorial. Overt heart failure (present in four of six patients in category 3) would lower shunt volumes, which in turn would lower venous pressure. Possibly more significantly, these patients had little evidence of venous egress abnormalities (i.e., they had a low-resistance venous system).

Obstructions to venous egress are reported with vein of Galen aneurysms and may represent the inciting factor [12, 13]. Venous abnormalities, in the main, reflect a direct or relative hindrance to the efflux of blood from the cranium. In this series venous abnormalities (see Table 4) included presence of an accessory straight sinus; stenosis of the straight sinus (or grade 4 aneurysm/straight sinus complex); transverse sinus stenosis; and prominent retrograde collateral venous drainage routes, usually through the sphenoparietal sinus, cavernous sinus, or the orbital veins. Measured venous

pressure within the aneurysm/straight sinus complex was higher in patients with venous aberrations (40 cm) than in those without (25 cm). Significantly, as documented in one patient and suspected in three others with a grade 4 aneurysm/straight sinus complex, torcula pressure can be substantially lower than Galenic aneurysm pressure, indicating the presence of a pressure gradient across the straight sinus (Fig. 6). It is important to note that neonates, who present with overt heart failure, had both lower measured venous pressures and no apparent vein abnormalities or retrograde filling of collateral cerebral veins. This suggests that a combination of a low-resistance venous system and a choroidal type of Galenic fistula contributes to the observed hemodynamic consequences in neonates. It is not clear whether venous stenosis represents an associated anomaly [5], an occurrence preceding development of the arteriovenous shunt, or a compensatory vascular response to the Galenic fistula. Those with accessory straight sinus (and atresia of the primary straight sinus) suggest a congenital nature. Others, as those with a grade 4 aneurysm/straight sinus complex, suggest a more functional state, since they allow unobstructed passage of the transtorcular catheter through the apparently stenotic segment even when it remained unopacified during angiography, as evident in Fig. 3B. The venous narrowing in this circumstance is not rigidly atretic or fibrotic, but rather suggests (and this is purely conjecture) a vasoconstrictive response by the straight sinus to the increased shunt volume and/or elevated vein of Galen/proximal straight sinus pressure. It is known that cerebral veins possess both myogenic and neurogenic vasoconstrictive properties [6]. Whether this applies to dural sinuses, and to the straight sinus in particular, has not been investigated.

Correlation between the degree of ectasia of the vein of Galen/straight sinus complex and venous pressure offers a means of comparing morphology (cross-sectional diameter measurements) with hemodynamic features (measured venous pressure) of Galenic arteriovenous shunts. The single case with a grade 1 complex (having a minimal and comparable increase in both the vein of Galen and the straight sinus size) had only mildly elevated intraluminal venous pressure. The mean venous pressures of grades 2 and 3 (those with moderate or marked ectasia) are significantly higher than that of grade 1 (minimal ectasia), but do not vary significantly between themselves. Those cases with a grade 4 aneurysm/straight sinus complex, however, constitute an important category. A pressure differential between intraaneurysmal and torcula pressure was documented in one case (Fig. 6). Three additional cases had marked vein of Galen ectasia in the presence of a nondilated or "stenotic" appearing straight sinus. It is likely that a pressure gradient exists across the straight sinus in these cases as well. High intraaneurysmal pressure is, therefore, less likely to be transmitted to the general cerebral venous system. In support of this, none of the four patients with a grade 4 complex developed brain calcification or presented with cardiac failure. Such patients are more likely to thrombose spontaneously [14] or to thrombose with only minimal embolotherapy.

The relationship between ventriculomegaly and vein of Galen aneurysm/straight sinus size is not directly explainable

by compression of the caudal third ventricle or cerebral aqueduct by the ectatic vein of Galen. In those cases in which the Galenic aneurysm size is small, as with grades 1 and 2 morphology, and CT evidence of cisternal space separating the aneurysm from the caudal third ventricle or aqueduct exists, ventriculomegaly or frank hydrocephalus requiring a ventriculoperitoneal shunt occurred in five of six patients. Of the nine patients with substantial aneurysm enlargement six required shunts while the remaining three did not, at least not prior to embolotherapy. These findings suggest that the elevated venous pressure sufficiently limits resorption of CSF to account for all or part of the ventriculomegaly in most cases.

Parenchymal brain calcification was located in both periventricular and/or subcortical positions. No calcification occurred in posterior fossa brain structures, or in either the angiomatous malformations or in the walls of the vein of Galen aneurysms. Calcification occurred most frequently in the white matter adjacent to the frontal horns and trigones (Fig. 5). The relationship between venous pressure and brain calcification in all likelihood is related at least in part to chronically increased cerebral venous pressure. None of the six patients in whom venous pressure remained under 20 cm of H₂O had evidence of brain calcification. Venous pressures, serially measured in two of these six patients over 14 months, increased to greater than 20 cm, but no concomitant CT evidence of calcification accrued during this time interval. No calcification was present in patients with the grade 4 aneurysm/straight sinus complex, suggesting a protective effect of the straight sinus stenosis. Of the nine patients with pressures greater than 20 cm, two patients had no calcification, four had small amounts, and three had moderate or extensive amounts of calcification. Brain calcification was present in three of the four patients presenting in the newborn period. In the one case (Fig. 5) in which serial CTs were available, there was incontrovertible evidence of progressive calcification occurring over a 4-year interval and was noted to accelerate in the year prior to treatment. However, for most patients serial CTs were not available prior to embolotherapy. Thus, the rate of brain calcification cannot be determined with assurity. Such variability in extent and age of first documentation suggests that multiple factors are operative in the development of brain calcification, including the duration and degree of venous pressure elevation.

In summary, it is helpful to condense the data presented above. All Galenic fistulae in this series had elevated straight sinus/vein of Galen aneurysm venous pressure (range, 9–55 cm of H₂O). Progressive increase in venous pressure was observed in two patients over a 6-month interval, indicating that this is a dynamic process. The extent of vein of Galen/straight sinus complex ectasia is proportional to the extent of venous pressure elevation. Minimal ectasia, assuming both the vein of Galen aneurysm and the straight sinus dilate, is likely to exhibit mild pressure elevation, while substantial ectasia is likely to have higher venous pressures. However, cases with disproportionate ectasia (where the vein of Galen dilates strikingly but the straight sinus does not) are likely to

have a pressure gradient across the stenotic straight sinus, and exhibit only minimal venous pressure elevation in the torcula.

Higher venous pressures were associated with more complex (choroidal and/or thalamic) arteriovenous malformations than with simple (true Galenic) fistulae. Only those patients with arteriovenous shunts having cerebral artery contributors (choroidal/category 3 type) presented with overt cardiac failure. Elevated venous pressure (>20 cm of H₂O) was associated with an increased occurrence of brain calcification. Abnormalities of venous efflux existed in nine of 15 patients. None of these presented in overt failure. On the other hand, four of the six remaining patients who exhibited no obvious obstruction to venous egress presented in cardiac failure. These observations suggest lowered resistance to venous egress in the face of a Galenic arteriovenous shunt, resulting in a higher shunt volume and greater cardiac strain. Furthermore, the lowered venous resistance decrease diastolic filling pressure for the coronary arteries, resulting in an ischemic cardiomyopathy. These observations raise the possibility that limiting flow through the dural venous system, as occurs with transtorcular wire coil embolization, may provide a physiologic means of controlling shunt volume and straight sinus pressure.

REFERENCES

1. Aube M, Tenner M, Brown J, Sher J. Arteriovenous malformation of the vein of Galen. *Acta Radiol [Suppl] (Stockh)* 1975; 347:23–30
2. Diebler C, Dulac O, Renier D, Ernest C, Lalande G. Aneurysms of the vein of Galen in infants aged 2 to 15 months. Diagnosis and natural evolution. *Neuroradiology* 1981; 21:185–197
3. Martelli A, Scotti G, Harwood-Nash C, Fitz C, Chuang S. Aneurysms of the vein of Galen in children: CT and angiographic correlations. *Neuroradiology* 1980; 20:123–133
4. Roosen N, Schirmer M, Lins E, Bock WJ, Stork W, Gahen D. MRI of an aneurysm of the vein of Galen. *AJNR* 1986; 7:733–736
5. Lasjaunias P, Ter Brugge K, Lopez Ibor L, et al. The role of dural anomalies in vein of Galen aneurysms. *AJNR* 1987; 8:185–192
6. Auer LM, MacKenzie ET. Physiology of the cranial venous system. In: Kapp J, Schmidek H, eds. *The cerebral venous system and its disorders*. Orlando: Grune & Stratton, 1984:169–227
7. Vinuela F, Nombela L, Roach MR, Fox AJ, Pelz DM. Stenotic and occlusive disease of the venous drainage system of deep brain AVMs. *J Neurosurg* 1985; 63:180–184
8. Mickley JP, Quisling R. Transtorcular approach to vein of Galen aneurysms. *Concepts Pediatr Neurosurg* 1985; 6:230–238
9. Norman M, Becker L. Cerebral damage in neonates resulting from arteriovenous malformations of the vein of Galen. *J Neurol Neurosurg Psychiatry* 1974; 37:252–258
10. Hoffman H, Chuang S, Hendrick E, Humphrey R. Aneurysms of the vein of Galen. *J Neurosurg* 1982; 57:316–322
11. Cronquist S, Granholm L, Lundstrom N. Hydrocephalus and congestive heart failure caused by intracranial arteriovenous malformation in infants. *J Neurosurg* 1974; 36:249–254
12. Rayboud CH, Hald JK, Strother CHM. Vein of Galen aneurysms. *AJNR* 1985; 6:457 (abstr)
13. Okudera T, Ohta T, Huang Y. Embryology of the cranial venous system. In: Kapp J, Schmidek H, eds. *The cerebral venous system and its disorders*. Orlando: Grune & Stratton, 1984:93–107
14. Smith J, Kampine J. Hemodynamics. *Circulatory physiology*, 2nd ed. Baltimore: Williams & Wilkins, 1984:16–31