



## Discover Generics

Cost-Effective CT & MRI Contrast Agents



FRESENIUS  
KABI

WATCH VIDEO

# AJNR

## Technique for cranial CT scanning of excessively obese patients.

I J Finch, Y Sun and S A Shatsky

*AJNR Am J Neuroradiol* 1989, 10 (2) 434

<http://www.ajnr.org/content/10/2/434.citation>

This information is current as  
of June 28, 2025.

# Technique for Cranial CT Scanning of Excessively Obese Patients

Ira J. Finch,<sup>1</sup> Yvonne Sun, and Stanley A. Shatsky

CT scanning has become a virtually indispensable tool in evaluating patients quickly and accurately for intracerebral disease, particularly in the emergency room. Occasionally, some patients cannot be scanned because their weight exceeds the capacity of the CT scanner table, generally in the range of 300 lb. (137 kg).

## Materials and Methods

The technique devised makes use of two Hoyer patient lifts.\* The lift consists of a metal frame and legs on wheels from which a cloth sling is suspended. A patient lying on the sling, which is hooked to a

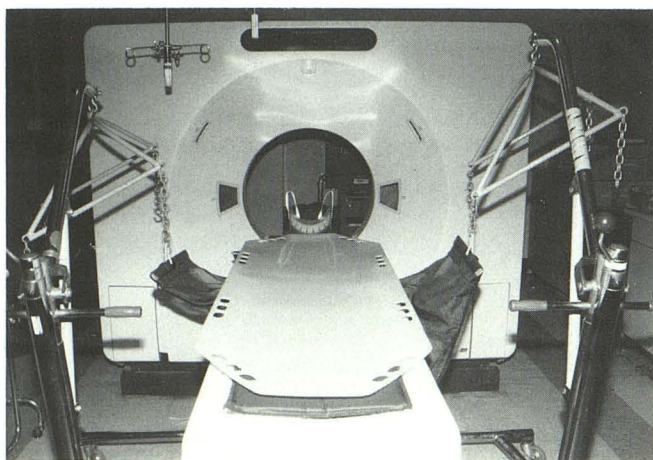


Fig. 1.—Apparatus for supporting patient. White plastic buckboard on which patient rests is supported by a sling suspended from two Hoyer lifts that flank CT table.

metal suspension device, can be lifted or lowered by means of a hand crank that controls the elevation of the frame.

In the CT suite, the patient is placed supine on a plastic spinal buckboard.<sup>†</sup> A single sling is positioned underneath the buckboard at the level of the patient's thighs. The sling is then connected to two Hoyer lifts, one on each side of the CT table (Fig. 1). The legs of the lifts are anchored with approximately 40 lb. (18 kg) of weight to stabilize them. The lifts are then cranked up approximately 3 cm to reduce the patient's weight on the table. We have found that by positioning the sling at thigh level, the patient and sling will move freely with the table, permitting accurate scanning at 10-mm slice intervals. The Hoyer lifts themselves remain stationary.

Using this method we performed three studies on two patients, one 350 lb. (159 kg) and the other 329 lb. (149 kg). We obtained a scout image and approximately 12 10-mm contiguous axial slices. The time required for each procedure was similar to that for a standard cranial CT. All scans were performed on a GE 9800 unit,<sup>‡</sup> which has a weight limit of 320 lb. (145 kg) for head scanning. All studies were of high quality and eminently diagnostic.

## Discussion

The Hoyer lift is readily available in many hospitals and is generally used by nurses to lift patients from their beds. By using two of these devices, a very heavy patient can be adequately supported, permitting safe scanning in a relatively short period of time. To our knowledge, no technique permitting the scanning of patients who exceed the weight limit of the CT table has previously been reported. Although relatively few patients are precluded from CT scanning by their weight, neuroradiologic evaluation in these patients is problematic. Their weight and size often restrict evaluation by MR imaging and by arteriography as well.

\* Hoyer, Oshkosh, WI.

† Smooth Mover, Alimed, Dedham, MA.

‡ General Electric, Milwaukee, WI.

Received June 28, 1988; accepted August 14, 1988.

<sup>1</sup> All authors: Departments of Radiology and Neurosurgery, Santa Clara Valley Medical Center, 751 S. Bascom Ave., San Jose, CA 95128. Address reprint requests to I. J. Finch.