



## Discover Generics

Cost-Effective CT & MRI Contrast Agents



WATCH VIDEO

# AJNR

### **Cerebral CT of lethal ethylene glycol intoxication with pathologic correlation.**

J Zeiss, M E Velasco, K M McCann and R J Coombs

*AJNR Am J Neuroradiol* 1989, 10 (2) 440-442

<http://www.ajnr.org/content/10/2/440.citation>

This information is current as  
of June 28, 2025.

## Cerebral CT of Lethal Ethylene Glycol Intoxication with Pathologic Correlation

Jacob Zeiss,<sup>1</sup> Manuel E. Velasco,<sup>2</sup> Kevin M. McCann,<sup>1</sup> and Robert J. Coombs<sup>1</sup>

The effect of various toxic substances on the brain has often been found to be relatively characteristic of, if not specific for, a given toxin. Carbon monoxide poisoning, for instance, has a predilection for the globus pallidus and cerebral white matter [1]. Methanol intoxication has an affinity for the putamen [2]. While the CT findings are not specific, insofar as other entities may produce occasionally similar findings and variations may occur within each toxin group, they are consistent enough to establish overall patterns. These patterns are generally reflected in conventional cranial CT scans.

Although the gross pathologic and histologic changes of ethylene glycol intoxication have been documented previously, the CT manifestations have only been alluded to in two prior case reports. Since they were sublethal, neither of these had direct pathologic correlation. A general pattern can be seen emerging from these few cases. The purpose of this paper is to describe a cranial CT pattern we believe is fairly typical, though not diagnostic, of ethylene glycol poisoning, as well as to correlate these findings with the pathologic changes discovered on the subsequent autopsy.

### Case Report

A 29-year-old man presented to a local emergency department approximately 6 hr after ingesting several ounces of ethylene glycol in a suicide attempt. He had slurred speech and ataxia but did not smell of alcohol. His initial physical examination was otherwise unremarkable. CBC, blood chemistry, and electrolytes at this time were normal, except for a slightly decreased calcium of 8.4 mg and a slightly widened anion gap. Arterial blood gases revealed metabolic acidosis with pH 7.2,  $pO_2$  94, and  $pCO_2$  31. He was given standard overdose therapy in the emergency department. An IV ethanol infusion was also begun for competitive enzyme binding, although this was subsequently found to be subtherapeutic for the first several hours.

Over the next 12 hr the patient deteriorated rapidly. He became lethargic and progressively obtunded. Breathing became shallower and more rapid. His pulse rate increased to 90 and his rhythm became irregular with frequent ventricular premature contractions. Blood pressure dropped to 100/50. Urine output decreased steadily to less than

10 ml/hr. He suffered occasional convulsions. Repeat CBC remained normal but blood chemistry revealed increasing hypocalcemia at 6.6 mg and decreasing renal function with creatinine at 2.3. Arterial blood gasses continued to show high anion gap metabolic acidosis with pH 7.2.

At this point the patient was transported to a larger medical center. Within hours of arrival, or approximately 24 hr after ingestion, he was totally comatose without spontaneous movement or response to any stimuli. Intubation and mechanical ventilation became necessary. Pulse rate varied between 80 and 160 with runs of ventricular tachycardia requiring lidocaine drip and intermittent cardioversion. An EKG further revealed complete right bundle branch block and first degree AV block. Blood pressure was maintained at 90 systolic with dopamine. Urine output ceased and a Quinton hemodialysis catheter was inserted. As blood chemistry continued to show severe hypocalcemia at 5.5 mg, IV calcium gluconate was maintained as was sodium bicarbonate for the persistent moderate metabolic acidosis. Valium was used intermittently for seizure activity.

The patient was stabilized over the next 48 hr and maintained on these multisystem support modalities. A noncontrast CT obtained at this time revealed diffuse cerebral edema with effacement of the peripheral sulci and fissures as well as the central cisterns (Fig. 1). The occipital horns and trigones were mildly dilated. In addition, there were striking areas of low attenuation involving the central white matter of the cerebellum, including the dentate nucleus and reticular formation as well as the pons, mesencephalon, mediobasal temporal lobes, thalamus, lentiform nuclei, and probably the claustrum. The internal and external capsule regions were obscured by the diffuse decreased attenuation in this area.

Over the next 3 weeks the metabolic acidosis and hypocalcemia were gradually corrected and stabilized. As a result, cardiac status was also improved and stabilized, and blood pressure could be adequately maintained without dopamine. However, the patient could not be weaned from the respirator and required extensive support for intermittent pulmonary atelectasis and infection. Furthermore, renal function remained essentially nonexistent, mandating continued dialysis. He remained comatose without spontaneous movement and nonresponsive to verbal stimuli. Decorticate posturing was present upon painful stimulus, pupils became unreactive, and bilateral Babinski signs were present.

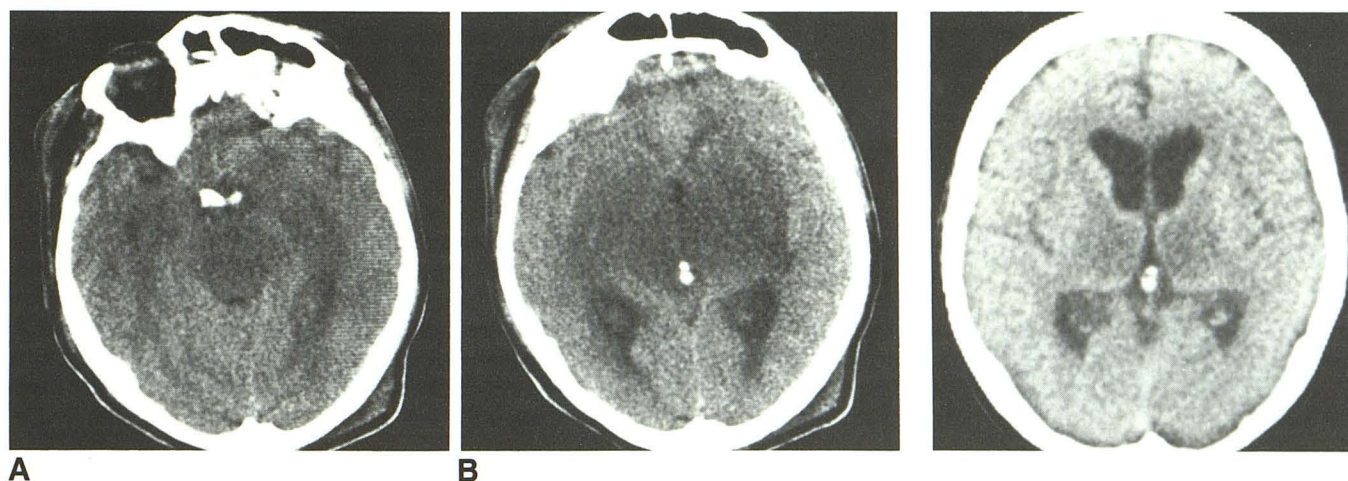
A repeat noncontrast CT at this time (3 weeks after insult) was surprising, however, insofar as the extent of CT abnormality did not correlate well with the clinical status (Fig. 2). The CT was, in fact,

Received August 10, 1987; accepted after revision December 8, 1987.

<sup>1</sup> Department of Radiology, Medical College of Ohio, C.S. 10008, Toledo, OH 43699. Address reprint requests to J. Zeiss.

<sup>2</sup> Department of Pathology, Medical College of Ohio, Toledo, OH 43699.





**Fig. 1.**—A and B, Noncontrast CT scans obtained 48 hr after ethylene glycol ingestion show areas of decreased attenuation in the central basilar areas of the brain; specifically, in the pons, mesencephalon, and mediobasal temporal lobes (A) and the thalami and basal ganglia (B) with consequent obscuring of the internal, external, and extreme capsules. Slight dilatation of posterior lateral ventricles is present despite such other findings of cerebral edema as effacement of third ventricle and anterior horns, basal cisterns, and peripheral sulci.

**Fig. 2.**—Follow-up noncontrast CT scan obtained 3 weeks after insult shows persistence of decreased attenuation only in thalamus and medial globus pallidus. Cerebral edema has completely resolved, with increasing prominence of anterior ventricular horns, third ventricle, cisterns, and fissures.

improved from the initial one of 3 weeks prior. The diffuse cerebral edema had resolved with normal or perhaps even slightly prominent demarcation of the basal cisterns, fissures, and sulci. The areas of diminished attenuation in the pons, cerebellum, and mesencephalon were no longer present. The low-density obscuring basal ganglia, thalami, and adjacent capsules showed resolution in all but the thalami and medial portions of the globus pallidus. However, as the outlook was hopeless, dialysis was discontinued and the patient died shortly thereafter.

At autopsy, the brain weighed 1340 g and did not appear edematous. Microscopic examination showed prominent findings in numerous vessels. Crystalline deposits of calcium oxalate were found in the walls of small blood vessels. The deposits appeared limited to the arteriolar walls and no crystals were found free in the intervening parenchyma. The crystals were round and globular in shape and showed a radial rosettelike pattern of fine needles converging in the center. They had a yellowish tinge and were double refractile under polarized light. They did not stain with hematoxylin and eosin but appeared dark gray to black with the Pizzolato's stain for calcium oxalate [3]. A slight perivascular infiltrate of predominantly polymorphonuclear leukocytes was present but no microscopic hemorrhages were seen. The adjacent neuropil showed variable degrees of vacuolization with evidence of neuronal loss, axonal swellings, and a patchy infiltrate of activated microglial cells but no fully developed macrophages or evidence of astrocytic reaction. These changes were particularly evident in the midline thalamic nuclei and brainstem pontine nuclei, reflecting the changes found on CT. The leptomeninges covering the pons showed a sparse inflammatory exudate consisting mainly of neutrophilic leukocytes, few lymphocytes, and monocytes. These findings are consistent with typical changes of ethylene glycol toxicity [4, 5].

## Discussion

Only two prior case reports could be found that specifically refer to the cranial CT findings of ethylene glycol intoxication

[6, 7]. The first of these two sublethal cases described areas of decreased attenuation in the pons, basal ganglia, thalamus, corpora quadrigemina, and mediobasal portions of the temporal lobes as well as moderate cerebral edema. The findings were present 2 days after ingestion and were essentially completely resolved at 5 days. A second report demonstrated a similar pattern of acute centrally decreased attenuation with diffuse cerebral edema but otherwise sparing of the corona radiata and cortical gray matter. On day 17 a repeat CT scan demonstrated resolution of the density abnormalities and diffuse edema with development instead of mild central atrophy.

Clearly, a pattern emerges in which one sees a broad area of decreased attenuation in the mediobasilar portions of the brain as a result of acute ethylene glycol intoxication. This reflects relatively widespread regional ischemia involving the central basilar brain (i.e., brainstem, dentate nucleus, thalamus, basal ganglia, corpora quadrigemina, mediobasilar temporal lobes, and internal capsule). Generally, accompanying these findings is diffuse cerebral edema. Interestingly, our patient actually demonstrated slight dilatation of his posterior ventricular horns rather than the effacement usually produced by cerebral edema. Certainly, cerebral edema was indicated by the compression of the anterior horns, third ventricle, cisterns, and sulci. A possible explanation may be acute increase in CSF production secondary to ischemic insult or decrease in the rate of reabsorption, perhaps in conjunction with the least degree of edema and mass effect occurring in the vicinity of the posterior horns.

While the cerebral edema responds fairly promptly (in less than a week) the resolution of diminished attenuation also occurs within a relatively short time. Maier [6] described a return to isodensity within 4 days, and Bobbitt et al. [7] at 17



days. Our case showed dramatic CT improvement at 21 days. However, CT improvement is not necessarily a barometer of clinical course or prognosis. Nevertheless, from a differential standpoint, we believe the residual thalamic attenuation decrease is significant, since other toxins that have an affinity for the general basal ganglia vicinity do not show a particular predilection for the thalamus.

The extent and distribution of the lesions found on autopsy further confirmed the predilection for thalamic involvement as well as the inability of the follow-up CT scan to reflect accurately the underlying pathology. Despite improvement in cerebral edema, a return to isodensity of most of the previous low-density areas does not necessarily indicate a return to normal structure or function. This is not particularly unexpected and is probably analogous to the isodense phase of cerebral infarction. A contrast-enhanced study may be useful in such cases in which the clinical picture is inconsistent with an improved CT scan, as it may enhance some of these isodense areas. Furthermore, if the patient survives, longer-term follow-up may demonstrate a return of low-density

areas. Where feasible, an MR scan might be advisable to see if it is not more consistent with the clinical picture of a cerebrally deteriorating patient whose CT scan shows improvement.

#### REFERENCES

1. Kim KS, Weinberg PE, Suh JH, Ho SU. Acute carbon monoxide poisoning: computed tomography of the brain. *AJNR* **1980**;1:399-402
2. Aquilonius SM, Bergstrom K, Enoksson P, et al. Cerebral computed tomography in methanol intoxication. *J Comput Assist Tomogr* **1980**;4(4):425-428
3. Pizzolato P. Histochemical recognition of calcium oxalate. *J Histochem Cytochem* **1964**;12:333-336
4. Smith DE. Morphologic lesions due to acute and subacute poisoning with antifreeze (ethylene glycol). *Arch Pathol* **1951**;51:423-433
5. Friedman EA, Greenberg JB, Merrill JP, Dammin GJ. Consequences of ethylene glycol poisoning. Report of four cases and review of literature. *Am J Med* **1962**;32:891-902
6. Maier W. Cerebral computed tomography of ethylene glycol intoxication. *Neuroradiology* **1983**;24:175-177
7. Bobbitt WH, Williams RM, Freed CR. Severe ethylene glycol intoxication with multisystem failure. *West J Med* **1986**;144:225-228