

# Generic Contrast Agents

Our portfolio is growing to serve you better. Now you have a *choice*.



FRESENIUS  
KABI

[VIEW CATALOG](#)

# AJNR

## **Preoperative embolization of arteriovenous malformations with polyene threads: techniques with wing microcatheter and pathologic results.**

A Benati, A Beltramello, R Colombari, A Maschio, S Perini, R Da Pian, A Pasqualin, R Scienza, L Rosta and E Piovan

This information is current as  
of May 7, 2025.

*AJNR Am J Neuroradiol* 1989, 10 (3) 579-586  
<http://www.ajnr.org/content/10/3/579>

# Preoperative Embolization of Arteriovenous Malformations with Polyene Threads: Techniques with Wing Microcatheter and Pathologic Results

A. Benati<sup>1</sup>  
 A. Beltramello<sup>1</sup>  
 R. Colombari<sup>2</sup>  
 A. Maschio<sup>1</sup>  
 S. Perini<sup>1</sup>  
 R. Da Pian<sup>3</sup>  
 A. Pasqualin<sup>3</sup>  
 R. Scienza<sup>3</sup>  
 L. Rosta<sup>1</sup>  
 E. Piovan<sup>1</sup>  
 A. Scarpa<sup>2</sup>  
 G. Zamboni<sup>2</sup>

The technique with a wing microcatheter system and the pathologic aspects of 11 cerebral arteriovenous malformations (AVMs) surgically resected after embolization with polyene threads are reported. Embolization was performed once in eight patients and twice in three patients. Resected AVMs were submitted both to routine hematoxylin-eosin examination and to immunohistochemical workup in order to detect the type of immunologic response to thread emboli. In nine cases, 50% or more of the nidus was obliterated by the embolization. After embolization two patients developed reversible neurologic deficits. Pathologic specimens of resected AVMs demonstrated no vascular necrosis; however, a moderate inflammatory response could be seen, characterized by the presence of both mononuclear cells and foreign-body giant cells, associated with the absence of polymorphonuclear infiltrates. A granulomatous fibrotic process was identified that was present from the first month after embolization. Immunohistochemistry indicated that the immunologic response to thread emboli was cell-mediated, not humoral.

Embolization with the wing microcatheter with the use of polyene threads proved to be a safe and efficient system of embolization, as a preoperative procedure. Polyene threads are a nontoxic and biocompatible material that can be used as an embolic agent for brain AVMs.

Endovascular surgery carried out by interventionalists in specialized centers is now an effective therapeutic tool, both as a preoperative auxiliary procedure and, in selected cases, as the sole method of treatment. However, in the field of brain arteriovenous malformations (AVMs), present techniques cannot be considered fully satisfactory and many problems still persist. Dissatisfaction with both balloon catheter systems (risks of arterial rupture and vasospasm [1, 2]) and the impossibility of particulate embolization) and the most widely used embolic agent, bucrylate (abrupt solidification within the angioma, difficult calculation of the proper polymerization time [3], possible immediate or delayed hemorrhage after the embolization [4], and disappointing pathologic findings in resected specimens of previously embolized AVMs [5, 6]), led us to search for new and safer alternative materials of catheterization and embolization.

This article deals with our new microcatheter system and with the pathologic aspects of cerebral AVMs surgically resected after embolization with polyene threads.

## Materials and Methods

### *Embolization Technique*

Our technique is a modification of the Debrun balloon catheter system [7], with the distal end of the Silastic microcatheter completely open and exposed. To prepare this catheter a No. 17 latex balloon is put on a 2.5-French Silastic microcatheter.\* The tip of the balloon is then cut so that the tips of the microcatheter and balloon are aligned and the distal end of the Silastic microcatheter is completely exposed. With fine microsurgery forceps, five vertical

Received February 17, 1988; accepted after revision September 9, 1988.

A. Scarpa is supported by a scholarship from the Associazione Italiana per la Ricerca sul Cancro, Milan, Italy.

Presented at the annual meeting of the American Society of Neuroradiology, New York City, May 1987.

<sup>1</sup> Department of Neuroradiology, Verona University Hospital, Piazzale Stefani 1, 37126 Verona, Italy. Address reprint requests to A. Benati.

<sup>2</sup> Institute of Pathology, Verona University Hospital, Policlinico Borgo Roma, via Strada le Grazie, 37134 Verona, Italy.

<sup>3</sup> Department of Neurosurgery, Verona University Hospital, 37126 Verona, Italy.

**AJNR 10:579-586, May/June 1989**  
 0195-6108/89/1003-0579

© American Society of Neuroradiology

\* Ingenor, Paris, France.

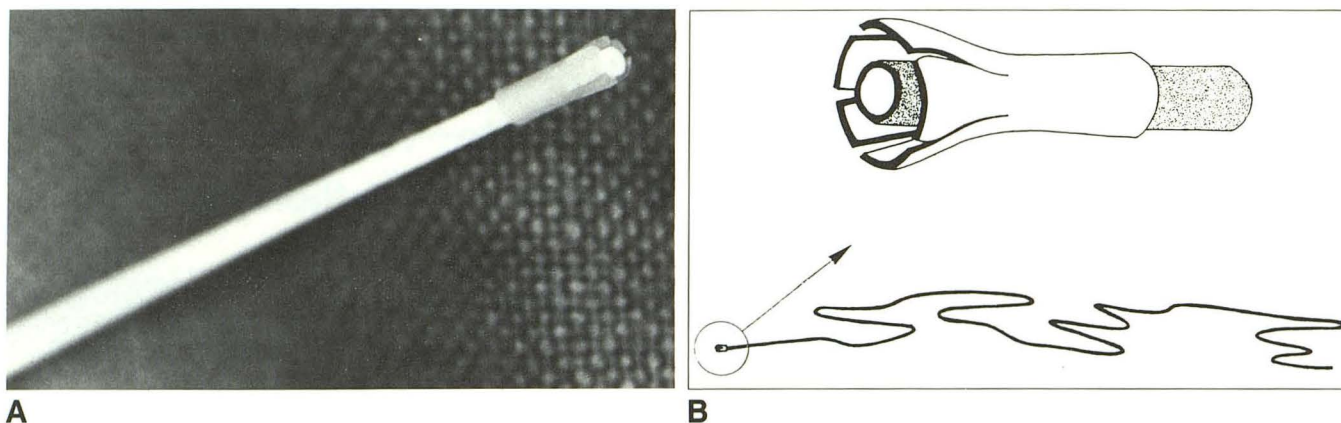


Fig. 1.—A, Microphotograph.

B, Drawing of wing microcatheter; magnified circle shows small latex wings surrounding tip of Silastic microcatheter, in which distal end of catheter is completely exposed.

cuts are made on the walls of the balloon surrounding the catheter as far as its neck. At the end of the procedure, five small latex wings have been created around the tip of the catheter (Fig. 1). These "floating" wings increase the area exposed to the bloodstream, and consequently the traction of the microcatheter along the direction of blood flow is strengthened [8, 9].

Intravascular navigation is flow-dependent and is obtained by a propulsion chamber. The microcatheter is slipped into an outer 6-French polyethylene coaxial catheter.<sup>†</sup> Once the microcatheter has reached the desired position, superselective angiograms of the vascular feeders are obtained without blocking the blood flow, similar to the system of Rufenacht and Merland [1, 2]. Manual injections of 1–2 ml of contrast medium<sup>‡</sup> are adequate, with digital subtraction angiographic equipment, to obtain reliable maps of the AVM and its feeders. As embolic agents, both fluids and particles can be used with our multipurpose microcatheter; therefore, it is suitable both for AVM embolization and for injection of chemotherapeutic agents. We have used the wing microcatheter for isobutyl 2-cyanoacrylate (IBCA) delivery, but our experience is based mainly on the use of threads, which can be injected through this catheter as well as through other ones (Pursil<sup>§</sup> or Tracker<sup>||</sup>). Polyfilament polyene 3–0 threads (0.2 mm in diameter)<sup>¶</sup> cut 1.5–2 mm long are fitted into 22-gauge catheter needles<sup>\*\*</sup> loaded (five emboli each) before the embolization procedure and ready for use. The loaded catheter needle is connected to a 2.5-ml syringe and inserted into the proximal end of the microcatheter. Emboli are then discharged into the artery by 1.5–2 ml of saline. The great majority of threads reach the nidus of the AVM, and a progressive embolization is achieved under continuous angiographic control and neurologic observation in the alert patient. Because this technique results in a progressive embolization, the higher-flow shunts are the first to close, followed by the slower-flow ones. Only when shunt flow is markedly reduced, at the very end of the procedure, can a few threads be deposited on the walls of the arterial pedicles, very close to the AVM. At the end of each procedure, superselective angiography of the embolized feeder is carried out by means of the same microcatheter.

Once one feeder is embolized, the same microcatheter can be moved to other feeders, without the need for complete withdrawal; in this way, many pedicles can be embolized in the same session. Control angiograms with the outer coaxial polyethylene catheter are obtained at the end of each embolization, and, if necessary, angiography during various phases of the procedure can be performed without removing the microcatheter.

#### Patient Population

Forty-two patients with symptomatic brain AVMs underwent 54 embolization procedures carried out with our wing microcatheter. The indication for embolization was the presence of a "critical" (or "eloquent") AVM, defined as a vascular malformation adjacent to or within critical areas of the brain for which surgical removal alone could result in possible permanent neurologic damage [10, 11]. History of a previous hemorrhage was an important criterion for the procedure.

Clinical status was tested before and after embolization. For each embolization the estimated amount of nidus obliteration was recorded.

On the basis of the results of embolization, the patients then underwent surgery or radiosurgery or were scheduled for further embolization sessions.

#### Pathology

The tissues were fixed in 10% formalin and embedded in paraffin. From each block 5- $\mu$ m-thick sections were obtained for routine hematoxylin-eosin examination and for immunohistochemistry.

In evaluating morphologic changes of vascular walls secondary to embolization with polyene thread, we excluded those produced by refractile foreign particles commonly introduced in AVMs during cerebral angiography [12].

**Immunohistochemistry.**—To characterize the nature of inflammatory cells eventually present around polyene threads, we analyzed immunohistochemically the paraffin sections obtained for routine hematoxylin-eosin examination. Every section had been treated with a series of antibodies reactive in routinely fixed paraffin-embedded tissue, including LN1, MB2, UCHL1, and antivimentin antibodies, that discriminate between B and T lymphocytes and recognize fibroblasts. Specifically, LN1 [13] is a murine monoclonal antibody of IgM class

<sup>†</sup> PBN, Soeborg, Denmark.

<sup>‡</sup> Iopamiro 300, Bracco Industria Chimica, Milan, Italy.

<sup>§</sup> Balt, Montmorency, France.

<sup>||</sup> Target Therapeutics, Los Angeles, CA.

<sup>¶</sup> Howmedica, Hamburg, W. Germany.

<sup>\*\*</sup> Venflon 2 Viggo, Helsingborg, Sweden.

directed against a cell-surface sialoantigen. In lymph nodes LN1 was found to have a remarkable specificity for germinal center cells and a weak reaction in the B-cell mantle zones. Within germinal centers it stained all cells with the exception of macrophages. MB2 [14] is a murine monoclonal antibody of IgG1 subclass that recognizes a neuroaminidase-resistant 28-kd antigen, strongly expressed in the cytoplasm of B cells and weakly on T cells. UCHL1 is an IgG2a murine monoclonal antibody that recognizes a 185-kd determinant on T cells, some macrophages, and polymorphonuclear (PMN) leukocytes [15]. Vimentin is the predominant intermediate filament of mesenchymal cells, first characterized in chick embryo fibroblasts [16]. It is regularly present in fibroblasts and their derived neoplasms, as well as in nevus cells, malignant melanomas [17], and hematopoietic cells [18]. Mouse antisera LN1 and MB2 were obtained from Biotest Diagnostic,<sup>††</sup> UCHL1 from Dako,<sup>‡‡</sup> and antiserum against vimentin from Behring.<sup>§§</sup>

An indirect immunoperoxidase technique, peroxidase-antiperoxidase (PAP) [19], was used to detect all antigens. Briefly, deparaffinized sections were soaked in methanol containing 0.3% hydrogen peroxide to prevent nonspecific staining due to endogenous peroxidase. After a 20-min incubation with 1:10 diluted normal swine serum (Dako), the sections were placed in a moist chamber and covered with the appropriately diluted antisera (LN1, pure; MB2, pure; UCHL1, 1:10; and vimentin, 1:5) for 60 min.

The sections treated with antiserum were then washed three times in phosphate-buffered saline (PBS), re-incubated in a moist chamber for 30 min with antimouse IgG swine serum (1:50, Dako), washed with PBS, and re-incubated in a moist chamber with PAP solution (1:200, Dako) for 30 min.

The final reaction product was produced by incubation with 3-3'-diaminobenzidine<sup>||</sup> and hydrogen peroxide in TRIS buffer as previously described [20].

The histopathologic evaluation was carried out without the knowledge of the length of the interval after embolization, the radiologically estimated percentage of the malformation nidus obliterated by the embolization, or the clinical status of the patient.

## Results

### Clinical

Of the 42 patients embolized in 54 procedures with polyene threads by means of our Silastic microcatheter, 26 patients are still under treatment, while treatment has ended for 16 patients. In fact, partial obliteration of the lesion permitted surgery in 11 patients (Figs. 2 and 3). Five malformations were reduced to less than 2 cm in diameter, a size suitable for radiosurgery (a single session of stereotactically focused external-beam irradiation) [21].

Operated patients were particularly important in order to study the pathologic aspects of resected AVMs previously embolized with polyene threads (Table 1). The mean age of the 11 patients operated on was 34 years (range, 10–49). AVMs were always located in critical areas of the brain (left, six; right, five). Three patients had had previous hemorrhages. Seizures were present in six patients, headaches in four. Only one patient had a neurologic deficit, a left homonymous hemianopia resulting from previous bleeding.

Embolization was performed only once in eight patients and twice in three. In nine patients 50% or more of the nidus was obliterated by the embolization. The interval between embolization(s) and surgery ranged from 4 to 50 weeks.

Intracranial navigation with the wing microcatheter failed twice. Only two complications, totally reversible, minor deficits, were noticed with our microcatheter and embolization with threads (homonymous hemianopia completely resolved in 1 day in both cases). No deaths or permanent neurologic deficits were observed with our technique.

In all cases in which a significant decrease (50% or more) in the size of the AVM was obtained (nine of 11), the surgeon believed that preoperative embolization had considerably helped the surgical removal of the angioma, which would have been very risky in five cases without prior embolization. Surgery caused two neurologic deficits (one quadrantanopia and one homonymous hemianopia) that persisted 4–6 months later. In one patient seizures significantly worsened; in another, homonymous hemianopia from previous bleeding persisted unmodified. The seven remaining patients were completely normal at postoperative follow-ups 6 months after the operation.

### Pathologic

Among the 11 resected AVMs previously embolized with threads, eight AVMs (cases 1–8) embolized only once were considered of particular interest because we attempted to establish a sequence of histopathologic events chronologically related to the embolization. The AVMs in this subgroup were resected 4–30 weeks after the last embolization with threads.

Routine sections of AVMs showed polyene threads in a varying, but frequently small, number of vascular channels. The threads appeared as a colorless material, birefringent in polarized light, and when seen together in multiple fascicles, mimicked a beehive in transverse sections (Fig. 4).

In tissues examined beginning at 6 weeks after embolization therapy, every polyene fiber was surrounded by varying amounts of granulation tissue, with a rich component of mononuclear cells, spindle-shaped cells, and foreign-body giant cells interspersed with many small capillary vessels.

The mononuclear inflammatory infiltrate consistently diminished in tissues resected 12 weeks or more after embolization. After this time the polyene threads were surrounded by a thin cushion of connective tissue with a few mononuclear inflammatory cells and foreign-body giant cells that filled and completely occluded the vascular lumen. In only one vessel (case 7) was a cleft seen between the vascular wall and this connective cushion (Fig. 5).

Necrosis of vascular channel walls was never found, nor were threads discovered in the neuroglial parenchyma that commonly lies in the interstices of the vascular channels. In four cases (cases 1–3 and 5), aggregates of PMN infiltrates were present in the wall of some AVM channels, but only in case 1 were a few leukocytes seen around the polyene threads. In the other three cases (cases 2, 3, and 5), PMN infiltrates were far from the thread emboli.

<sup>††</sup> Biotest Diagnostic, Frankfurt, W. Germany.

<sup>‡‡</sup> Dako, Glostrup, Denmark.

<sup>§§</sup> Behring, Frankfurt, W. Germany.

<sup>||</sup> Sigma Chemical Co., St. Louis, Mo.

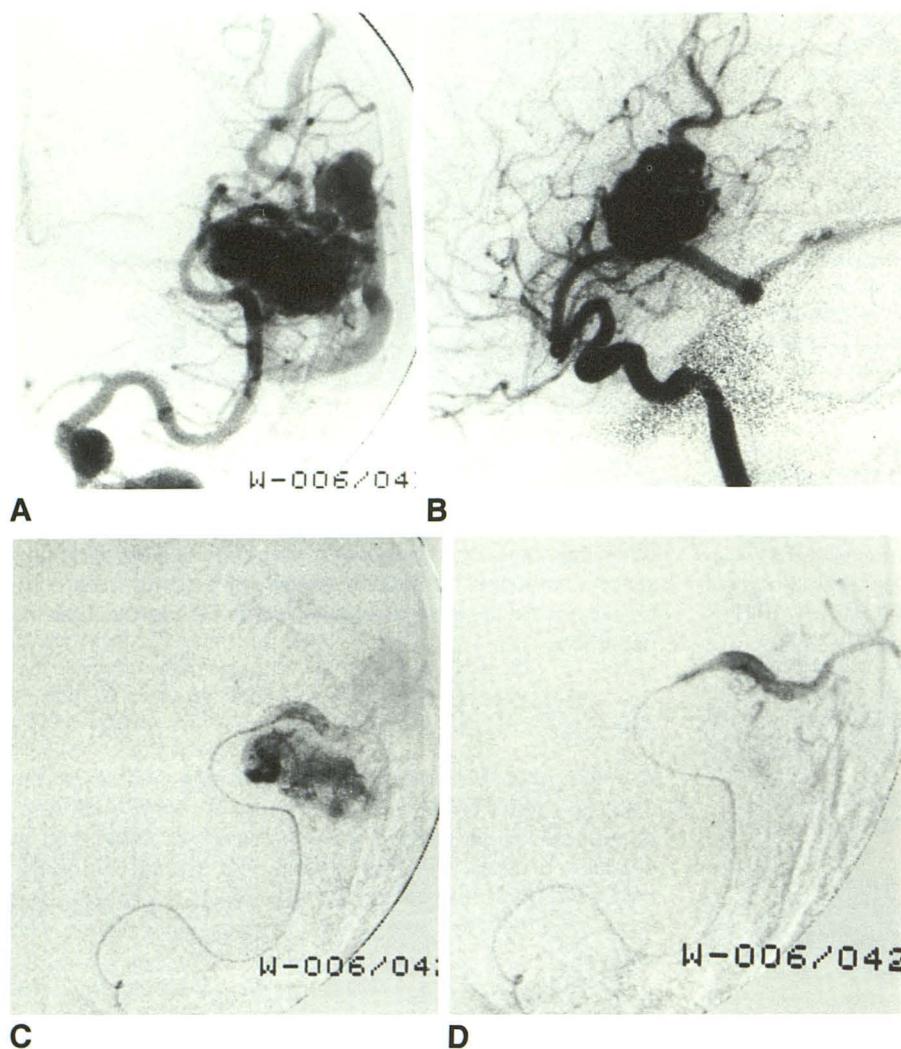


Fig. 2 (A-D).—Case 3.

A and B, Medium-sized left temporo-parietal arteriovenous malformation (AVM) fed by three branches of left middle cerebral artery.

C and D, Anteroposterior angiograms before and after embolization of angular artery with polyene threads (125 threads). Intrinsic feeders to AVM and AVM nidus are obliterated, while the distal vessel remains patent.

E-H, See opposite page.

**Immunohistochemistry.**—Immunohistochemical methods permitted us to characterize the mononuclear infiltrate, previously described. Around polyene fibers we always found a great number of T lymphocytes, UCHL1-positive (Fig. 6), and a variable number of spindle-shaped vimentin-positive fibroblasts. We never found any LN1- and MB2-positive cells, markers of B lymphocytes.

## Discussion

In therapeutic embolization of spinal, head and neck, and intracranial vascular abnormalities, embolization techniques have included particulate embolizations and balloon detachments. Various proposed techniques for embolization of brain AVMs have proved unsatisfactory, and as a result a "gold standard" of proved efficacy and safety does not exist.

Recently, various authors have tried to avoid the risks of vascular damage (overdistension, hemorrhage, vasospasm) linked to the inflation of the balloon attached to the tip of the microcatheter [1, 2]. Above all, many questions exist concerning the best embolic agent for clinical use. Bucrylate,

being fluid, would have the ideal properties for use in embolotherapy of cerebral AVMs, and various other substances [22, 23] are under evaluation (Strother CM and Hilal SK, personal communications). Bucrylate is still the most common embolic agent for this type of disease [3, 7, 24–27]. Nevertheless, many problems arise as to both its practical use and its long-term consequences. Regarding its practicality, the abrupt solidification of IBCA in the AVM vasculature and the complicated calculation of the right polymerization time make progressive embolization impossible. Furthermore, the catheter has to be withdrawn as soon as possible to avoid "in situ" gluing. Not infrequently the arterial feeder or the venous outlets are blocked, with possibly unfavorable clinical consequences. Regarding the long-term pathologic changes induced by bucrylate, we totally agree with Vinters et al. [4]: "It is important to know the fate of a substance that will persist in human tissues for months or years."

Long-term pathologic follow-up of brain AVMs treated by embolization with bucrylate has shown patchy transmural necrosis of portions of vessels treated days or weeks before with IBCA embolotherapy [5, 28]. The discovery of extravas-

Fig. 2 (E-H).—Case 3 (cont.).

E and F, After embolization of second feeder (posterior parietal artery), small part of AVM fed by posterior temporal branch still persists. In oblique view (F) this feeder appears too narrow to be selectively catheterized (arrows).

G and H, Postoperative control angiograms show complete resection of AVM.

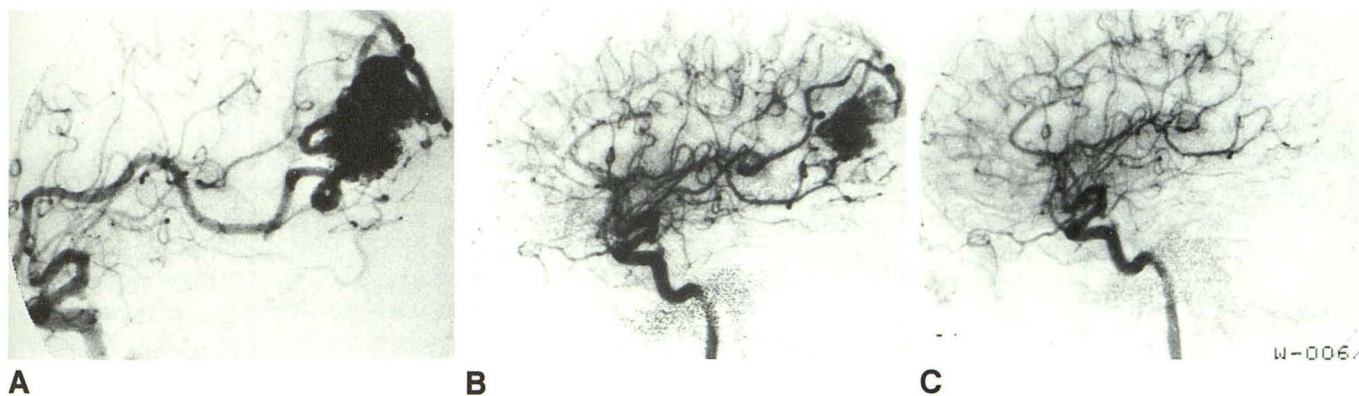
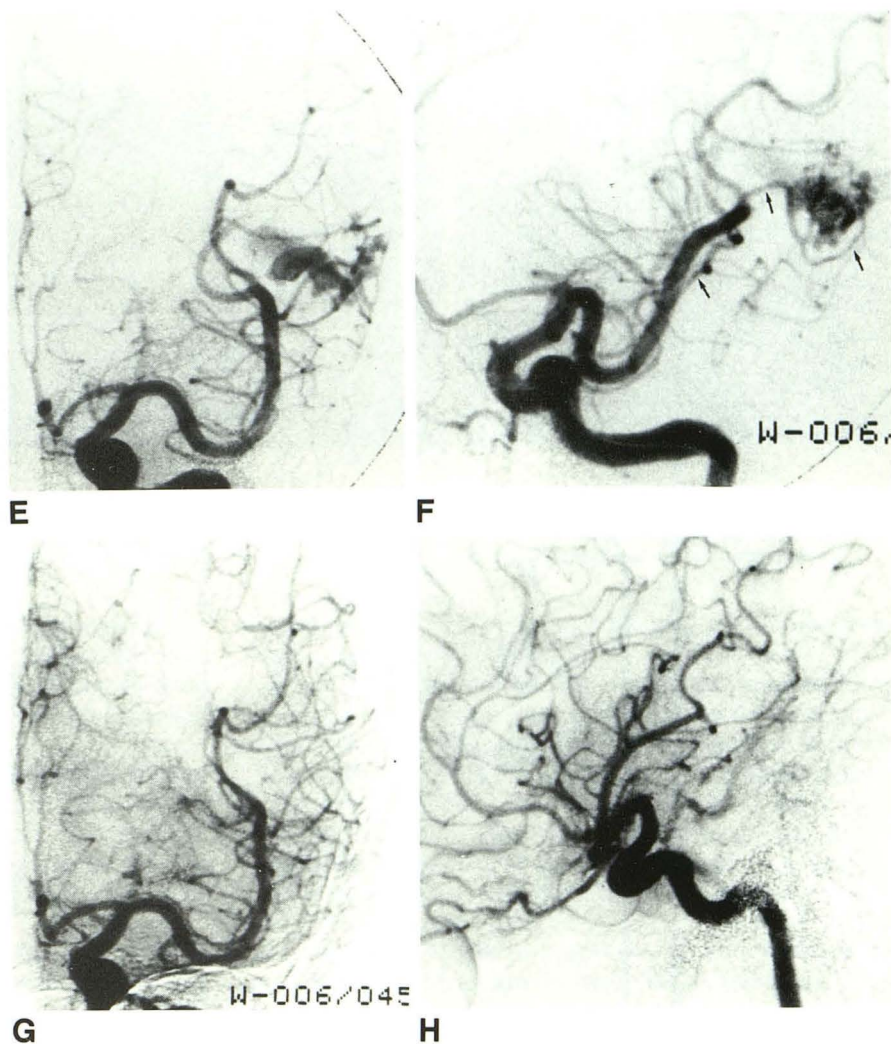


Fig. 3.—Case 7.

A, Medium-sized left posterior parietal arteriovenous malformation (AVM) fed by angular and posterior parietal arteries.

B, Final angiogram after embolization with wing microcatheter and polyene threads of dilated angular artery. Significant decrease of both AVM size and embolized feeder.

C, Postoperative control angiogram. Complete resection of AVM.

TABLE 1: Summary of Clinical Data and Pathologic Findings in Patients with Arteriovenous Malformations (AVMs) Who Had Surgery After Embolization with Polyene Polyester Threads

Case No.	Age	Gender	Location of AVM	Previous Hemorrhage	Clinical Status		No. of Embolizations (% Occlusion)	Interval Between Embolization and Surgery (weeks)	Mono-nuclear Cells	Giant Cells	Fibrosis	Polymorpho-nuclear Infiltrate	Postoperative Follow-up (months)
					Preembolization	Postembolization							
1	36	F	R parieto-occipital	Yes	L homonymous hemianopia	No changes	1 (50)	4	Rare	Present	Absent	Rare	Unchanged (6)
2	42	M	L temporal	No	Seizures	Normal	1 (50)	5	Rare	Present	Present	Present far from emboli	Normal (6)
3	35	M	L temporo-parietal	No	Seizures	Normal	1 (70)	5	Rare	Present	Present	Present far from emboli	Normal (6)
4	37	F	R occipital	No	Headaches	L homonymous hemianopia resolved in 1 day	1 (75)	6	Rare	Conspicuous	Present	Absent	Normal (6)
5	32	F	R occipital	No	Headaches	L homonymous hemianopia resolved in 1 day	1 (80)	6	Rare	Present	Present	Present far from emboli	Normal (6)
6	32	F	L frontal	No	Seizures, headaches	Normal	1 (40)	12	Present	Present	Present	Absent	Normal (6)
7	45	M	L parietal	Yes	Seizures	Normal	1 (60)	18	Present	Present	Conspicuous	Absent	Normal (6)
8	10	M	R parietal	No	Headaches	Normal	1 (95)	30	Absent	Present	Conspicuous	Absent	Normal (6)
9	49	M	L temporal	Yes	Normal	Normal	2 (90)	22, 6	Present	Conspicuous	Present	Absent	R homonymous hemianopia (4)
10	23	M	L frontal	No	Seizures	Normal	2 (45)	12, 8	Present	Present	Present	Absent	Seizures significantly worsened (6)
11	36	M	R parietal	No	Seizures	Normal	2 (85)	50, 25	Rare	Present	Conspicuous	Absent	L quadrantanopia (6)

Note.—Vessel wall necrosis was absent in all patients.

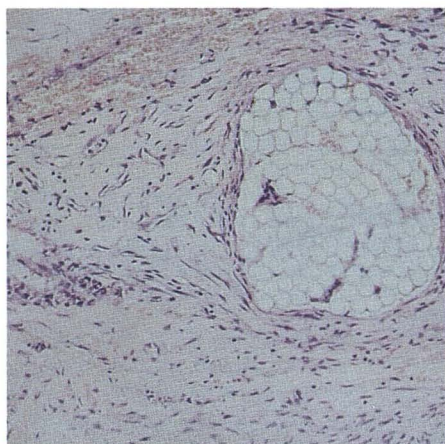


Fig. 4.—Vascular channel embolized by polyene thread, surrounded by highly vascularized granulation tissue.

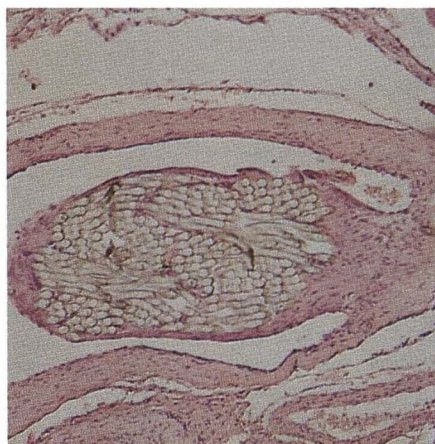


Fig. 5.—Case 7. C-shaped cleft between vascular wall and fibrotic granulation tissue surrounding polyene threads. (H and E,  $\times 100$ )

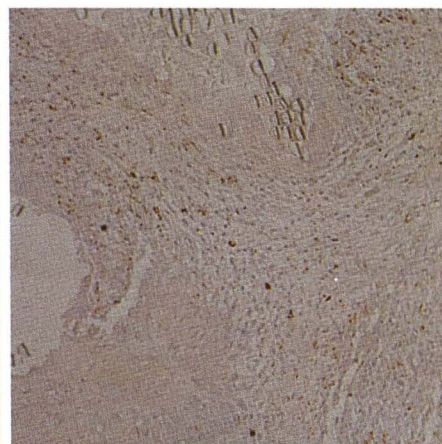


Fig. 6.—UCHL1-positive lymphocytes are evidenced as brown cytoplasmic cells (UCHL1 antiserum). (Peroxidase-antiperoxidase,  $\times 100$ )

cular bucrylate within the neuroglial parenchyma would speak in favor of its possible migration from the intravascular compartment. Delayed hemorrhage after therapeutic embolization with bucrylate can be explained partly by this mechanism [4].

In this report the pathologic changes observed in cerebral AVMs embolized with polyene threads and surgically resected 4 weeks to 1 year later are described. The hallmarks of the inflammatory response to polyene threads are the presence of both mononuclear cells and foreign-body giant cells and the absence of PMN infiltrates.

The presence or absence of PMN infiltrates is very important because it is the only reproducible parameter that is used to evaluate the presence or absence of wall necrosis. In fact, as the AVM is, by definition, a lesion in which there is a variable amount of elastica from vessel to vessel [29], the destruction of this imperfect elastica by the inflammatory reaction cannot be assessed accurately [28]. Thus, we considered the classical histochemical stains for the components of vascular wall to be inappropriate (trichrome, Weigert's for elastin, or silver impregnation for reticulin). Similarly, experimental studies on the effects of any embolizing material in normal cerebral vessels may have relatively little to contribute to settling this specific issue [5].

Differing from what has been reported for IBCA [4–6, 28], we found PMN infiltrates in the vascular wall close to polyene threads only in one patient (case 1). The AVM in this patient was resected at the shortest interval after embolization (4 weeks). This finding would speak in favor of a release of PMN chemotactic factors soon after embolization. However, we did not find this response to extend beyond 4 weeks. Vascular necrosis associated with PMN infiltrates was never found in the pathologic specimens of the remaining patients who underwent surgery 5–50 weeks after the embolization. In three other patients (cases 2, 3, and 5), PMN infiltrates were present in the wall of AVM channels far from the thread emboli. This inflammatory reaction may have occurred in response to necrosis, which may in turn have been a function of occlusion of the major blood supply to the AVM, similar to

resected AVMs after balloon embolizations, in which no embolic substance was injected [30].

Another important factor that should be stressed is the phenomenon of revascularization. This well-known event, frequently observed during inflammation also, is confirmed by "in vitro" studies in which lymphocytes, macrophages, platelets, prostaglandin E, collagen, and products of cellular rexis [31, 32] are seen. In all patients examined, highly vascularized granulation tissue was observed surrounding polyene threads (Fig. 4). In our opinion, these small capillary vessels are not able to reestablish the AVM nidus. However in case 7, where the AVM was excised 4 months after embolization, a C-shaped cleft was seen between the thread emboli enveloped by endothelium and the fibrosclerotic wall of only one partially obstructed artery. Viable-appearing RBCs could also be seen. This finding suggests that threads adhere to the endothelium of vessels that are larger than the emboli. Adherence is noted, particularly at sites of turbulence in branching vessels or in vessels with high vascular flow. Similar phenomena were also reported to occur with other embolic agents [4, 22, 33]. On the other hand, as long as a tissue remains viable it will have a blood supply [33]; therefore, a tissue made ischemic and fibrotic by therapeutic embolization, but which still remains viable, will reestablish, to some degree, its blood supply. Our more recent leaning is toward shorter intervals between embolization and surgery in order to avoid the occurrence both of recanalization and of the hemodynamic changes caused by redistribution of blood flow within AVM vasculature.

In human tissue the analysis of cellular population and in particular of lymphocytes has been greatly facilitated by the availability of monoclonal antibodies directed against specific cellular antigens and against lymphoid differentiation antigens. However, until recently, cryostat sections have been required because most lymphoid antigens have not survived conventional fixation and processing. This has imposed a serious limitation on the study of lymphocyte activities in inflammatory and neoplastic tissues, since most routine histologic tissues arrive at the laboratory in fixative. Recently, a new generation

of monoclonal antibodies has been described that are capable of assigning a B-cell or T-cell derivation to a lymphoid population in fixed tissues. The antibodies LN1 [13] and MB2 [14] recognize epitopes on normal and neoplastic B cells. The monoclonal antibody UCHL1 shows specificity for cells of T-cell derivation [34], and the well-known antivimentin antibody reacts with this protein expressed by fibroblasts.

The application of this panel of antibodies to embolized AVMs allowed us to investigate the sequence of pathogenetic events related to the presence of polyene threads within AVM vasculature. The absence of LN1- and MB2-positive cells around polyene threads permitted us to state that B lymphocytes are not involved in this inflammatory process; in other words, the immunologic process occurring in response to this type of foreign substance is not a humoral one. On the contrary, many UCHL1-positive T lymphocytes and vimentin-positive fibroblasts are present. As in other better known granulomatous inflammatory responses, we can postulate T lymphocytes produce lymphokines-activating macrophages that synthesize interleukin 1 and fibronectin [35]. Interleukin 1 again activates T lymphocytes and fibronectin promotes fibroblast recruitment, attachment, and proliferation in the granulomas [36]. The final result would be a self-maintaining process reaching the fibrotic stage.

Embolization by means of our microcatheter system with polyene threads proved to be a useful and reliable tool to achieve, in conjunction with surgery, complete cure in a significant number of critical AVMs.

Morbidity and technical failures are both so low as to justify the embolization as the first step in the treatment plan of the majority of critical AVMs. Pathologic studies of brain AVMs resected after embolization have demonstrated the absence of angioneurosis. A moderate inflammatory response can be seen that tends to be alleviated by the fourth week.

The immunologic response to thread emboli is cell-mediated, not humoral. It gives origin to a self-maintaining granulomatous-fibrotic process, which begins after the first month and peaks at the third month. The threads used in our procedures are nonreabsorbable, biocompatible, nontoxic, and useful as embolizing agents for brain AVMs.

## REFERENCES

- Rufenacht D, Merland JJ. A new and original microcatheter system for hyperselective catheterization and endovascular treatment without risk of arterial rupture. *J Neuroradiol* 1986;13:44-54
- Rufenacht D, Merland JJ. Superselective catheterization using very flexible, formed catheters. *Acta Radiol [Suppl]* (Stockh) 1987;369:600-602
- Vinuela F, Fox AJ. Interventional neuroradiology and the management of arteriovenous malformations and fistulas. *Neuroradiology* 1983;1:131-154
- Vinters HV, Galil KA, Lundie MJ, Kaufmann JCE. Long-term pathological follow-up of cerebral arteriovenous malformations treated by embolization with bucrylate. *N Engl J Med* 1983;314:477-483
- Vinters HV, Galil KA, Lundie MJ, Kaufmann JCE. The histotoxicity of cyanoacrylates. Review article. *Neuroradiology* 1985;27:279-291
- Klara PM, George ED, McDonnell DE, Pevsner PH. Morphological studies of human arteriovenous malformations. Effects of isobutyl 2-cyanoacrylate embolization. *J Neurosurg* 1985;63:421-425
- Debrun G, Vinuela F, Fox AJ, Drake CG. Embolization of cerebral arteriovenous malformations with bucrylate. Experience of 46 cases. *J Neurosurg* 1982;56:615-627
- Benati A, Beltramello A, Maschio A, Perini S, Rosta L, Piovani E. Combined embolization of intracranial AVMs with a multi-purpose mobile-wing microcatheter system. Indications and results in 71 cases (abstr). *AJNR* 1987;8:938-939
- Benati A, Beltramello A, Maschio A, Perini S, Rosta L, Piovani E. Endovascular treatment of intracranial AVMs. Combined embolization with a multi-purpose mobile-wing microcatheter system. *J Neuroradiol* 1987;14:99-113
- Da Pian R, Pasqualin A, Scienza R, Vivenza C. Microsurgical treatment of ten arteriovenous malformations in critical areas of cerebrum. *J Microsurg* 1980;1:305-320
- Spetzler RF, Martin NA. A proposed grading system for arteriovenous malformations. *J Neurosurg* 1986;65:476-483
- Vinters HV, Kaufmann JC, Drake CG. "Foreign" particles in encephalic vascular malformations. *Arch Neurol* 1983;40:221-225
- Epstein AL, Marder RJ, Winter JN, Fox RI. Two new monoclonal antibodies (LN-1, LN-2) reactive in B5 formalin fixed, paraffin embedded tissues with follicular centre and mantle zone human B lymphocytes and derived tumors. *J Immunol* 1984;133:108-136
- Hall PA, D'Ardenne AJ, Butler MG, Habeshaw JR, Stansfeld AG. New marker of B lymphocytes, MB2: comparison with other lymphocyte subset markers active in conventionally processed tissue sections. *J Clin Pathol* 1987;40:151-156
- Smith SH, Brown MH, Rowe D, Callard RE, Beverley PCL. Functional subset on human helper-inducer cells defined by a new monoclonal antibody, UCHL1. *Immunology* 1986;58:63-70
- Lazarides E. Intermediate filaments as mechanical integrators of cellular space. *Nature* 1978;283:249-256
- Miettinen M, Lehto VP, Virtanen I. Presence of fibroblast-type intermediate filaments (vimentin) and absence of neurofilaments in pigmented nevi and malignant melanomas. *J Cutan Pathol* 1983;10:188-192
- Denk H, Krepler R, Artlieb U, et al. Proteins of intermediate filaments: an immunohistochemical and biochemical approach to the classification of soft tissue tumors. *Am J Pathol* 1983;110:193-208
- Sternberger L. *Immunocytochemistry*. Englewood Cliffs, NJ: Prentice Hall, 1974
- Chilosi M, Bonetti F, Iannucci A. Carcinogenic 3-3'-diaminobenzidine. *Am J Clin Pathol* 1981;75:638
- Leksell L. *Stereotaxis and radiosurgery: an operative system*. Springfield, IL: Thomas, 1971
- Quisling RG, Mickle JP, Ballinger WB, Carver CC, Kaplan B. Histopathologic analysis of intraarterial polyvinyl alcohol microemboli in rat cerebral cortex. *AJNR* 1984;5:101-104
- Lee DH, Wriedt CHR, Lylyk P, et al. Thrombotic embolization agents: tests in pig rete. In: Calabrò A, Leonardi M, eds. *Computer aided neuroradiology. Proceedings of the XIVth congress of the European Society of Neuroradiology*. Rome: CIC, 1987:185-187
- Kerber C. Intracranial cyanoacrylate: a new catheter therapy for arteriovenous malformation. *Invest Radiol* 1975;10:536-538
- Cromwell LD, Harris AB. Treatment of cerebral arteriovenous malformations. A combined neurosurgical and neuroradiological approach. *J Neurosurg* 1980;52:705-708
- Drake CG. Arteriovenous malformations of the brain. The option for management. *N Engl J Med* 1983;309:308-310
- Picard L, Moret J, Lepoivre J. Endovascular treatment of intracerebral arteriovenous angiomas. Technique, indications and results. *J Neuroradiol* 1984;11:9-28
- Vinters HV, Debrun G, Kaufmann JC, Drake CG. Pathology of arteriovenous malformations embolized with isobutyl-2-cyanoacrylate (bucrylate). Report of two cases. *J Neurosurg* 1981;55:819-825
- Stehbens WE. *Pathology of the cerebral blood vessels*. St Louis: Mosby, 1972
- Lamman TH, Martin NA, Vinters HV. The pathology of encephalic arteriovenous malformations treated by prior embolotherapy. *Neuroradiology* 1988;30:1-10
- Polverini PJ, Cotran RS, Gimbrone MA, Unanue ER. Activated macrophages induce vascular proliferation. *Nature* 1977;269:804-805
- Montesano R, Orci L, Vassalli P. In vitro rapid organization of endothelial cells into capillary-like networks is promoted by collagen matrices. *J Cell Biol* 1983;97:1648-1652
- Strother CM, Laravuso R, Rappe A, Su SL, Northern K. Glutaraldehyde cross-linked collagen (GAX): a new material for therapeutic embolization. *AJNR* 1987;8:509-515
- Norton AJ, Ramsay AD, Smith SH, Beverley PCL, Isaacson PG. Monoclonal antibody (UCHL-1) that recognizes normal and neoplastic T cells in routinely fixed tissues. *J Clin Pathol* 1986;39:399-405
- Ruoslahti E, Engvall E, Hayman EG. Fibronectin: current concepts of its structure and function. *Coll Relat Res* 1981;1:95-128
- Rennard SI, Bitterman PB, Crystal RG. Mechanisms of fibrosis. *Am Rev Respir Dis* 1984;130:492-496