

Generic Contrast Agents

Our portfolio is growing to serve you better. Now you have a *choice*.



[VIEW CATALOG](#)

AJNR

The Acetazolamide Challenge: Imaging Techniques Designed to Evaluate Cerebral Blood Flow Reserve

Jeffrey Rogg, Michael Rutigliano, Howard Yonas, David W. Johnson, Susan Pentheny and Richard E. Latchaw

This information is current as of May 17, 2025.

AJNR Am J Neuroradiol 1989, 10 (4) 803-810
<http://www.ajnr.org/content/10/4/803>

The Acetazolamide Challenge: Imaging Techniques Designed to Evaluate Cerebral Blood Flow Reserve

Jeffrey Rogg¹
Michael Rutigliano²
Howard Yonas³
David W. Johnson⁴
Susan Pentheny⁴
Richard E. Latchaw³

Cerebral blood flow was analyzed by the stable xenon (Xe)/CT scanning technique in 29 patients with significant vascular lesions before and after administration of an acetazolamide (Diamox) vasodilatory challenge. Three response types were identified: I, normal flow before Diamox with flow augmentation after Diamox; II, low flow before Diamox with flow augmentation after Diamox; and III, low or normal flow before Diamox with no augmentation or decreased flow after Diamox. Twenty-four percent of the patients studied qualified for category III. We believe that patients in this category represent a group of individuals without blood flow reserve whose clinical management should include careful consideration of their hemodynamic status.

The Xe/CT scanning technique with the addition of Diamox flow challenge is a clinically accessible and effective method for assessing cerebral blood flow and blood flow reserve.

The development of a clinically accessible means to identify patients with neurologic symptoms caused by transient focal or global low cerebral blood flow (CBF) has important potential therapeutic implications [1–3]. Signs and symptoms of decreased cerebrovascular reserves and episodic low CBF are generally non-specific and may be difficult to recognize [4]. Angiography is imprecise in establishing the diagnosis because this technology is unable to provide the physiologic information necessary to assess the adequacy of primary or collateral regional blood supply [5]. Ideally, this analysis is performed by positron emission tomography (PET), which requires the measurement of both CBF and metabolism [6, 7]. PET is, however, available at relatively few centers. This article describes the use of stable xenon (Xe)/CT performed before and after a vasodilatory challenge to identify patients with low cerebral blood flow and blood flow reserve.

The strategy we followed was derived in part from PET studies that determined that the cerebral arteries maintain CBF in response to decreased perfusion pressure by dilatation [2]. After vessels are maximally dilated, any further compromise in perfusion pressure results in a progressive decrease in blood flow and an accompanying increase in oxygen extraction. When this condition, termed "misery perfusion" [3], has been achieved, additional vasodilatory challenges would not be expected to augment flow. When CBF falls below 20 ml/100 g/min in normal cortical tissue, metabolism and neurologic function become compromised as the regional oxygen and glucose supply to the brain is expended [8, 9].

Although local cerebral blood flow values may be reduced by proximal vascular compromise and inadequate supply, CBF can also be reduced by decreased metabolic demand caused by either neuronal loss or deafferentation. Therefore, a single measurement of CBF, regardless of the method—Xe-133, single photon emission CT (SPECT), or stable Xe/CT—does not give nonspecific information in this regard. However, the addition of a second measurement obtained during a vasodilatory challenge can assess whether territorial reserves have been compromised. That is, CBF augmentation would not be expected in regions that already

This article appears in the July/August 1989 issue of *AJNR* and the September 1989 issue of *AJR*.

Received June 24, 1988; revision requested August 22, 1988; revision received November 11, 1988; accepted December 5, 1988.

¹ Department of Radiology, Brown University School of Medicine, Rhode Island Hospital, Providence, RI 02902.

² University of Pittsburgh School of Medicine, Pittsburgh, PA 15213.

³ Department of Radiology and Neurological Surgery, University of Pittsburgh School of Medicine, Pittsburgh, PA 15213. Address reprint requests to H. Yonas.

⁴ Department of Radiology, University of Pittsburgh School of Medicine, Pittsburgh, PA 15213.

AJNR 10:803–810, July/August 1989
0195–6108/89/1004–0803

© American Society of Neuroradiology

TABLE 1: Summary of Clinical Histories, Significant Vascular Anatomy by Doppler or Angiographic Investigation, and Categorization by Xe Diamox Analysis in 29 Patients

Case No.	Clinical History	Significant Vascular Anatomy	Age	Pre-pCO ₂ /Post-pCO ₂	Baseline Cerebral Blood Flow	Xe Diamox	Type*
1	L hemiparesis expressive aphasia	R MCA occlusion	59	39/30	Focal R MCA distr.; low flow	No change	III
2	L facial and upper extremity weakness; symptoms related to decreased blood pressure	R ICA occlusion; bilateral moderate VA stenosis	78	38/30	Diffuse low	Diffuse increase	II
3	Transient L hemisphere symptoms	L ICA occlusion	55	31/27	Focal L ICA distr.; low flow	No change	III
4	L hemisphere TIAs after endarterectomy		74	38/32	Normal	Diffuse increase	I
5	L TIA	R & L VA stenosis	72	33/30	Diffuse low	Diffuse increase	II
6	Aphasia	R ICA occlusion	64	32/24	Normal	Diffuse increase	I
7	Syncope	L ICA occlusion		37/32	Normal	Diffuse increase	I
8	R hemiparesis	L ICA occlusion, 80–90%; R ICA stenosis	66	30/28	Focal R MCA distr.; low flow	No change	III
9	L carotid bruit	Doppler 80% L ICA stenosis	50	39/37	Normal	Diffuse increase	I
10	Transient R hemiparesis & expressive aphasia	Doppler severe L ICA stenosis	57	42/40	Focal L MCA decreased flow	Unchanged	III
11	Transient R hemiparesis	40–50% L ICA stenosis	66	34/24	Normal	Diffuse increase	I
12	L occipital infarct; light-headedness	>80% L ICA stenosis; >80% L subclavian stenosis; R subclavian occlusion	54	42/34	Normal	Diffuse increase	I
13	R CVA	R ICA occlusion	63	30/26	Low flow R ACA; R MCA distr.	Diffuse increase	II
14	Transient R hemiparesis & aphasia	>70% L ICA stenosis		32/28	Periinfarct; normal	Diffuse increase	I
15	Syncope	R ICA occlusion		41/38	Normal	Diffuse increase	I
16	Episodic dizziness	>70% L & R VA stenosis	67	36/30	Normal	Diffuse increase	I
17	Asymptomatic	L ICA occlusion	66	30/27	Global low flow	Diffuse increase	II
18	Asymptomatic	L ICA & R ICA occlusion	60	36/30	Global low flow	Diffuse increase	II
19	R hemiparesis; L caudate infarction	L MCA occlusion			Low normal flow (periinfarct)	Diffuse increase except in infarct	I
20	Vertigo	L ICA, R ICA, R VA occlusion; L EC-IC bypass	70		Global low	Diffuse increase	II
21	R hemisphere TIAs; R amaurosis fugax	R ICA occlusion R ICA stenosis			Focal low R ICA distr. flow	Focal low R ICA distr.	III
22	R amaurosis fugax	L ICA occl; R VA occl; R ICA pseudoocclusion	64	35/28	Diffuse low flow	Diffuse increase	
23	R amaurosis fugax	R ICA 80% stenosis; R subclavian occlusion	54	35/26	Normal	Diffuse increase	I
24	R hemiparesis	>80% L ICA stenosis	67	32/28	Low normal	Diffuse increase	I

Table 1—Continued

Case No.	Clinical History	Significant Vascular Anatomy	Age	Pre-pCO ₂ /Post-pCO ₂	Baseline Cerebral Blood Flow	Xe Diamox	Type*
25	Vertigo	Doppler; R ICA stenosis	62	32/32	Diffuse low flow	Focal low	III
26	L carotid bruit	90% L ICA stenosis	69		Normal	Diffuse increase	I
27	R amaurosis fugax	L ICA & R ICA occlusion; 80% L VA stenosis; 60% R VA stenosis	63		Diffuse low flow	Diffuse increase	II
28	L bruit; old MCA infarct	99% L ICA stenosis; 50% R ICA stenosis	42		Focal low flow (periinfarct)	Diffuse increase	II
29	L upper extremity weakness	99% R ICA stenosis; L ICA occlusion; 50% L & R VA stenosis	55		Normal	Focal decrease (R ICA distr.)	III

* Type: I = normal baseline with post-Diamox flow augmentation; II = low-flow baseline with post-Diamox augmentation; III = low or normal baseline with no response or decreased flow post-Diamox. Low = 20–35, normal = 35–60, high = >60 (as defined in text).

Note.—ACA = anterior cerebral artery; MCA = middle cerebral artery; PCA = posterior cerebral artery; subclav = subclavian artery; VA = vertebral artery; ICA = internal carotid artery; R = right; L = left; EC-IC = extracranial to intracranial; TIA = transient ischemic attack; CVA = cerebrovascular accident.

have maximum vasodilation, while augmentation would be expected in regions with reduced CBF secondary to decreased metabolic demand.

On the basis of this theory, some investigators have measured CBF before and after a flow challenge to identify patients with "misery perfusion." Various methods have been used to create a flow challenge: (1) elevating or lowering blood pressure, (2) having patients inhale a 3–5% carbon dioxide mixture, or, more recently, (3) administering an IV acetazolamide (Diamox) bolus [9–12].

Acetazolamide is easy to administer, safe, and provokes a predictably potent vasodilatory challenge [13–15]. The specific action of the drug that causes vasodilation is unclear, but it is believed that vasodilation is mediated by the drug's inhibition of carbonic anhydrase [12, 13]. The vasodilatory effect appears to be localized to the brain [13, 15, 16], and the activity of the drug remains potent despite baseline increased tissue levels of pCO₂ [13, 14]. The degree of CBF augmentation found in the normal individual has ranged from 70–90% [12, 13]. With advancing age, activated flows may not increase as dramatically, but flow symmetry will remain preserved [12].

Materials and Methods

CBF was determined by the Xe/CT CBF method. The Xe/CT method is a relatively new CBF technology that provides tomographic, quantitative CBF information with direct anatomic correlation.* This methodology has been addressed in detail previously [1, 17–19].

Xe/CT CBF with an acetazolamide challenge can be performed on an outpatient as well as inpatient basis. The average time to complete a double CBF study—before and 20 min after the administration of

TABLE 2: Cerebral Blood Flow* Analysis in Four Representative Cases: The Effect of Diamox by Vascular Territory

		R ACA	L ACA	R MCA	L MCA	R PCA	L PCA
Type I	Baseline	46	44	49	52	49	47
Case 26	Diamox	63	63	67	67	63	66
	% Change	35%	43%	37%	29%	30%	39%
Type II	Baseline	26	26	31	28	32	32
Case 27	Diamox	37	46	41	41	53	51
	% Change	43%	73%	31%	50%	65%	60%
Type II	Baseline	33	25	35	23	37	37
Case 28	Diamox	44	32	44	31	47	47
	% Change	35%	28%	23%	35%	29%	27%
Type III	Baseline	34	36	34	41	47	44
Case 29	Diamox	34	32	32	48	47	54
	% Change	1%	–11%	–5%	18%	0%	23%

* Cerebral blood flow measured as ml/100 g/min.

Note.—R = right; L = left; ACA = anterior cerebral artery; MCA = middle cerebral artery; PCA = posterior cerebral artery.

acetazolamide—is 60 to 90 min. Patient cooperation is required for this study, which also demands direct involvement of a health care professional. Immediately after the initial CBF study, 1 g of IV acetazolamide is administered. The second study is begun 20 min after drug delivery. Typically, acetazolamide results in a reduction of measured end tidal CO₂ (see Table 1) without alteration of vital signs or other associated symptoms.

We studied 29 patients with significant vascular disease diagnosed by either noninvasive studies or angiography. Twenty-three individuals had at least one significantly stenosed or occluded carotid artery, and 12 had occlusion in two or more major vessels (Table 1). Three patients were asymptomatic and underwent these studies because they were found to have a carotid bruit. Twenty-six patients had experienced transient ischemic attacks (TIAs) or fixed neurologic compromise. The latter patients were studied at least 3 weeks after a stroke. This allowed time for the recoupling of CBF and metabolism to occur.

* General Electric Medical Systems, Milwaukee, WI.

We compared pre- and postacetazolamide CBF studies by using standard contrast-mode software and region-of-interest density software for blood flow analysis (see Fig. 1). In the contrast mode, all values above the designated flow level are displayed as white, and all values below as black (see Figs. 2E and 2F). Regions of interest for regional cerebral blood flow (rCBF) were consistent with vascular territories reported by Damasio [20]. Pre- and postacetazolamide blood flow maps were compared for evidence of flow change in corresponding vascular territories. We generally considered rCBF to be within normal limits when flows ranged between 35 and 60 ml/100 g/min. Acceptable limits of normal were somewhat dependent on patient age, however, as flows of 35 ml/100 g/min were considered low in a 20-year-old but acceptable in an 80-year-old. An rCBF between 20 and 35 was generally considered low; an rCBF greater than 60 was generally considered elevated.

Results

The results are summarized in Table 1. This table provides clinical information and significant vascular anatomy for each of the 29 patients in the study. All patients had at least one major vessel with greater than 50% stenosis. Twelve (41%) had multivessel disease. pCO_2 values are provided to demonstrate that Diamox was physiologically active, blocking carbonic anhydrase and thereby decreasing pCO_2 in all cases.

Three basic types of responses to Diamox are defined: type I, normal CBF before Diamox with flow augmentation after Diamox; type II, diffuse or focal low CBF before Diamox with augmentation after Diamox; type III, low or normal CBF before Diamox with no response or decreased CBF after Diamox. Thirteen patients (45%) had a type I response, nine patients (31%) had a type II response, and seven patients (24%) had a type III response. The following four cases are representative of each response type and are described in greater detail in Table 2.

Type I (case 26, Table 1): A 69-year-old man was evaluated after being diagnosed, during a routine physical examination, as having an asymptomatic left carotid bruit. Noninvasive studies showed severe stenosis of his left internal carotid artery (ICA). Angiography confirmed 80–90% stenosis at the origin of the proximal left ICA; the remainder of the intracranial vasculature and the circle of Willis were normal. A CT scan (Fig. 1A) was unremarkable, and the baseline Xe/CT CBF study (Fig. 1B) was normal. Flow was symmetrical in all territories, with most values ranging between 45 and 55 ml/100 g/min. Twenty minutes after the patient received 1 g of IV acetazolamide, we performed a second CBF study (Fig. 1C), which showed an average flow increase of 36% in all vascular territories (Table 2).

Type II (case 27, Table 1): A 63-year-old woman presented with a sudden onset of blindness in the right eye that resolved partially over the next 6 weeks. Angiography demonstrated 90% stenosis at the origin of the left common carotid artery and occlusion of the left internal carotid artery (ICA). The right ICA also was occluded, and the right external carotid artery was moderately stenotic at its origin. The origin of the left vertebral artery had an 80% stenosis, and the origin of the right vertebral artery had 50–60% stenosis. Collateral supply to the right ICA siphon was supplied by ethmoidal vessels. In addition to flow from the right ICA, the right anterior cerebral artery (ACA) and middle cerebral artery (MCA) also received collateral flow through the right posterior communicating artery and leptomeningeal collaterals from the right posterior cerebral distributions. The baseline Xe/CT CBF study demonstrated lower flow values bilaterally than would be expected in a 63-year-old person (a mean of 29, Table 2). The introduction of acetazolamide, however, caused a symmetrical flow augmentation of 55% (up to 44.9 ml/100 g/min).

Type II (case 28, Table 1): A 42-year-old man presented with an asymptomatic bruit found after a significant left hemi-

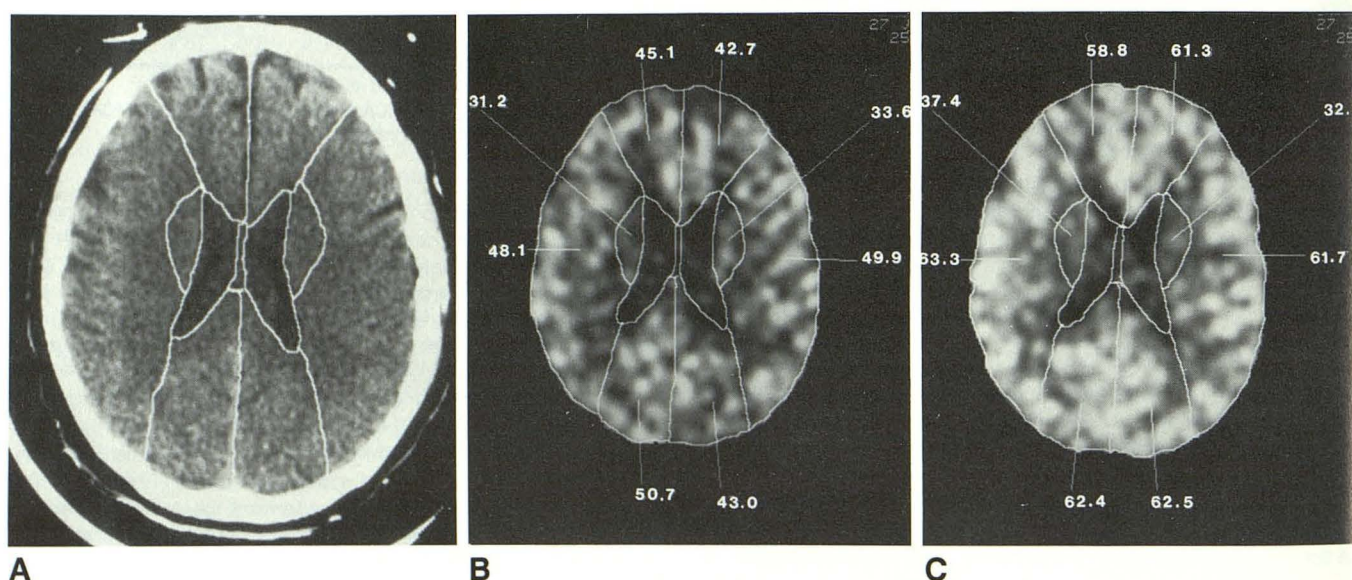


Fig. 1.—A–C, Case 26. Xe/CT scans demonstrate a representative type I normal scan series.

A, The middle of the usual three levels selected for evaluation.

B, Baseline Xe/CT image with superimposed vascular territory map and region of interest blood flows (ml/100 g/min).

C, Repeat Xe/CT CBF evaluation after Diamox (1 g IV). Flow augmentation has occurred in all vascular territories.

sphere, closed head injury. His examination revealed a mild residual expressive aphasia. CT images disclosed an area of encephalomalacia in the left middle cerebral artery distribution, consistent with a remote infarction (Fig. 2A). Angiography demonstrated 99% stenosis at the origin of the left ICA and 50% stenosis at the origin of the right ICA. Collateral flow to the left hemisphere occurred by retrograde ophthalmic artery flow to the carotid siphon, and by posterior communicating artery and leptomeningeal collaterals from the posterior circulation. The baseline Xe/CT CBF study showed an area of hypoperfusion corresponding to the site of previous infarction, but also showed compromised flow values in the remainder

of the left middle cerebral artery (Figs. 2B, 2E, and Table 2). After receiving 1 g of acetazolamide, there was an increase of CBF in all territories, including the region immediately posterior to the infarction within the distal distribution of the middle cerebral artery (Figs. 2C, 2F, and Table 2).

Type III (case 29, Table 1): A 55-year-old man presented with left upper extremity weakness and left facial paresis of recent onset. An angiogram defined a 95% stenosis at the proximal right ICA, and complete occlusion of the left ICA. The left and right anterior and middle cerebral arteries were supplied by the stenotic right ICA. The left middle cerebral artery was supplied by collateral vessels from the left external

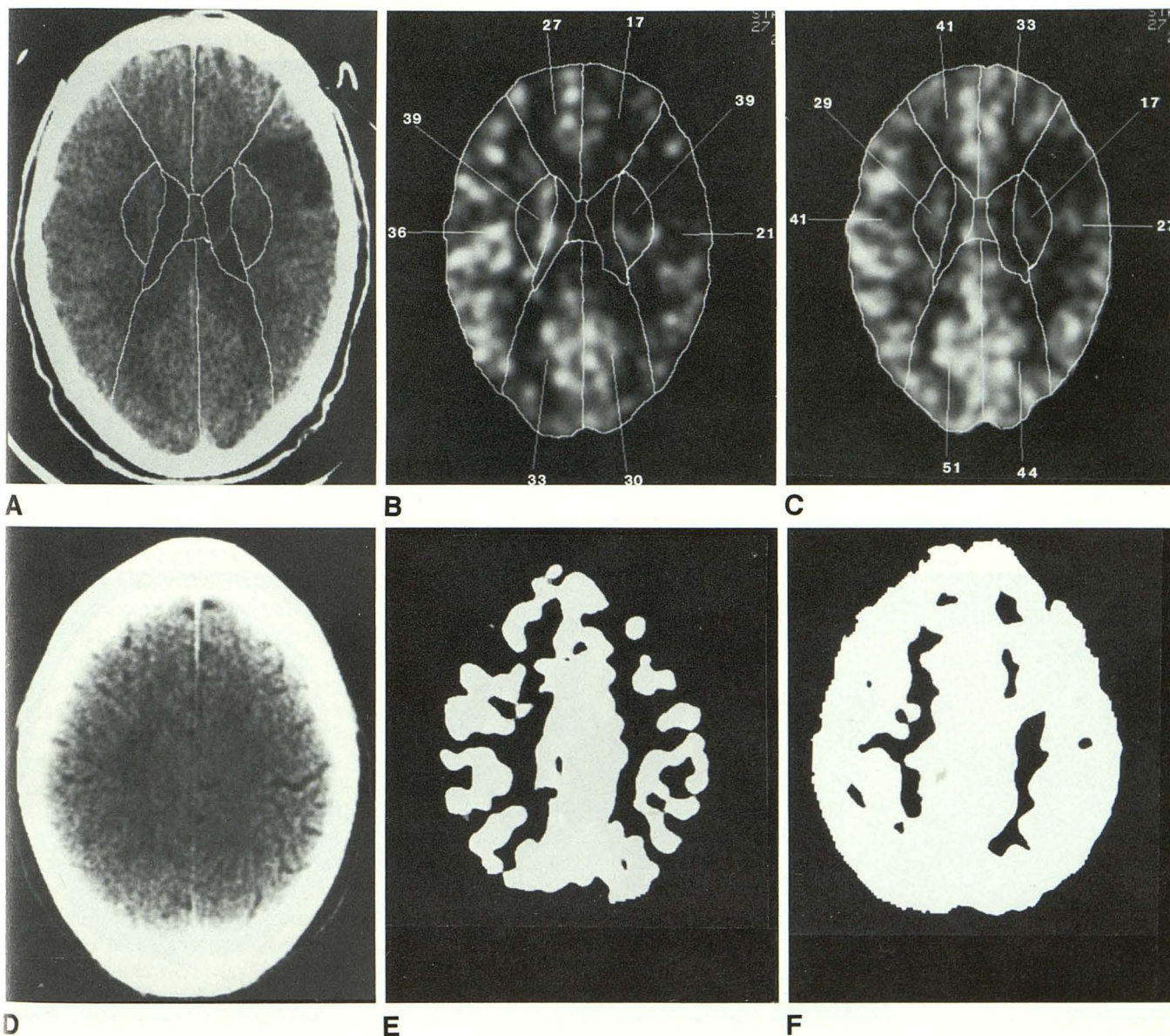


Fig. 2.—A–F, Case 28. Xe/CT scans demonstrate a representative type II scan series.

A shows an area of encephalomalacia in left frontoparietal region from a previous infarction. The level above, D, appears normal.

In B and E, Xe/CT shows that the area of decreased CBF is greater than that expected from plain CT. Flows are decreased in the left frontal and mid-parietal regions anterior and posterior to the old infarction, as well as in the frontoparietal region above the site of the infarct.

In C and F, Post-Diamox flow augmentation is seen in periinfarct zone at level of, and cephalad to, the known area of encephalomalacia. E and F were filmed at a level of 20 (white = flow greater than 20 ml/100 g/min) to accentuate flow differences before and after Diamox.

carotid and left posterior cerebral arteries. The origins of both vertebral arteries were moderately stenotic. A CT scan was unremarkable (Fig. 3A). The baseline Xe/CT CBF study disclosed normal baseline flow values within all territories, but with mild asymmetry ($R < L$) (Figs. 3B, 3C, and Table 2). After the addition of acetazolamide, flow remained unchanged or decreased in all right anterior circulation territories and in the left anterior cerebral artery territory (Figs. 3D, 3E, and Table 2).

Discussion

The diagnostic utility and specificity provided by the use of acetazolamide as a vasodilatory challenge were suggested

by Vorstrup et al. [21], who used Xe-133 with SPECT imaging to evaluate patients before and after extracranial-intracranial bypass operations [21, 22]. These researchers noted postoperative augmentation of resting CBF in only one of the 13 patients with preoperative regional hypoperfusion; this patient was also the only patient in the study whose CBF was not increased after preoperative acetazolamide flow challenge. These findings support the contention that acetazolamide flow challenge can identify those patients who already have maximal vasodilation and minimal flow reserves.

On the basis of our experience, we defined three types of responses to an acetazolamide challenge: I, an increase in normal baseline flow values; II, an increase in focal or diffuse low flow values; and III, no change or a decrease in low or normal flow values. Type III is the only group that would

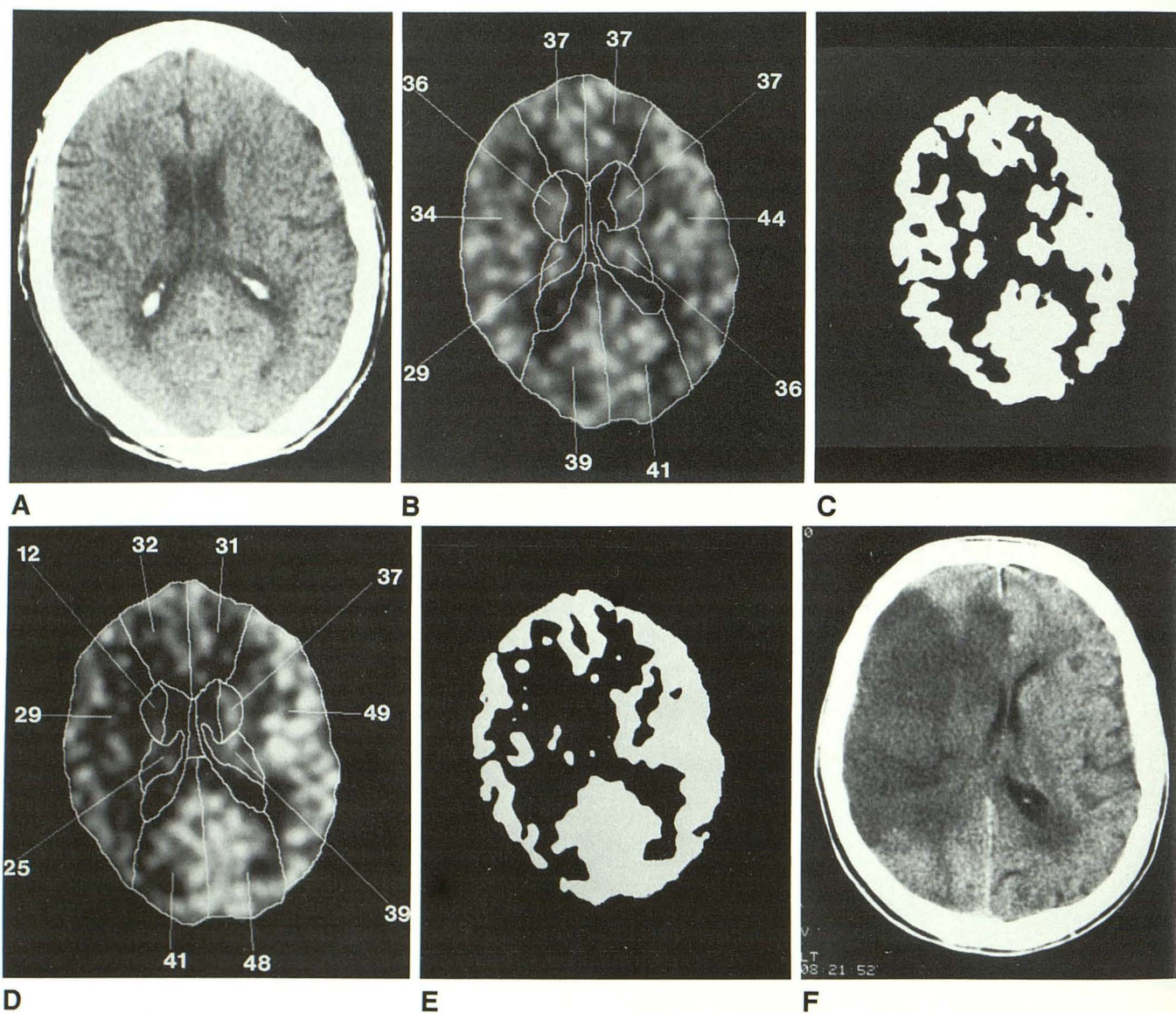


Fig. 3.—A–F, Case 29. Xe/CT scans demonstrate a representative type III scan series.

A shows a baseline CT with low-normal right hemispheric CBF (B) on baseline Xe/CT scans. C displays the CBF data shown in B at a flow threshold of 20 ml/100 g/min. The post-Diamox (D and E) scans demonstrate decreased CBF from baseline in right and left anterior cerebral and right middle cerebral artery territories. F, obtained 48 hr after xenon evaluation, shows massive area of infarction corresponding to region of predicted CBF compromise.

include the single patient reported by Vorstrup et al. [21] and the group with "misery perfusion" reported by Baron et al. [3]. Each of these categories is represented by one or two of the cases described earlier. Case 26 is an example of type I: normal baseline CBF that increased significantly after the administration of acetazolamide. This patient is typical of many patients (13 of 29) we studied who had normal flow despite angiographic evidence of significant stenosis or occlusion.

Cases 27 and 28 exemplify type II: diffuse or focal low flow in baseline studies but with maintained reserves of CBF as demonstrated by the ability to augment flow with acetazolamide. Nine of our 29 patients fell into this group. Although angiography suggested that the supply of blood was severely compromised in case 27, the patient's retention of blood flow reserves suggested that the low flow areas were appropriate to the decreased demand. The patient's absence of further symptoms while on anticoagulation therapy in the 6 months following this assessment supports our assumption of an embolic origin of her symptoms.

Case 28 illustrates reduced CBF, and presumably reduced metabolism, due to deafferentation. Figure 2B shows a region with relatively low flow posterior to the CT-defined infarction, despite the relatively normal appearance of this region on the CT images. After acetazolamide administration, the flow in this area increased, providing evidence for adequate availability of blood flow, but reduced demand. The presence of a larger area of flow and metabolic disturbance than suggested by the CT-defined injury has been widely reported [23].

Case 29 represents type III, low or normal baseline flow values that decreased in a potentially compromised vascular distribution after the patient received acetazolamide, despite an elevation of CBF in other areas. This finding suggested that there is little potential for collateral flow to the portion of the brain that angiography has shown to be supplied preferentially by the right ICA. If the right ICA were further compromised, the patient would be at a significant risk of sustaining a massive infarct [24]. The patient was scheduled for emergency right carotid endarterectomy but before this could be performed, 36 hr after the study, the predictive value of the acetazolamide challenge was substantiated by the onset of a massive stroke in the territory of the right middle cerebral artery (Fig. 3F). Seven (24%) of our 29 patients with significant occlusive vascular disease were in this category.

Despite angiographic and/or noninvasive evidence of significant occlusive vascular disease, 76% of the patients studied by Xe/CT CBF had, at rest, flow values that increased significantly with acetazolamide. This finding is consistent with earlier reports that emphasize the imprecision of existing anatomic methods for predicting hemodynamic compromise [5], and is supported by Sullivan et al. [13], who found that 40% of patients with significant vascular disease on angiography had normal CBF when given an acetazolamide flow challenge and studied by Xe-133 scintillation counting. The studies of Vorstrup and others along with our own limited experience indicate that patients who have type III responses are those most likely to benefit from medical or surgical efforts to augment CBF delivery.

Although the international study of extracranial-intracranial

bypass operations suggested that flow augmentation procedures were not of significant clinical benefit [25, 26], a recent review of that study suggests that a subgroup of critically flow-dependent patients may have been excluded [27]. Our experience indicates that the Xe/CT CBF technique combined with a challenge of flow reserve is a useful clinical means to identify a hemodynamically compromised subgroup of individuals who may have transient symptoms due to a marginal basal level of perfusion that transiently drops to a level inadequate to maintain function. Once such persons are identified, future studies are needed to define their prognosis and determine whether they may benefit from either medical or surgical approaches.

In summary, we believe that Xe/CT CBF measurements used with an acetazolamide challenge provide an objective, clinically accessible method of assessing cerebral blood flow and blood flow reserve.

REFERENCES

1. Yonas H, Gur D, Good B, et al. Stable xenon CT blood flow mapping for evaluation of patients with extracranial-intracranial bypass surgery. *J Neurosurg* 1985;62:324-333
2. Grubb RL Jr, Ratcheson R, Raichich M, et al. Regional cerebral blood flow and cerebral oxygen utilization in superficial temporal middle cerebral artery anastomosis patients. *Acta Neurol Scand* 1979;60:502-503
3. Baron JC, Bousser MG, Rex A, et al. Reversal of focal "misery perfusion syndrome" by extra- intracranial arterial bypass in hemodynamic cerebral ischemia: a case study with 0-15 positron emission tomography. *Stroke* 1981;12:454-459
4. Kistler PJ, Popper AH, Heres RC. Therapy of ischemic cerebral vascular disease due to atherothrombosis. *N Engl J Med* 1984;311:22-34, 1984; 311:100-105
5. Latchaw RE, Ausman JI, Lee M. Superficial temporal-middle cerebral artery bypass: a detailed analysis of multiple pre- and post-operative angiograms in 40 consecutive patients. *J Neurosurg* 1979;51:455-465
6. Lebrun-Grandie P, Baron JC, Soussaline F, et al. Coupling between regional blood flow and oxygen utilization in the normal human brain: a study with positron tomography and oxygen-15. *Arch Neurol* 1986;4: 230-236
7. Lenzi GL, Frackowiak RS, Jones T. Cerebral oxygen metabolism and blood flow in human cerebral ischemic infarction. *J Cereb Blood Flow Metab* 1982;2:321-335
8. Jones TH, Morawetz RB, Crowell RM, et al. Thresholds of focal cerebral ischemia in awake monkeys. *J Neurosurg* 1981;54:773-782
9. Yonas H, Gur D, Claassen D, Wolfson SK Jr, Moossy J. Stable xenon-enhanced computed tomography in the study of clinical and pathologic correlates of focal ischemia in baboons. *Stroke* 1988;19:228-238
10. Norrving B, Bengt N, Risberg J. rCBF in patients with carotid occlusion; resting and hypercapnic flow related to collateral pattern. *Stroke* 1982;13:155-162
11. Grubb RL, Reichle ME, Erchling JO, et al. The effects of changes in PaCO₂ on cerebral blood volume, blood flow and vascular mean transit time. *Stroke* 1974;5:630-639
12. Auge A, Thoresen M, Walle L. Changes in cerebral blood flow during hyperventilation and CO₂-breathing measured transcranially in humans by pulsed bidirectional ultrasound Doppler blood velocity meter. *Acta Physiol Scand* 1980;110:167-173
13. Sullivan HG, Kingsbury TB, Morgan MS, et al. The rCBF response to Diamox in normal subjects and cerebrovascular disease patients. *J Neurosurg* 1987;67:525-534
14. Hauge A, Nicolaysen G, Thoresen M. Acute effects of acetazolamide on cerebral blood flow in man. *Acta Physiol Scand* 1983;117:233-239
15. Cotev S, Lee J, Severinghaus JW. The effects of acetazolamide on cerebral blood flow and cerebral tissue PCO₂. *Anesthesiology* 1968;29:471-477
16. Macri JJ, Politoff A, Rubin R, Dixon R, Rall D. Preferential vasoconstrictor properties of acetazolamide on the arteries of the choroid plexus. *Int J*

- Neuropharmacol* 1966;5:109-115
17. Gur D, Wolfson SK, Yonas H, et al. Progress in cerebrovascular disease: local cerebral blood flow by xenon-enhanced CT. *Stroke* 1982;13:750-758
 18. Yonas H, Good WF, Gur D, et al. Mapping cerebral blood flow by xenon-enhanced computed tomography: clinical experience. *Radiology* 1984;152:435-442
 19. Yonas H, Wolfson SK Jr, Gur D, et al. Clinical experience with the use of xenon-enhanced CT blood flow mapping in cerebral vascular disease. *Stroke* 1984;15:443-450
 20. Damasio H. A computed tomographic guide to the identification of cerebral vascular territories. *Arch Neurol* 1983;40:138-142
 21. Vorstrup S, Paulson OB, Lassen NA. How to identify hemodynamic cases. In: Spetzler, Carter, Selman, Martin, eds. *Cerebral revascularization for stroke*. New York: Theme-Stratton, 1985
 22. Batjer HH, Devous MD, Purdy PD, et al. Improvement in regional cerebral blood flow and cerebral vasoreactivity after extracranial-intracranial arterial bypass. *Neurosurgery* 1988;22:913-919
 23. Kuhl DE, Phelps ME, Kowell AP, Metter EJ, Selin C, Winter J. Effects of stroke on local cerebral metabolism and perfusion: mapping by emission computed tomography of ^{18}F FDG and ^{13}N H₃. *Ann Neurol* 1980;8:47-60
 24. Yonas H, Steed D, Latchaw R, Gur D, Peitzman A, Webster M. Relief of nonhemispheric symptoms in low flow states by anterior circulation revascularization: a physiologic approach. *J Vasc Surg* 1987;5:289-297
 25. EC/IC Bypass Study Group. Failure of extracranial-intracranial arterial bypass to reduce the risk of ischemic stroke. *N Engl J Med* 1985;313:1191-1200
 26. Plum F. Extracranial-intracranial arterial bypass and cerebral vascular disease. *N Engl J Med* 1985;313:1221-1223
 27. Sundt TM Jr. Was the international randomized trial of EC/IC arterial bypass representative of the population at risk? *N Engl J Med* 1987;316:814-816