



## Get Clarity On Generics

Cost-Effective CT & MRI Contrast Agents

**FRESENIUS  
KABI**

[WATCH VIDEO](#)

# AJNR

### **A protocol for the isolation of carotid and vertebral arteries in MR angiography.**

J P Cousins, C L Dumoulin, S P Souza and W A Wagle

*AJNR Am J Neuroradiol* 1989, 10 (5) 921-922

<http://www.ajnr.org/content/10/5/921.citation>

This information is current as  
of August 7, 2025.

## A Protocol for the Isolation of Carotid and Vertebral Arteries in MR Angiography

Joseph P. Cousins,<sup>1</sup> Charles L. Dumoulin,<sup>2</sup> Steven P. Souza,<sup>2</sup> and William A. Wagle<sup>1</sup>

MR angiography [1–9] is rapidly becoming a technique to evaluate blood flow in the carotid and vertebral arteries. We have been using a time-of-flight pulse sequence [9] to acquire axial images of carotid and vertebral arteries with flow-encoded information. These axial images can be reformatted through a computer algorithm to give multiple angle presentations of the collected data in sagittal or coronal planes.

We found that many of the reconstructed images were difficult to interpret because of overlap of right and left vertebral and carotid arteries (Fig. 1). Presented here is a protocol for optimizing the information obtained in the time-of-flight images.

All of the angiograms were obtained on a clinical 1.5-T system.\* Studies of the carotid artery bifurcations were performed with the standard linear head coil, which was used for both excitation and detection. The region of interest (the carotid bifurcation) was located with multiple-view angle, phase-contrast MR angiograms [4]. A series of 128 axial time-of-flight images was then obtained with superior saturation to suppress venous flow. Standard acquisition parameters were: 16-cm field of view, 12-cm slab, one excitation, 128 × 256 matrix, and 20° flip angle.

The problem of arterial overlap was solved in a straightforward manner. The 128 axial images were reduced to 64 to 80 consecutive images centered in the excitation slab. The right arteries were isolated by using a circular mask that included only the right carotid and vertebral in the reformatting of the axial images. The positions of the axes of rotation and the circular masks used in the processing are shown in Figure 2. A series of 31 images was produced with views of the vessels at 6° increments through 180°. The analogous procedure was performed to isolate and image the left arteries. One side benefit of this procedure is that any two consecutive reformatted images of the series can be presented as stereoscopic pairs (Fig. 3).

The two sets of images of the right and left arteries are automatically centered by the reformatting process. There-

fore, to present the isolated arteries on the same image for direct comparison, the two sets of 31 images had to be offset from center using a translation function of another program. In order to allow adequate separation of the images of the right and left arteries, the images were translated left and right respectively (the circular radius +5 pixels). The offset images were then added together using a computer program to produce a final set of 31 images. Two of these combined images are shown in Figure 4. The right and left arteries are clearly presented with no overlap from vessels on the opposite side. The top images in Figure 4 present the carotids and vertebrals as if one was looking at both the right and left arteries simultaneously from an exterior position (a lateral view); the bottom images in Figure 4 present the vessels rotated 180°, a simultaneous view of the arteries from the midline of the patient.

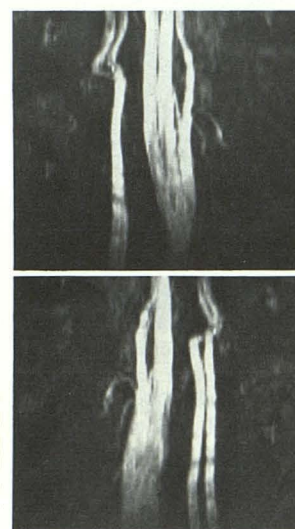


Fig. 1.—Lateral view of right (top) and left (bottom) carotid and vertebral arteries obtained from reformatting time-of-flight axial images acquired with superior saturation (venous suppression). Images are difficult to interpret owing to overlap of vessels.

\* General Electric, Milwaukee, WI.

Received February 15, 1989; revision requested April 12, 1989; revision received May 2, 1989; accepted May 4, 1989.

<sup>1</sup> Department of Radiology, MRI/Neuroradiology Section, The Albany Medical College, New Scotland Ave., Albany, NY 12208. Address reprint requests to J. P. Cousins.

<sup>2</sup> The General Electric Corporate Research and Development Center, Schenectady, NY 12301.



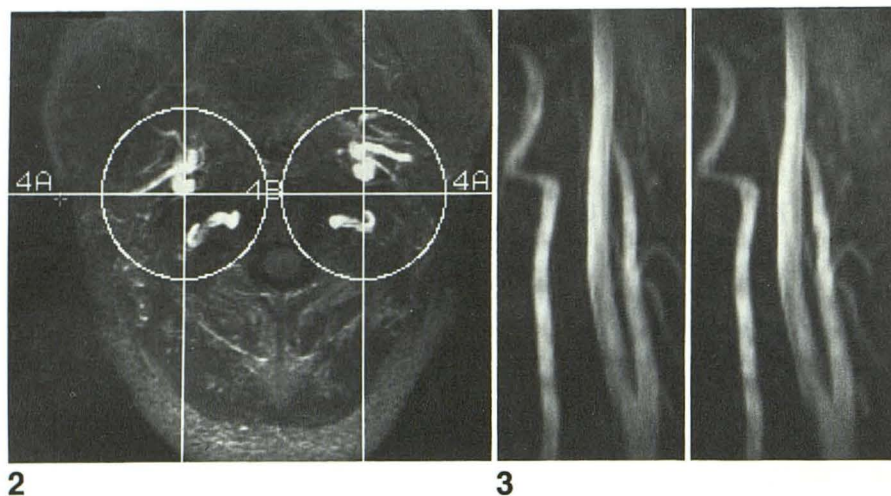


Fig. 2.—Stacked view of the 80 time-of-flight axial images used for image reconstructions in Figs. 1, 3, and 4. Axes of rotation for vessels (+) and circular masks are highlighted for both right and left arteries. Position of viewer to vessels in Fig. 4 (top) and 4 (bottom) is indicated by 4A and 4B, respectively.

Fig. 3.—Stereoscopic images (right and left) of isolated right carotid and vertebral arteries obtained from time-of-flight axial images with venous suppression.

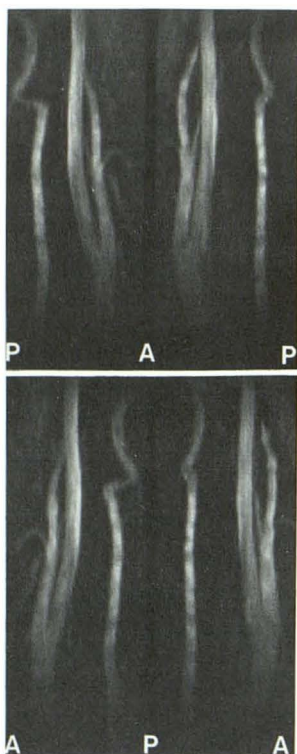


Fig. 4.—Simultaneous lateral views of isolated right and left carotid and vertebral arteries, from an exterior position (top) and an interior position, from the midline (bottom). This presentation allows direct comparison of vessels with no interference of opposite vasculature.

The advantages to using this procedure for the presentation of carotid and vertebral MR-angiography data are that the overlap of opposing vessels is eliminated, and that the right and left vessels are presented simultaneously to allow direct

comparisons. If one views the images of the isolated arteries in the spatial mode on the GE console or from a VCR tape, one can also obtain a three-dimensional presentation of the arteries because of the rapid presentation of stereoscopic images with time.

Although this procedure requires two different image reconstructions, two image translations, and one addition, instead of just one reformatting (Fig. 1), we think the data presented have greater clinical utility because interference from opposite vessels is eliminated, and both right and left arteries are presented simultaneously at any view angle, including a true lateral view.

#### REFERENCES

1. Nishimura DG, Macovski A, Pauly JM. Magnetic resonance angiography. *IEEE Trans Med Imaging* 1986;MI-5(#3):140-151
2. Nishimura DG, Macovski A, Pauly JM, Conolly SM. MR angiography by selective inversion recovery. *Magn Reson Med* 1987;4:193-202
3. Dumoulin CL, Hart HR. Magnetic resonance angiography. *Radiology* 1986;161:717-720
4. Dumoulin CL, Souza SP, Feng H. Multi-echo magnetic resonance angiography. *Magn Reson Med* 1987;5:47-57
5. Dumoulin CL, Souza SP, Hart HR. Rapid scan magnetic resonance angiography. *Magn Reson Med* 1987;5:238-245
6. Souza SP, Dumoulin CL. Dynamic magnetic resonance angiography. *Dynamic Cardiovasc Imaging* 1987;1:126-127
7. Dumoulin CL, Souza SP, Walker MF, Yoshitome E. Time-resolved magnetic resonance angiography. *Magn Reson Med* 1988;6:275-286
8. Walker MF, Souza SP, Dumoulin CL. Quantitative phase contrast magnetic resonance angiography. *J Comput Tomogr* 1988;12:304-313
9. Dumoulin CL, Cline HE, Souza SP, Wagle WA, Walker MF. Three-dimensional time-of-flight magnetic resonance angiography using spin saturation. *Magn Reson Med* 1989;11:35-46