



Providing Choice & Value

Generic CT and MRI Contrast Agents



**FRESENIUS
KABI**

CONTACT REP

AJNR

**Intravascular Therapeutic Embolization for
Acute Traumatic Bleeding from the Ear**

Fong Y. Tsai, Dipak C. Shah, Kenneth Alfieri and Akhtar Ashraf

AJNR Am J Neuroradiol 1989, 10 (5 suppl) S40-S41

http://www.ajnr.org/content/10/5_suppl/S40.citation

This information is current as
of July 28, 2025.

Intravascular Therapeutic Embolization for Acute Traumatic Bleeding from the Ear

Fong Y. Tsai,¹ Dipak C. Shah, Kenneth Alfieri, and Akhtar Ashraf

Severe trauma to the head may result in vascular injuries. The clinical presentation may be varied and cause either acute or chronic symptoms. The acute traumatic bleeding from the ear resulting from perforating or blunting trauma to the basal skull has been reported only rarely [1–3]. We are reporting our experiences of intravascular therapeutic technique that we used in treating acute traumatic bleeding from the ear.

Case Reports

Case 1

A 25-year-old male victim of a car accident suffered severe basal skull and neck trauma. Right ear bleeding was stopped by packing. However, after surgical stabilization of the cervical spine injury with a halo, sudden massive active bleeding was noted from the swollen right ear. Episodes of hypotensive blood pressure occurred. Emergency angiography disclosed a transection of right internal maxillary artery with a high pseudoaneurysm and fistula into the jugular vein (Figs. 1A and 1B). The patient's blood pressure was unstable; therefore, emergent embolization was performed with Gianturco steel coil. The first steel coil did not stop the bleeding. After the placement of the second steel coil, active bleeding was stopped, but oozing continued. The oozing stopped completely about 1 hour after embolization (Fig. 1C). He has been followed for 1½ years after the accident and has had no recurrent symptoms.

Case 2

A 30-year-old man suffered gunshot wounds to his head, neck, and chest. Despite transfusion, systolic blood pressure fluctuated from 80 to 120 mm. He became hypotensive, and massive active bleeding from the right ear occurred. Emergent angiography disclosed a huge extravasation from the right ear and mastoid with a huge fistula between right internal carotid artery and jugular vein (Figs. 2A and 2B). No flow was noted from right internal carotid artery to the head. Intravascular embolization was performed after angiography, and the bleeding was stopped with two steel coils (Figs. 2C and 2D). The patient was stabilized, and his blood pressure returned to 130/80. He has not had recurrent symptoms for 1 year after the accident.

Discussion

Vascular injury may result in occlusion, transection, or fistula formation. Lacerations and transections frequently present with hemorrhage, expanding hematoma, and/or a false

aneurysm; they may require acute emergency treatment. This type of injury usually requires repair of the damaged artery; however, if the injury is surgically inaccessible or if the patient's condition is deteriorating so fast that surgical management is not feasible, emergency therapeutic embolization may be performed [1–3]. In our two cases, two patients had massive bleeding and unstable blood pressure despite transfusion. Although surgical ligation of carotid artery also may stop bleeding, our intravascular embolization was performed quickly and eliminated the risk of general anesthesia.

Detachable balloon embolization has been the method for endovascular treatment of traumatic arteriovenous fistula. With high flow and a wide open fistula, the detached balloons may be dislodged into the jugular vein and then may migrate to the heart and lungs [1–7]. In case 2, a huge fistula of internal carotid artery directly shunted into jugular vein. We chose a steel coil instead of detachable balloon to avoid dislodgment of the detached balloon into the lung (which had occurred in two other cases, one carotid jugular fistula [3] and one vertebrojugular fistula). The steel-coil embolization also requires less skill to perform than does the detachable-balloon embolization. The steel coil may be placed into the artery by using the same angiographic catheter [8, 9]. In case 2, we had a partial embolization with two steel coils, but no recurrence was noted after 1 year, probably because the strands of steel coil may generate more thrombi after the procedure, resulting in further embolization.

Partial proximal embolization carries the potential risk of fistula recurrence; however, the fistula may be reembolized with either balloon, particulate, or liquid emboli agents. The risk of dislodging emboli in this situation will be lower than in the initial emergent situation. If the arterial route is not accessible, a venous approach may be considered.

Although we had only a short time to follow-up (1–1½ years), no symptoms recurred in either case. Steel coils may be considered as an alternative choice in treating this life-threatening situation of massive bleeding and unstable clinical condition.

REFERENCES

1. Hieshima GB, Mehringer CM, Grinnell VS, Hasso AN, Siegel NM, Pribbaum HF. Emergency occlusive techniques. *Surg Neurol* 1978;9:239–302

Received June 6, 1988; revision requested August 5, 1988; revision received October 18, 1988; accepted October 18, 1988.

¹ All authors: University of Missouri–Kansas City, School of Medicine, Radiology Department, Truman Medical Center, 2301 Holmes, Kansas City, MO 64108. Address reprint requests to F. Y. Tsai.

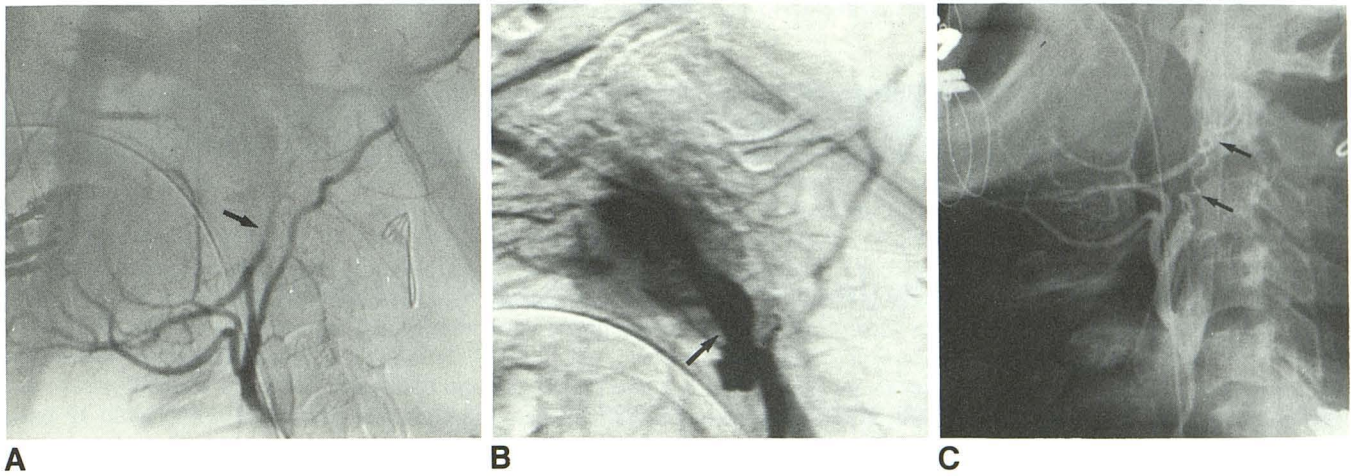


Fig. 1.—Case 1.

A, Right external carotid angiography shows laceration of internal maxillary artery (arrow). Metallic wire at C2–C3 was for cervical spine fracture. Extravasation of contrast material was not well seen.

B, Digital subtraction angiography of external carotid artery clearly shows a huge pseudoaneurysm (arrow) and extravasation originating from proximal internal maxillary artery.

C, Embolization after insertion of steel coils (arrows) shows occlusion of internal maxillary and occipital arteries.

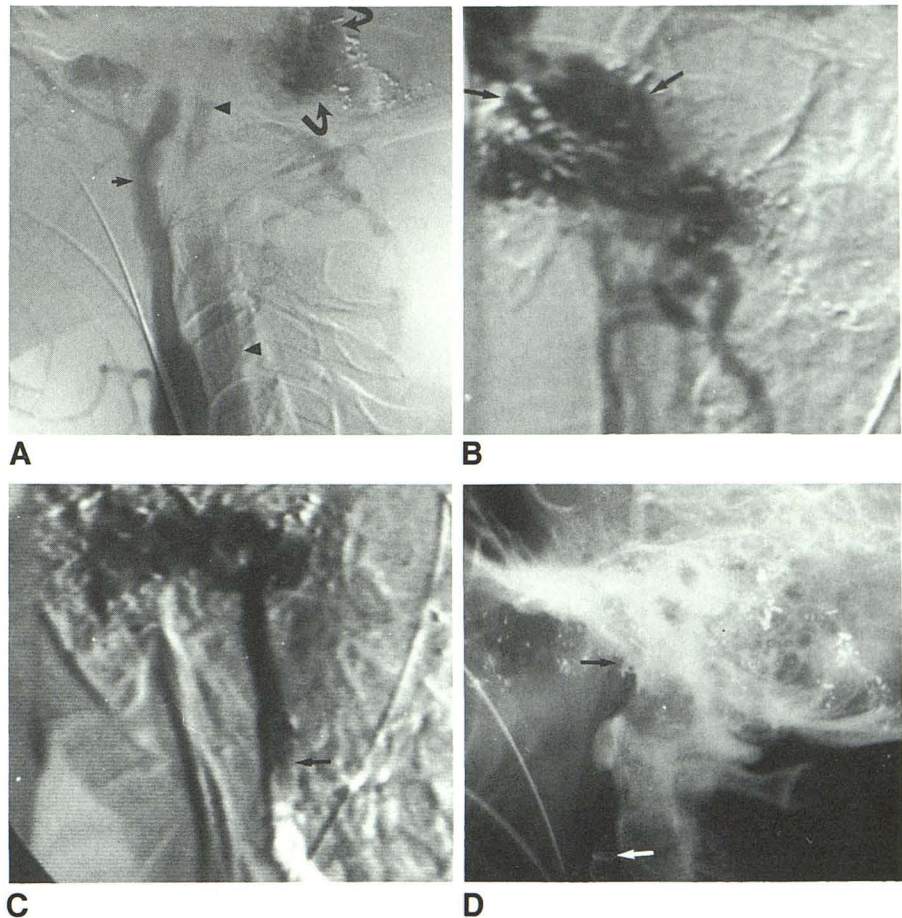


Fig. 2.—Case 2.

A, Right carotid angiography shows a fistula between carotid artery (arrow) and jugular vein (arrowheads) at base of skull with massive extravasation at mastoid area (curved arrows).

B, Anteroposterior view of digital subtraction angiography (DSA) of internal carotid artery shows contrast material also shunting into sigmoid and transverse sinus with extravasation in mastoid area (arrows).

C, Embolization DSA of internal carotid artery after insertion of steel coil (arrow) shows slow flow to mastoid area. No opacification of jugular vein was noted.

D, Vertebral angiography shows two steel coils (arrows) in embolic internal carotid artery and good opacification of distal right carotid circulation from posterior communicating artery.

- Hieshima GB, Grinnell VS, Mehringer CM. A detachable balloon for therapeutic transcatheter occlusions. *Radiology* 1981;138:227–228
- Mehringer CM, Hieshima GB, Grinnell VS, et al. Therapeutic embolization for vascular trauma of the head and neck. *AJNR* 1983;4:137–142
- Tsai FY, Hieshima GB, Mehringer CM, Grinnell V, Pribram HW. Delayed effects in the treatment of C-C fistula. *AJNR* 1983;4:357–361
- Debrum G, Lacour P, Vinuela F, et al. Treatment of 54 traumatic carotid cavernous fistulas. *J Neurosurg* 1981;55:678–692
- Dehning DO, Tsai FY. Treatment of carotid cavernous fistula by intravas-

cular balloon embolization. *Mo Med* 1986;83:213–218

- Debrum G, Lacour P, Caron JP, et al. Detachable balloon and calibrated leak balloon techniques in the treatment of cerebral vascular lesions. *J Neurosurg* 1978;49:635–649
- Gianturco C, Anderson JH, Wallace S. Mechanical device for arterial occlusion. *AJR* 1975;124:428–435
- Wallace S, Schwarten ED, Smith DC, et al. Intrarenal A-V fistulas: transcatheter coil occlusion. *J Urol* 1978;120:282–286