

Generic Contrast Agents

Our portfolio is growing to serve you better. Now you have a *choice*.



FRESENIUS
KABI

[VIEW CATALOG](#)

AJNR

Sphenopharyngeal Meningoencephalocele: Unusual Clinical and Radiologic Features

T. Boulanger, P. Mathurin, G. Dooms, M. Lambert, S. Smellie and
G. Cornelis

AJNR Am J Neuroradiol 1989, 10 (5 suppl) S80

http://www.ajnr.org/content/10/5_suppl/S80.citation

This information is current as
of May 15, 2025.

Sphenopharyngeal Meningoencephalocele: Unusual Clinical and Radiologic Features

A 42-year-old woman was admitted for further investigation of deficiency of growth hormone and gonadotropin first documented in 1969. On admission, the patient was mildly obese and of short stature (48 kg for 134 cm). There was no evidence of facial or palatal abnormality, funduscopy was normal, and both visual fields and sense of smell were intact. Clinical examination also was normal.

The following radiologic examinations were carried out: radiography of the skull; frontal and lateral hypocycloidal tomography of the sphenoid bone; angio-CT of the sella turcica; metrizamide computed cisternography; and MR imaging. The radiologic findings included a sharply demarcated funnel-shaped bony defect stretching in a slightly anterior and inferior direction between the floor of the sella turcica and the pharyngeal surface of the basisphenoid. A round structure was seen hanging beneath this defect, in the nasopharynx. This structure appeared to contain CSF, thus constituting a sphenopharyngeal meningocele (Figs. 1A and 1B).

Associated with this meningocele were numerous distortions of the structures of the sellar and parasellar region. The optic nerves were invaginated into the bony defect before joining the optic chiasm and optic tracts, which were distorted and lay in a near-vertical plane. The pituitary gland lay within the posterior region of the bony defect to which the infundibulum stretched. The third ventricle was not dilated, and there was no evidence of agenesis of the corpus callosum (Fig. 1C).

Discussion

A rare variety of encephalocele is the basal type that occurs once in every 35,000 live births [1]. The sphenopharyngeal type is the most rare [1] and also the most difficult to diagnose because no external tumor is visible (except in those instances of herniation so large that protrusion through the mouth or nares occurs). This problem may present in various clinical ways: congenital ocular anomalies, visual field defects, facial abnormalities, other congenital midline brain defects, endocrinologic anomalies, or ear-nose-throat problems, including cerebrospinal rhinorrhea [2]. However, diagnosis is radiologic. In 1985, Currarino et al. [3] described a classification based on the size of the bony defect.

Regardless of the group, Currarino et al. [3] propose the same underlying defect in embryonic development, explaining the frequent associated dysraphic anomalies. This case presents several unusual features. The means of presentation as isolated endocrine deficiencies is exceptional. It involves a 13-mm wide bony defect and thus belongs to group 3 (classification of Currarino et al. [3]), although we did not find a dilated third ventricle, as has been reported in all previous cases. No associated anomalies were found; there was no facial abnormality, even occult, and ophthalmologic examination was

normal. It is therefore interesting to recall another theory of the pathogenesis proposed by Danoff et al. [4] and McCoy [5].

In our patient, the site of the bony defect is in the medial part of the postsphenoid. Indeed, endochondral ossification of the postsphenoid originates from two lateral nuclei, allowing speculation that the defect may have resulted from inadequate medial fusion of these elements. This would explain the formed lateral walls of the basisphenoid and the absence of other associated dysraphic abnormalities. Whatever the underlying pathogenesis, the herniation must be considered secondary and aided by the absence of a dural covering in the floor of the sella at the level of the bony defect, and by an incompetent diaphragma sellae. Thus, under the influence of CSF pressure, the parasellar and sellar structures descend, which explains the endocrine findings.

In summary, the isolated endocrine findings, the anatomic configuration, and the absence of associated dysraphic anomaly characterize this exceptional case. In addition, the possibility of another developmental abnormality (bony fusion) must not be forgotten in the explanation of isolated cases without other facial abnormality.

ACKNOWLEDGMENT

We are grateful to J. Crabbe for referring this patient.

T. Boulanger
P. Mathurin
G. Dooms
M. Lambert
S. Smellie
G. Cornelis
UCL St Luc
1200 Brussels, Belgium

REFERENCES

1. Pollock JA, Newton TH, Hoyt WF. Transsphenoidal and transtentorial encephaloceles. *Radiology* 1968;90:442-453
2. Yokota A, Matsukado Y, Fuwa I, Moroki K, Nagahiro S. Anterior basal encephalocele of the neonatal and infantile period. *Neurosurgery* 1986;19(3):468-478
3. Currarino G, Maravilla KR, Salyer KE. Transsphenoidal canal (large cranio-pharyngeal canal) and its pathologic implications. *AJNR* 1985;6:39-43
4. Danoff D, Serbu J, French LA. Encephalocele extending into the sphenoid sinus. *J Neurosurg* 1966;24:684-686
5. McCoy G. Cerebrospinal rhinorrhea. A comprehensive review and a definition of the responsibility of the rhinologist in diagnosis and treatment. *Laryngoscope* 1963;73:1125-1157

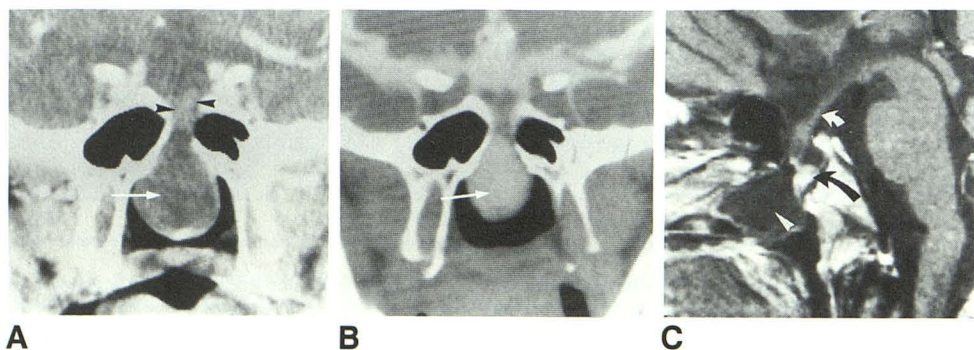


Fig. 1.—A, Coronal CT section of sella turcica shows liquid nature of mass in rhinopharynx (meningocele) (arrow) and invagination of optic nerves (arrowheads) into bony defect.

B, Coronal CT section of sella turcica during metrizamide cisternography confirms the continuity between sphenopharyngeal meningocele (arrow) and optochiasmatic cistern.

C, Midsagittal T1-weighted MR image (470/30) of sella turcica after gadolinium IV contrast shows locations of pituitary gland (black arrow), which lies posterior to bony defect, and infundibulum (white arrow). Arrowhead: meningocele pouch.