

# Generic Contrast Agents

Our portfolio is growing to serve you better. Now you have a *choice*.



FRESENIUS  
KABI

[VIEW CATALOG](#)

# AJNR

## Synovial Cysts in the Lumbar Spine: MR Characteristics

Jordan Rosenblum, Saeid Mojtahedi and Robert J. Foust

*AJNR Am J Neuroradiol* 1989, 10 (5 suppl) S94

[http://www.ajnr.org/content/10/5\\_suppl/S94.citation](http://www.ajnr.org/content/10/5_suppl/S94.citation)

This information is current as  
of May 14, 2025.

# Synovial Cysts in the Lumbar Spine: MR Characteristics

Synovial cysts are cystic lesions arising from the synovial membrane of diarthrodial joints. They may or may not be continuous with the joint space, and they are usually filled with a mucinous fluid. Clinically, the most frequent presentation is lower back pain without motor or sensory impairment [1]. Synovial cysts can present with more classic radicular symptoms, mimicking a herniated nucleus pulposus [2-4]. Before widespread use of CT scanning, the diagnosis was a difficult one radiographically. Several recent studies have described the characteristic CT findings of synovial cysts [1, 3, 5]. Review of the English-language literature reveals no description of the MR characteristics of these lesions. We report here two pathologically proved cases of synovial cysts arising from the facet joints of the lumbar spine and their correlative MR findings.

## Case Reports

### Case 1

A 50-year-old man had complained of lower back pain radiating to his right foot. He had slightly decreased strength in his right toe and parathesia involving his right leg. Plain films showed sclerosis of the facets at L4-L5. Myelogram showed a posterolateral defect on the right at L4-L5 (Fig. 1A). Postmyelogram CT suggested the possibility of a synovial cyst vs an extruded disk fragment (Fig. 1B). MR revealed a cystic lesion arising from the facet joint, isointense to CSF on both T1- and T2-weighted images. Laminectomy was performed with removal of a cystic lesion arising from the hypertrophied right L4-L5 facet joint; pathologic studies confirmed a synovial cyst.

### Case 2

A 61-year-old man had a 2-month history of lower back pain radiating to his right thigh with slight weakness of his right leg. Plain films revealed sclerosis of the facet joint. MR revealed a cystic lesion that was continuous with the facet joint. It was isointense to CSF on both T1- and T2-weighted images (Figs. 2A and 2B). The patient underwent an L4-L5 hemilaminectomy and medical facetectomy. A cystic lesion was removed, which pathologic studies showed to be a synovial cyst.

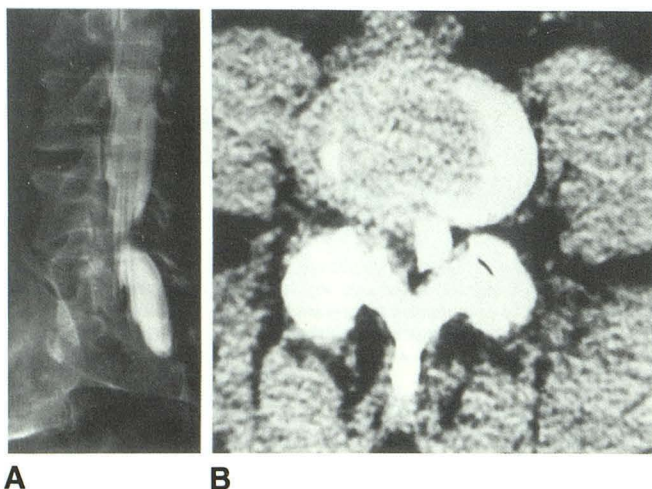


Fig. 1.—Case 1.

A, Myelogram shows extradural defect posterolaterally on the right.  
B, Postmyelogram CT reveals extradural defect with marked degenerative changes of right facet joint at L4-L5.

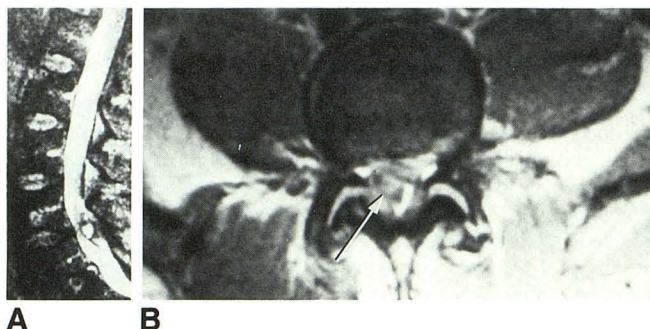


Fig. 2.—Case 2.

A, T2-weighted MR (1950/100) demonstrating a cystic lesion isointense to CSF with a low-intensity rim.

B, T2-weighted MR (1950/2100) reveals displacement of thecal sac to the left. Cystic lesion is seen to be continuous with facet joint (arrow).

## Discussion

Hemminghytt et al. [1], Casselman [3], and Mercader et al. [5] have described the characteristic CT findings of synovial cysts. These include a cystic lesion, often with a calcific rim, lying adjacent to the facet joint and of lower attenuation than the disk material. They are almost always found at the L4-L5 level and displace the thecal sac anteriorly and medially.

Recently there has been a trend toward replacing conventional CT myelography with an MR examination in the evaluation of suspected disk disease. Because the clinical symptoms may be similar, an increasing number of patients with a diagnosis of synovial cyst probably will be evaluated by MR. In the two cases we report, a cystic lesion is seen arising from the adjacent articular joint. It displaces the thecal sac anteriorly and medially. The lesion displays signal characteristics isointense to CSF on T1-weighted, balanced, and T2-weighted images. A low-intensity rim surrounds the lesion and separates it from the thecal sac, which is presumed to represent the synovial membrane surrounding the cyst. The high signal intensity on T2-weighted images allows differentiation from an extruded disk fragment, and, when the high-signal area is continuous with the synovial space of the joint (as in Fig. 2B), we think a definite diagnosis can be made. To date, we have insufficient evidence to comment on the relative efficacy of CT vs MR in diagnosing synovial cysts in the spinal column. However, the recent trend toward use of MR instead of conventional myelography and CT in the evaluation of radicular pain requires an awareness of the characteristic MR findings of synovial cysts.

Jordan Rosenblum  
Saeid Mojtahedi  
Robert J. Foust  
The University of Chicago  
Chicago, IL 60637

## REFERENCES

1. Hemminghytt S, Daniels DL, Williams AL, Haughton VM. Intraspinous synovial cysts: natural history and diagnosis by CT. *Radiology* 1982;145:375-376
2. Abrahams JJ, Wood GW, Eames FA, Hicks RW. CT-guided needle aspiration biopsy of an intraspinal synovial cyst (ganglion): case report and review of the literature. *AJNR* 1988;9:398-400
3. Casselman ES. Radiologic recognition of symptomatic spinal synovial cysts. *AJNR* 1985;6:971-973
4. Wang A, Haykal HA, Lin JC, Lee JH. Synovial cysts of the lumbar spine: CT evaluation. *Comput Radiol* 1987;11:253-257
5. Mercader J, Munoz G, Cardenal C. Intraspinous synovial cyst diagnosis by CT. *Neuroradiology* 1985;27:346-348