

Generic Contrast Agents

Our portfolio is growing to serve you better. Now you have a *choice*.



FRESENIUS
KABI

[VIEW CATALOG](#)

AJNR

MR imaging of Tolosa-Hunt syndrome.

D M Yousem, S W Atlas, R I Grossman, R C Sergott, P J Savino
and T M Bosley

AJNR Am J Neuroradiol 1989, 10 (6) 1181-1184

<http://www.ajnr.org/content/10/6/1181>

This information is current as
of May 12, 2025.

MR Imaging of Tolosa-Hunt Syndrome

David M. Yousem¹
 Scott W. Atlas¹
 Robert I. Grossman¹
 Robert C. Sergott²
 Peter J. Savino²
 Thomas M. Bosley²

The Tolosa-Hunt syndrome consists of painful ophthalmoplegia caused by cavernous sinus inflammation, which is responsive to steroid therapy. The MR features of 11 patients with the clinical diagnosis of Tolosa-Hunt syndrome were studied. Two patients had normal MR studies of the orbit and cavernous sinuses. In nine patients, abnormal signal and/or mass lesions were seen in the cavernous sinuses; in eight cases, the abnormality was hypointense relative to fat and isointense with muscle on short TR/TE images and isointense with fat on long TR/TE scans. Extension into the orbital apex was seen in eight cases. In six of nine cases the affected cavernous sinus was enlarged; in five of nine it had a convex outer margin. One patient had a thrombosed cavernous sinus and superior ophthalmic vein in addition to a cavernous sinus soft-tissue mass.

The signal intensity of Tolosa-Hunt syndrome in this limited series was similar to that of orbital pseudotumor and is confined to a limited differential diagnosis, which includes meningioma, lymphoma, and sarcoidosis.

AJNR 10:1181-1184, November/December 1989; *AJR* 154: January 1990

Since Tolosa [1] described a case of periarteritis of the cavernous carotid artery creating a painful ophthalmoplegia in 1954 there has been considerable interest in the Tolosa-Hunt syndrome (THS), an inflammatory process involving the cavernous sinus. In 1961, Hunt et al. [2] outlined six clinical criteria characterizing the syndrome: (1) steady, gnawing, retroorbital pain; (2) defects in the third, fourth, sixth, or first branch of the fifth cranial nerve, with less common involvement of the optic nerve or sympathetic fibers around the cavernous carotid artery; (3) symptoms lasting days to weeks; (4) occasional spontaneous remission; (5) recurrent attacks; and (6) prompt response to steroid therapy. Initial radiographic evaluation consisted of carotid artery and superior ophthalmic vein angiography, which often demonstrated narrowing of the carotid siphon or thrombosis of the superior ophthalmic vein and/or cavernous sinus [3-7]. While CT was initially thought to be insensitive to THS findings, modern high-resolution CT has been able to demonstrate soft-tissue abnormalities in the cavernous sinus, suggesting that THS need not be a diagnosis of exclusion [4, 8-10]. We retrospectively reviewed the MR findings in 11 patients with THS, paying special attention to intensity patterns, anatomic involvement, and vascular changes.

Materials and Methods

Since 1984, 11 patients found to have THS were evaluated by MR imaging. Clinical records and patient charts were reviewed in all cases to see that patients fulfilled the criteria of painful cranial neuropathies with deficits in the third, fourth, fifth, or sixth distribution; spontaneous remissions or prompt responses to steroid treatment; and no other identifiable cause of the disorder. Biopsies of the affected cavernous sinus were performed in three patients, all three showing nonspecific inflammatory change.

The 11 patients consisted of eight females and three males with an average age of 39 years (range, 9-75). The left cavernous sinus alone was clinically involved in nine cases, one

Received December 8, 1988; revision requested January 19, 1989; revision received March 28, 1989; accepted March 31, 1989.

Presented in part at the annual meeting of the American Society of Neuroradiology, Orlando, March 1989.

¹ Department of Radiology, Section of Neuroradiology, Hospital of the University of Pennsylvania, 3400 Spruce St., Philadelphia, PA 19104. Address reprint requests to S. W. Atlas.

² Neuroophthalmology Service, Wills Eye Hospital, Philadelphia, PA 19107.

0195-6108/89/1006-1181

© American Society of Neuroradiology

case had bilateral involvement, and one case was affected only on the right side. The third cranial nerve was affected in nine cases, the fourth in five cases, the sixth in three cases, and the first division of the fifth nerve in three cases (some cases had multiple nerves involved).

The patients were scanned on a 1.5-T GE MR scanner, and sagittal, coronal, and axial short TR/TE images were obtained with parameters of 500–800/20–25/1,2 (TR range/TE range/excitations), 128,192 × 256 matrix, 3-mm slice thickness, and 14- or 16-cm field of view. Double echo long TR coronal or axial scans were used with 2500–3000/30, 80/2, 128,192 × 256 matrix, 3- to 5-mm thickness, and 20-cm field of view.

Results

Two patients had normal MR examinations of the cavernous sinus. Of the nine patients with positive MR findings in the affected cavernous sinus, eight had low-signal tissue with respect to fat but isointense with muscle on short TR/TE images of the cavernous sinus. Long TR/TE images of these eight patients revealed isointensity with fat in the area of abnormality (Figs. 1 and 2). The one case of different signal intensities was complicated by cavernous sinus thrombosis—this lesion was hyperintense relative to muscle on short TR/TE scans and hyperintense relative to fat on long TR/TE scans, suggesting subacute clot in the sinus. Similar intensity changes were found in the patient's superior ophthalmic vein. Three cases showing narrowing of the cavernous carotid were identified (Fig. 2). In eight cases, extension into the ipsilateral orbital apex was detected (Fig. 3). The signal intensity of the lesion did not change as it entered the orbit. No skip lesions were found. All cases appeared to involve the apex through contiguous spread.

When compared with the contralateral normal cavernous sinus, the cavernous sinus affected by THS was enlarged in

six of the nine patients with abnormal MR examinations. The outer dural margin was convex and bulging laterally in five of nine cases; the normal appearance is a concave outer contour. Soft tissue was seen medial to the carotid artery in only two of the nine patients with abnormal scans.

Three of the nine patients with positive MR studies had repeat MR scans after steroid therapy and complete or partial resolution of symptoms. In two cases the mass in the cavernous sinus was smaller in size, but still present. In a third case no residual abnormality was detected.

Clinically, the two cases that were normal on MR behaved similar to those with positive MR findings. Both had isolated left third-nerve palsies with retroorbital pain. One resolved spontaneously in less than a month, without recurrence. After the normal MR scan, the other patient was treated as if she had an ophthalmoplegic migraine, was placed on propranolol, and had resolution of her symptoms.

Discussion

THS has been well-defined in terms of clinical criteria for diagnosis, but the pathologic and radiologic literature has lagged behind the clinical description of the entity. This is due in part to the precarious location and small size of the lesion in a region difficult to image or sample by biopsy; namely, the cavernous sinus. For these reasons the diagnosis of THS has been one of exclusion. Only with the advent of CT and MR imaging could lesions of the cavernous sinus be visualized directly.

The pathologic correlation in cases of THS is sparse owing to its lack of specificity and a reluctance to biopsy the cavernous sinus if steroid therapy is promptly effective. Tolosa's original article [1] described a granulomatous periarteritis of the cavernous carotid, whereas Hunt et al. [2] wrote of a proliferation of fibroblasts, lymphocytes, and plasma cells

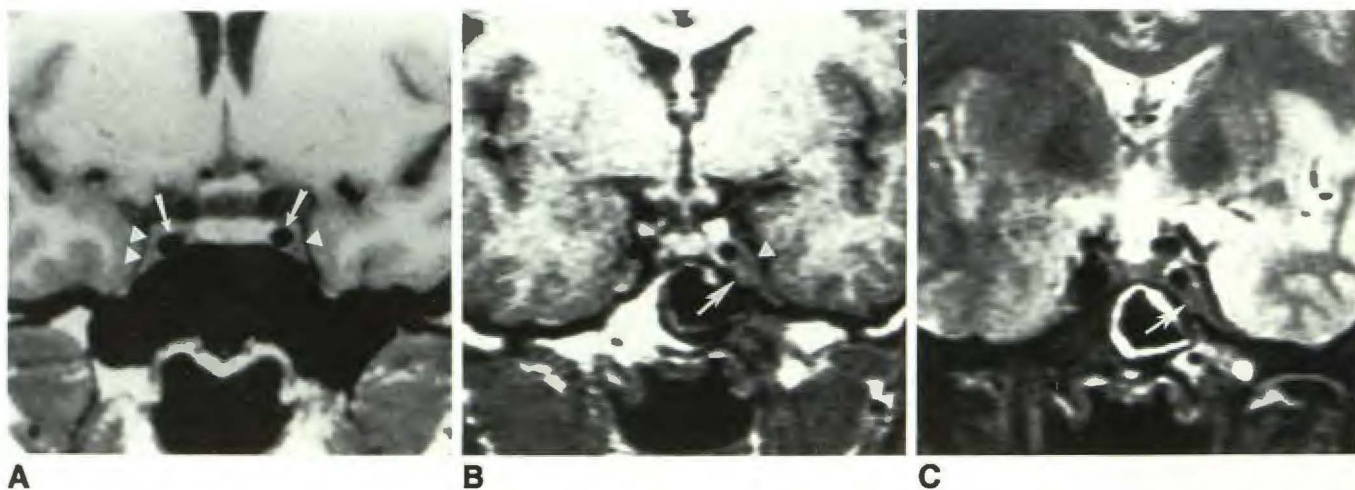


Fig. 1.—Typical MR signal characteristics of Tolosa-Hunt syndrome (biopsy confirmed) in patient with a painful third-nerve palsy. Normal comparison view of cavernous sinus is also shown.

A, Coronal 600/20 scan of normal volunteer demonstrates normal low intensity of cavernous sinuses with intracavernous carotid artery flow void (arrows). Note concave lateral dural reflection of cavernous sinus (arrowheads).

B, Coronal 600/25 scan of patient with Tolosa-Hunt syndrome shows low-intensity lesion in left cavernous sinus (arrow) that approaches left cavernous carotid above. The lesion is isointense with orbital muscles and is hypointense relative to neighboring fat. Lateral border of affected cavernous sinus is convex (arrowhead).

C, Same lesion (arrow) on coronal 2500/80 scan is low in intensity.

Fig. 2.—Tolosa-Hunt syndrome with narrowing of left cavernous carotid artery in patient with third cranial nerve palsy and pain in distribution of first division of trigeminal nerve.

A, Coronal 600/20 scan demonstrates encasement and narrowing of left cavernous carotid artery (*arrow*) by low-intensity tissue. Note difference in caliber from right carotid.

B, Coronal 3000/80 scan shows absence of bright signal; the lesion is just perceptible inferiorly (*arrowheads*). In all cases the short TR/TE scans were best for detection of Tolosa-Hunt syndrome.

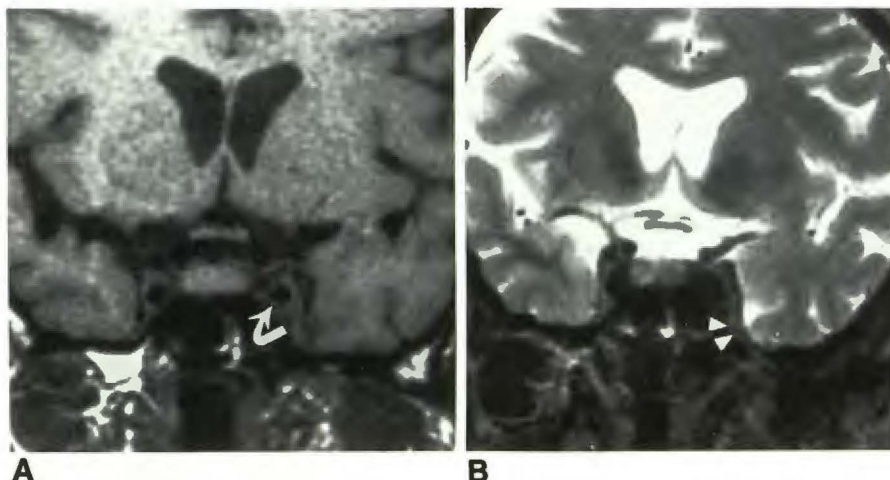
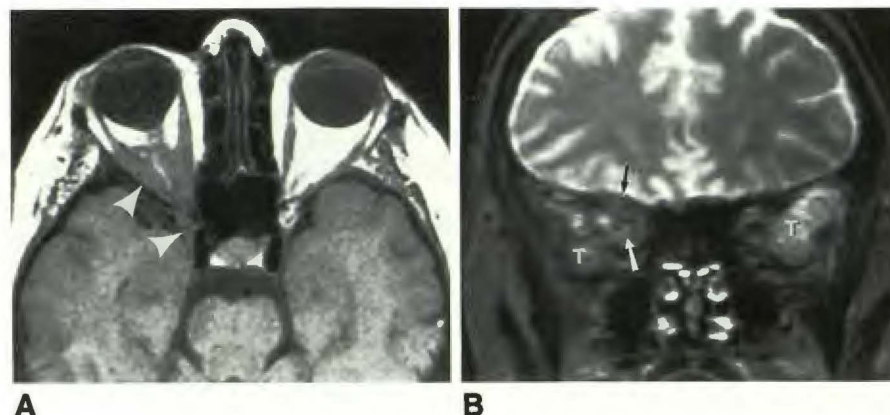


Fig. 3.—Extension of inflammatory lesion into orbit in patient with extraocular muscle deficits and retroorbital pain. Biopsy proved.

A, Axial 800/20 scan obtained late in the patient's course demonstrates a lesion isointense with muscle in right cavernous sinus (*arrowheads*) as well as thickening of lateral and medial rectus, optic nerve, and orbital apex fat infiltration. These orbital findings are typical of orbital pseudotumor. Serial CT scans had shown a lesion that originated in the cavernous sinus, but over a 1-month interval had spread to the orbital apex.

B, Coronal 3000/90 scan shows abnormal signal in right orbit (*arrows*) similar in intensity to subcutaneous fat. Temporal lobes (T) are also seen on this image.



within the adventitia of the vessels. Campbell and Okazaki [11] found a necrotizing vasculitis with chronic nongranulomatous inflammation in one case and noted the overlap of pathologic features in orbital pseudotumor and THS. All three of our biopsied cases revealed nonspecific inflammation. Cultures were negative and no neoplasm could be detected. Granulomas were not discovered; lymphocytes and fibroblasts predominated.

Before CT the radiographic evaluation for THS consisted of angiography and plain films to exclude aneurysms, meningiomas, metastases, and pituitary masses. Angiographic features in THS include narrowing of the carotid siphon, occlusion of the superior ophthalmic vein, nonvisualization of the cavernous sinus, and reversibility of findings with steroid use [3–7]. However, a normal orbital venogram or arteriogram does not exclude THS, and one series found no vascular abnormality in 16 of 26 cases [7]. Plain films may show sellar erosions, but are usually normal [6]. In seven of eight cases reported by Aron-Rosa et al. [4], CT scans were reportedly normal, which perpetuated the prevailing view that THS was still a diagnosis of exclusion. However, since 1978 sporadic cases of positive CT studies in patients with THS have been reported [8, 9]. Kwan et al. [10] used CT to study five patients with clinically suspected THS and found asymmetric enlargement of a cavernous sinus, abnormal nodular enhancement

of the prepontine cistern, or inflammatory soft-tissue density in the orbital apices in four of five cases; the fifth case was an epidermoid. All four positive cases showed resolution of the CT findings after steroid therapy.

Our study complements an earlier MR study of orbital pseudotumor (OP), a lesion with similar histopathology. OP produced low signal intensity on spin-echo sequences in 11 of 12 cases in the series by Atlas et al. [13], possibly caused by the fibrous nature of the inflammatory process resulting in a decrease in mobile proton density [12, 13]. Additionally, the fat of the orbit lost signal intensity when invaded by idiopathic orbital inflammation [12, 13]. The intensity features of OP (isointense relative to muscle on short TR/TE images and to fat on long TR/TE images) are similar to those found in most THS cases, supporting the hypothesis that THS may not be a separate disease from OP but a related histopathologic entity in a different anatomic location.

The clinical differential diagnosis of steroid-responsive painful ophthalmoplegia includes metastases, carotid-cavernous fistulae, pituitary adenomas, vasculopathic cranial neuropathy, aspergillus invasion, Wegener's granulomatosis, sarcoidosis, lymphoma, and ophthalmoplegic migraine [8, 10, 14–18]. Meningiomas and aneurysms may rarely cause pain when of sufficient size. While metastases, pituitary adenomas, aspergillus infection, some meningiomas, and some cases of

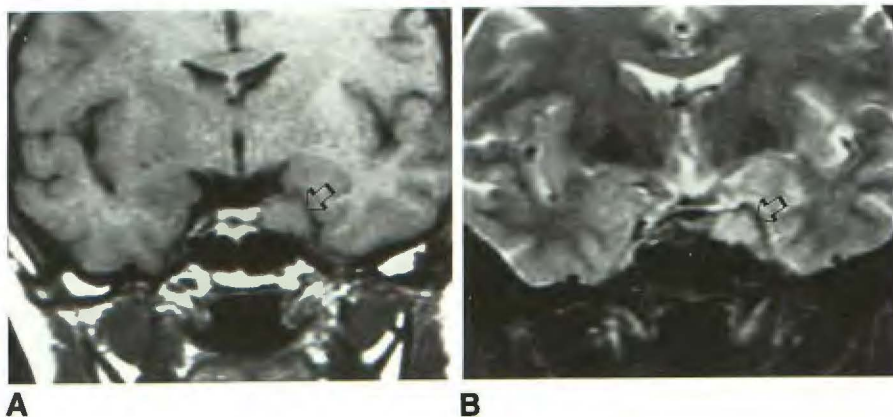


Fig. 4.—Left cavernous sinus meningioma: one of the differential diagnostic entities with signal characteristics similar to Tolosa-Hunt syndrome. Surgically proved.

A, Low-intensity mass in left cavernous sinus on 600/20 scan elicited a painful third-nerve palsy (arrow).

B, This meningioma is hyperintense relative to fat on 3000/80 scan. Some meningiomas, lymphomas, metastatic foci, and sarcoid deposits may have intensity characteristics similar to Tolosa-Hunt syndrome and may extend into orbital apex.

lymphoma are often hyperintense relative to fat on long TR images, sarcoidosis, lymphoma, and meningiomas may display hypointensity or isointensity on short TR/TE and long TR/TE sequences, as in THS [13] (Fig. 4). However, sarcoidosis and lymphoma will often have systemic symptoms and meningiomas will not resolve with steroid therapy. Vascular abnormalities such as arteritides, cavernous-carotid fistulae, ophthalmoplegic migraines, and aneurysms are not associated with masses in the cavernous sinus or orbital apex as in THS.

In the appropriate clinical setting of painful ophthalmoplegia, MR findings of a cavernous sinus abnormality that is isointense with muscle on short TR/TE images and isointense with fat on long TR/TE images suggests the diagnosis of THS. With these MR features and a prompt response to steroid therapy, THS need not merely be a diagnosis of exclusion, although other lesions may have similar intensity characteristics. A small percentage of patients with this clinical syndrome may have lesions not detectable with current imaging techniques.

REFERENCES

1. Tolosa EJ. Periarteritic lesions of the carotid siphon with clinical features of carotid intracranial aneurysms. *J Neurol Neurosurg Psychiatry* 1954;17:300-302
2. Hunt WE, Meagher JN, LeFever H. Painful ophthalmoplegia: its relation to indolent inflammation of the cavernous sinus. *Neurology* 1961;11:56-62
3. Sondheimer FK, Knapp J. Angiographic findings in the Tolosa-Hunt syndrome: painful ophthalmoplegia. *Radiology* 1973;106:105-112
4. Aron-Rosa D, Doyon D, Salamon G, Michotey P. Tolosa-Hunt syndrome. *Ann Ophthalmol* 1978;10:1161-1168
5. Takeoka T, Gotoh F, Fukuchi Y, Inagaki Y. Tolosa-Hunt syndrome. *Arch Neurol* 1978;35:219-223
6. Polsky M, Janicki PC, Gunderson CH. Tolosa-Hunt syndrome with sellar erosion. *Ann Neurol* 1979;6:129-131
7. Muhletaler CA, Gerlock AJ Jr. Orbital venography in painful ophthalmoplegia (Tolosa-Hunt syndrome). *AJR* 1979;133:31-34
8. Neigel JM, Rootman J, Robinson RG, Durity FA, Nugent RA. The Tolosa-Hunt syndrome: computed tomographic changes and reversal after steroid therapy. *Can J Ophthalmol* 1986;21:287-290
9. Ketonen L, Teravainen H, Pilke A, Katevuo K. Computed tomography in a case of ophthalmoplegic syndrome. *Ann Clin Research* 1985;17:37-42
10. Kwan ESK, Wolpert SM, Hedges TR III, Laucella M. Tolosa-Hunt syndrome revisited: not necessarily a diagnosis of exclusion. *AJNR* 1987;8:1067-1072, *AJR* 1988;150:413-418
11. Campbell RJ, Okazaki H. Painful ophthalmoplegia (Tolosa-Hunt variant): autopsy findings in a patient with necrotizing intracavernous carotid vasculitis and inflammatory disease of the orbit. *Mayo Clinic Proc* 1987;62:520-526
12. Sobel DF, Kelly W, Kjos BO, Char D, Brandt-Zawadzki M, Norman D. MR imaging of orbital and ocular disease. *AJNR* 1985;6:259-264
13. Atlas SW, Grossman RI, Savino PJ et al. Surface-coil MR of orbital pseudotumor. *AJNR* 1987;8:141-146
14. Kline LB. The Tolosa-Hunt syndrome. *Surv Ophthalmol* 1982;27:79-95
15. Koppel BS. Steroid-responsive painful ophthalmoplegia is not always Tolosa-Hunt. *Neurology* 1987;37:544
16. Spector RH, Fiandaca MS. The "sinister" Tolosa-Hunt syndrome. *Neurology* 1986;36:198-203
17. Kline LB, Chandra-Sekan B. Pitfalls in computed tomographic evaluation of the cavernous sinus. *Surv Ophthalmol* 1985;29:293-296
18. Hunt WE. Tolosa-Hunt syndrome: one cause of painful ophthalmoplegia. *J Neurosurg* 1976;44:544-549