

# Generic Contrast Agents

Our portfolio is growing to serve you better. Now you have a *choice*.



FRESENIUS  
KABI

[VIEW CATALOG](#)

# AJNR

## **CT demonstration of cavernous sinus fat.**

D D Stricof, T O Gabrielsen, J T Latack, S S Gebarski and W F Chandler

*AJNR Am J Neuroradiol* 1989, 10 (6) 1199-1201

<http://www.ajnr.org/content/10/6/1199>

This information is current as  
of May 11, 2025.

# CT Demonstration of Cavernous Sinus Fat

Daniel D. Stricof<sup>1</sup>  
 Trygve O. Gabrielsen<sup>1</sup>  
 Joseph T. Latack<sup>1</sup>  
 Stephen S. Gebarski<sup>1</sup>  
 William F. Chandler<sup>2</sup>

CT demonstration of cavernous sinus fat deposits has been described as abnormal and potentially a specific sign of Cushing disease. CT scans of 100 patients without biochemical or clinical evidence of Cushing disease and of 10 patients with Cushing disease were studied retrospectively. Twenty-seven percent of the non-Cushing patients demonstrated fat in one or both cavernous sinuses. Forty percent of Cushing disease patients had detectable cavernous sinus fat. While fat deposits were more frequent in the Cushing disease group, this was not statistically significant ( $p = > .6$ ). CT demonstration of cavernous sinus fat ordinarily should be regarded as a normal finding.

*AJNR* 10:1199-1201, November/December 1989

CT demonstration of cavernous sinus fat deposits has been described as abnormal and a potentially specific sign of Cushing disease [1]. We have, however, observed cavernous sinus fat in many patients without Cushing disease. Gross anatomic and histologic studies also have described fat deposition within the cavernous sinus as a normal finding [2, 3]. These conflicting observations led to a retrospective study to determine the frequency and variable appearance of cavernous sinus fat demonstrated by CT.

## Materials and Methods

High-resolution, thin-section CT scans of the cavernous sinus regions of 100 consecutive patients without clinical or biochemical evidence of Cushing disease were examined retrospectively for the presence of fat within the cavernous sinuses. Most of these patients had been evaluated for temporal bone or non-Cushing pituitary abnormalities. A similar retrospective review was performed of the preoperative CT scans of 10 patients who had biochemical and subsequent surgical verification of Cushing disease.

CT scans were obtained on GE 8800 or 9800 scanners with 1.5-mm-thick contiguous axial sections after the IV bolus infusion of 150 ml of 60% iodinated contrast medium. In most patients, 1.5- or 3.0-mm-thick contiguous coronal sections were also obtained. Region-of-interest measurements were made of low-attenuation areas suspected of being fat deposits. Mean Hounsfield numbers between -20 and -100 were considered diagnostic of fat. Care was taken to avoid measuring streak artifacts and partial volume averaging from air in the sphenoid sinus. Fat found in the most anterior part of the cavernous sinus was thought to be a normal extension of orbital fat through the superior orbital fissure [1].

## Results

The average age, sex, and amount of fat in the cavernous sinuses of the Cushing and non-Cushing patients are listed in Tables 1 and 2. Of the 100 patients without Cushing disease, 27 had identifiable fat in one or both cavernous sinuses. Of the 10 patients with Cushing disease, four had fat deposits in one or both cavernous sinuses. Diameter of fat deposits was judged as small (up to 4 mm), moderate (4-

Received October 27, 1986; revision requested December 16, 1986; revision received April 17, 1989; accepted April 25, 1989.

Presented in part at the annual meeting of the American Society of Neuroradiology, San Diego, January 1986.

<sup>1</sup> Department of Radiology, Division of Neuroradiology, University of Michigan Hospital, B1D530F-0030, 1500 E. Medical Center Dr., Ann Arbor, MI 48109. Address reprint requests to T. O. Gabrielsen.

<sup>2</sup> Department of Surgery, Section of Neurosurgery, University of Michigan Hospital, Ann Arbor, MI 48109.

0195-6108/89/1006-1199

© American Society of Neuroradiology

**TABLE 1: Patients Without Cushing Disease**

	Number of Patients	Average Age	Female/Male
No demonstrable deposits	73	46	39/34
Small deposits of fat (up to 4 mm)	14	42	10/4
Moderate deposits (4–7 mm)	11	48	5/6
Large deposits (> 7 mm)	2	69	0/2

**TABLE 2: Patients with Cushing Disease**

	Number of Patients	Average Age	Female/Male
No demonstrable deposits	6	48	5/1
Small deposits of fat (up to 4 mm)	1	32	1/0
Moderate deposits (4–7 mm)	2	38	2/0
Large deposits (> 7 mm)	1	38	1/0

7 mm), and large (> 7 mm) (Figs. 1 and 2). There was a tendency for more frequent and larger amounts of fat to occur in older patients within the non-Cushing disease group. Fat deposits tended to be larger in the Cushing group; however, there was considerable overlap. While fat was found more frequently in the cavernous sinuses of Cushing patients (40% compared with 27%), this is not statistically significant ( $p = > .6$ ).

## Discussion

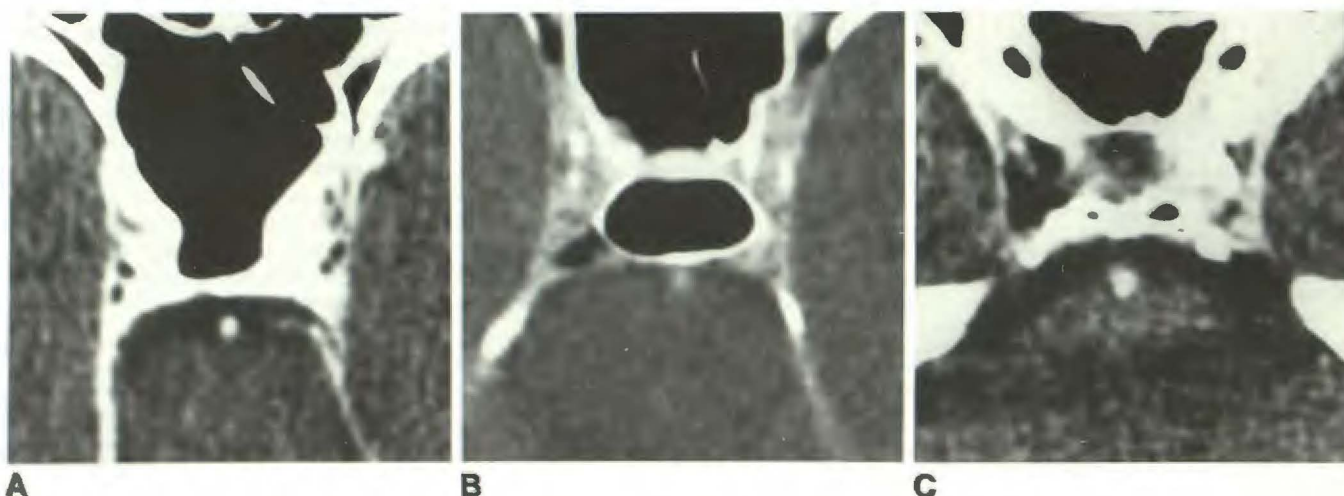
The normal presence of fat within the cavernous sinus is a reported but relatively obscure anatomic fact [2]. In Parkinson's study [2], gross dissection revealed presence of fat in all cadaver specimens. Microscopically, these fat collections represent normal fat cells between the venous channels of the cavernous sinus [2, 3].

The CT demonstration of cavernous sinus fat has been mentioned previously in patients without Cushing disease [1, 4], although its frequency in a large series has not been

reported. The occurrence of cavernous sinus fat in our group of Cushing disease patients (4/10; 40%) is essentially identical to that reported by Bachow et al. (6/16; 37.5%) [1]. However, they did not identify fat in the cavernous sinuses in a group of 30 randomly selected patients without Cushing disease. Fat in the cavernous sinuses became more frequent and more prominent with increasing age in our study. It is possible that there may have been a significant difference in the mean age of the patients studied by Bachow et al. and our group, since they did not state the age of their patients. Other than a possible age difference, it is difficult to explain the discrepancy between the two studies. It is interesting that the average age of the two patients with large fat deposits in our non-Cushing disease group was 69, 21 years older than the average age of the patients with moderate deposits. However, there also were several elderly patients in our control group who had little, and even no demonstrable cavernous sinus fat.

The size of our Cushing disease sample admittedly is small, so that it justifiably may be argued that this sample is too small a group from which to derive a definite statement regarding statistically significant differences in comparison with the large control group. The number of patients with well documented Cushing disease having accessible high-resolution, thin-section CT scans and operative-pathologic correlation in our institution limited the size of this sample. Nevertheless, the frequency of cavernous sinus fat in this group is consistent with the frequency in the slightly larger group reported by Bachow et al. [1]. We were mostly interested in studying the frequency and appearance of cavernous sinus fat in a larger control group of non-Cushing disease patients, which demonstrated a 27% frequency of fat deposition in the cavernous sinuses on CT scans.

No attempt was made to match the two groups regarding sex, age, or body weight versus height. We had no control over the fact that nine of 10 Cushing disease patients were women. The control group CT scans were obtained by selecting 100 consecutive CT examinations, with satisfactory high-resolution, thin-section CT demonstration of the cavernous



**Fig. 1.—A–C, Three patients without Cushing disease demonstrating small (A), moderate (B), and large (C) cavernous sinus fat deposits.**

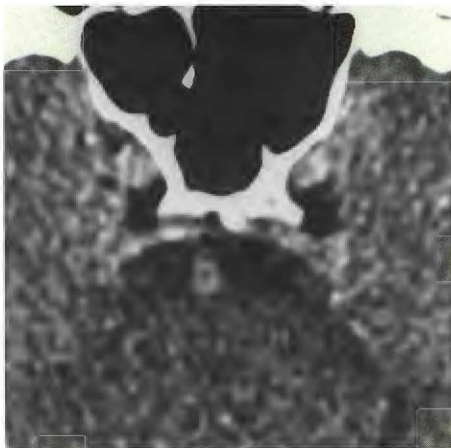


Fig. 2.—Large cavernous sinus fat deposits in a patient with Cushing disease.

ous sinuses and no clinical evidence of Cushing disease as the only criterion. It was thought that this would best reflect

the expected frequency and appearance of cavernous sinus fat in non-Cushing disease patients in ordinary clinical practice.

Although the frequency and amount of cavernous sinus fat may be greater in Cushing disease patients and possibly also in older and/or obese non-Cushing disease patients, mere CT demonstration of cavernous sinus fat ordinarily should be regarded as a normal finding.

#### REFERENCES

1. Bachow TB, Hesselink JR, Aaron JO, Davis KR, Taveras JM. Fat deposition in the cavernous sinus in Cushing disease. *Radiology* 1984; 153: 135-136
2. Parkinson D. Anatomy of the cavernous sinus. In: Smith JL, ed. *Neuro-ophthalmology. Symposium of the University of Miami and the Bascom Palmer Eye Institute*. St. Louis: Mosby, 1972;73-101
3. Bol'Shakov OP. Macroscopic and microscopic structural features of the cavernous sinus. *Fed Proc (Transl. suppl.)* 1964; 23:308-311
4. Hasso AN, Pop PM, Thompson JR, et al. High resolution thin section computed tomography of the cavernous sinus. *RadioGraphics* 1982; 2: 83-100