

Generic Contrast Agents

Our portfolio is growing to serve you better. Now you have a *choice*.



[VIEW CATALOG](#)

AJNR

Bilateral intraorbital meningoencephaloceles and associated midline craniofacial anomalies: MR and three-dimensional CT imaging.

R A Levy, S L Wald, P A Aitken and R H Dorwart

AJNR Am J Neuroradiol 1989, 10 (6) 1272-1274

<http://www.ajnr.org/content/10/6/1272.citation>

This information is current as
of May 11, 2025.

Bilateral Intraorbital Meningoencephaloceles and Associated Midline Craniofacial Anomalies: MR and Three-Dimensional CT Imaging

Richard A. Levy,^{1,2} Steven L. Wald,³ Phil A. Aitken,⁴ and Robert H. Dorwart¹

Developmental midline abnormalities involving facial, optic, cranial, and cerebral structures are complex anomalies that require a multidisciplinary therapeutic approach. Radiologic evaluation requires identification of cerebral anatomy, orbital structures, facial bones, and the anterior fossa as well as the relationships of these structures to one another. We report an unusual combination of low-lying cribriform plate, bilateral intraorbital meningoencephaloceles, bilateral hypoplasia of the nasolacrimal ducts and optic nerves, partial atrophy of the corpus callosum, and bilateral frontal and temporal lobe hypoplasia with associated large CSF spaces.

Case Report

A 5-week-old boy was referred for evaluation of hypertelorism. Examination revealed a saddle-nose-type deformity with large bilateral medial cystic masses in the orbits (Fig. 1). The masses transilluminated but did not pulsate. Extraocular motility appeared intact although diminished by the masses. Attempts to probe the lacrimal ducts were unsuccessful. No clefting of the lip or palate was evident. The anterior fontanelle and cranial sutures were normal. Neurologic examination was remarkable for mild bilateral hypoplasia of the optic nerve heads.

CT scans of the brain and facial structures were obtained by using 3-mm contiguous axial sections without gantry angulation on a GE 9800 scanner. Three-dimensional reconstructions of the orbits and anterior cranial fossa were obtained by using the 3D98 software package (Figs. 2A–2C). MR images of the brain (Figs. 3A–3D) were obtained by using sagittal, axial, and coronal T1-weighted, 600/20/1 (TR/TE/excitations), and axial proton-density, 2500/30/1, and T2-weighted, 2500/80/1, spin-echo sequences. Section thickness on all scans was 5 mm with a 1.5-mm interslice gap on sagittal and coronal images and a 2.5-mm interslice gap on the axial sections. A GE 1.5-MR scanner was used for all images.

Surgery consisted of a bifrontal craniotomy performed under general anesthesia. The underlying dura appeared normal. Upon opening the dura, a thick, filmy, white arachnoid membrane was evident and was filled with fluid chemically similar to CSF. The membrane was

pathologically confirmed as arachnoid. The frontal lobe was abnormal with several vertical sulci but normal gyri; the temporal lobe appeared normal. Cerebral tissue extended from the frontal lobe toward the cribriform plate, which was in an unusually low position. Bilateral olfactory nerves were seen. The falx was incompletely developed. Two tongues of cerebral tissue exited the skull through small bilateral bone defects located superior and lateral to the low-lying cribriform plate. The encephalocele stalk was amputated and evacuated from the medial orbit. Attempts to remove the meningeal capsule from the orbit were unsuccessful because it adhered to the periorbital. The

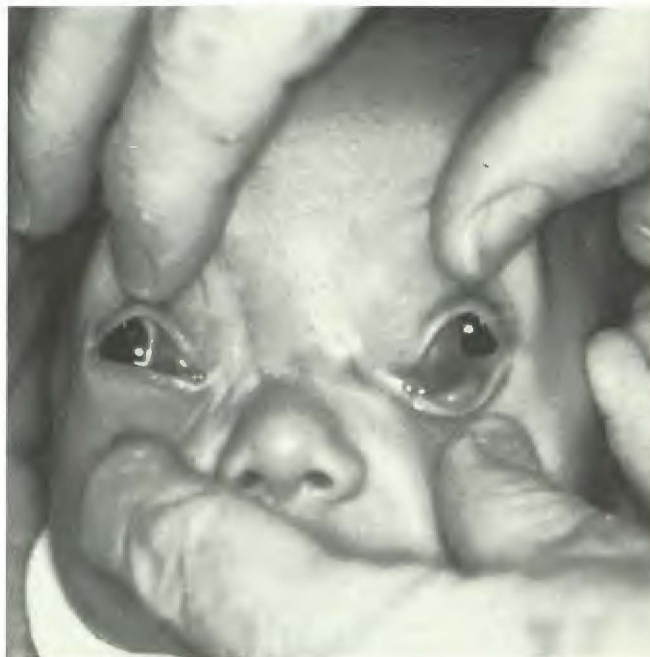

Fig. 1.—Preoperative photograph of patient demonstrates apparent hypertelorism with bilateral medial intraorbital cystic masses. Note saddle-nose deformity.

Received January 19, 1989; revision requested February 15, 1989; revision received May 8, 1989; accepted May 10, 1989.

¹ Department of Radiology, Medical Center Hospital of Vermont, Burlington, VT 05401.

² Present address: Department of Radiology, Health Sciences Center, SUNY, 750 E. Adams St., Syracuse, NY 13210. Address reprint requests to R. A. Levy.

³ Department of Neurological Surgery, Medical Center Hospital of Vermont, Burlington, VT 05401.

⁴ Department of Ophthalmology, Medical Center Hospital of Vermont, Burlington, VT 05401.



Fig. 2.—**A**, Three-dimensional CT reconstruction of anterior cranial fossa. Perspective is that of looking from above left orbital roof toward right orbit. There is a low-lying cribriform plate (*white arrow*) as well as osseous defect (*black arrow*) in anteromedial wall of right orbit through which meningoencephalocele passes from cribriform region into right orbit. A symmetric osseous defect of left orbit is not seen on this view.

B, Three-dimensional CT reconstruction of right orbit. Perspective is that of looking toward medial wall of right orbit from in front. *Black arrow* denotes frontal process of zygomatic bone. *White arrow* points to osseous defect at juncture of ethmoid, frontal, maxillary, and lacrimal bones through which meningoencephalocele from low-lying midline brain passes into orbit.

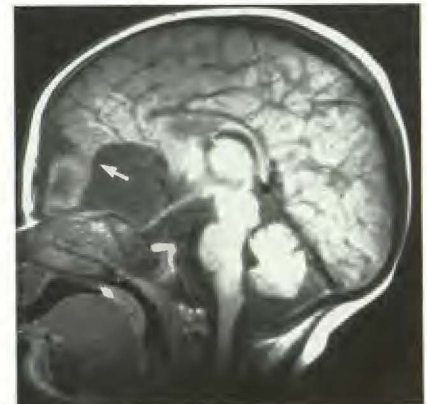C, Three-dimensional CT reconstruction of left orbit shows symmetric osseous defect (*white arrow*) similar to that in **B**. *Black arrow* points to frontal process of zygomatic bone.

Fig. 3.—**A**, Midsagittal T1-weighted MR image of brain demonstrates parenchyma (*white arrow*) extending into deepened anterior cranial fossa in region of low-lying cribriform plate. Note absence of rostral portion of corpus callosum.

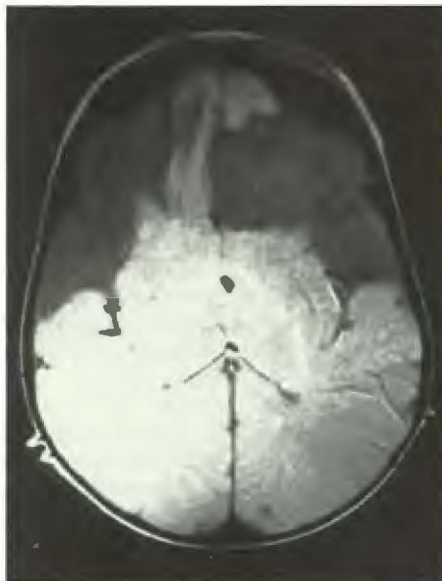B, Axial T1-weighted image of brain shows large frontotemporal CSF collections with interposed segment of brain parenchyma extending far anteriorly.

C, Coronal T1-weighted MR image of brain indicates that the large bilateral CSF collections are separate from the lateral ventricles.

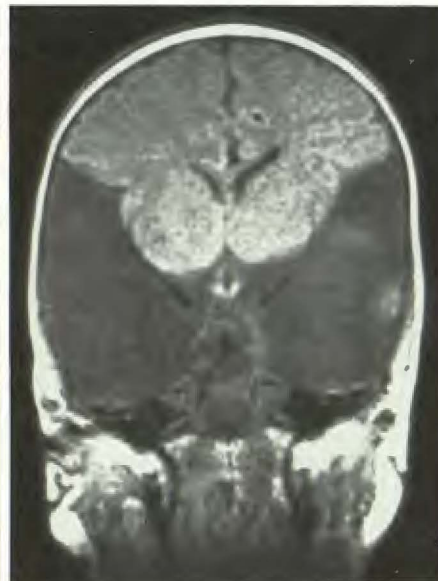
D, Axial T1-weighted MR image of brain demonstrates entrance of bilateral meningoencephaloceles from low-lying midline brain tissue into orbits at sites corresponding to osseous defects in Figs. 2B and 2C (*white arrows*). Note that gliotic brain tissue is located at medial orbit with meningocele component of meningoencephalocele located more laterally. (*White arrows* are situated within these meningoceles.) Globes are displaced laterally by meningoencephaloceles. Curvilinear high-signal intensity areas at posterior margins of meningocele components of meningoencephaloceles may represent chemical shift artifacts.



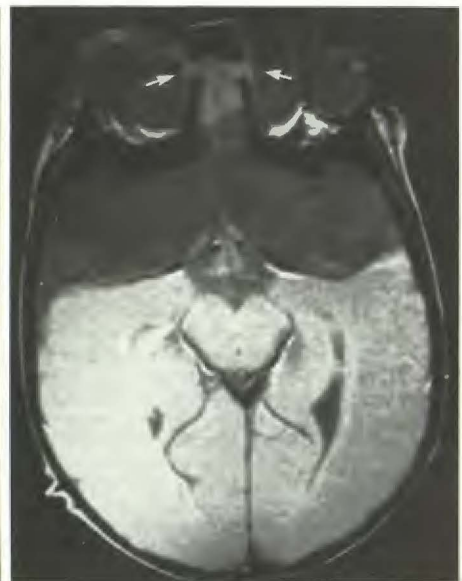A



B



C



D

frontal and subfrontal dura were repaired by using cadaveric dura after further removal of the filmy arachnoid and opening of this space into the suprasellar cistern. The optic nerves, chiasm, and carotid arteries appeared normal. The tissue in the medial orbits represented gliotic, poorly organized brain with the meningeal component of the meningoencephalocele located lateral to this gliotic tissue (Fig. 3D).

Discussion

A multifactorial sequence of embryologic events is a workable hypothesis for an explanation of the findings in this patient. Development of the major facial and cranial structures including the lip, optic nerve, and globe occurs during the fourth to eighth embryological week. Although the events resulting in the formation of the corpus callosum are poorly understood, it is believed that this structure develops somewhat later than the facial and cranial elements [1].

The bilateral frontotemporal structures encased by arachnoid are probably not true arachnoid cysts. The structurally abnormal temporal and frontal lobes in association with a lack of mass effect suggest to us that a primary event in this region resulted in abnormal development and embryogenesis. The space left by this tissue failure was then filled by CSF. Atrophy of the rostral portion of the corpus callosum is consistent with these findings and suggests that they occurred later than the facial anomalies in embryogenesis.

The current concept for the pathogenesis of encephaloceles states that they represent a primary anomaly of forma-

tion and separation of the neural tube from the surface associated with a defect in the development of its skeletal cover [2]. In our case, this was exemplified by the intraoperative difficulty in separating the meningoceles from the periorbita and the associated medial orbital osseous defects.

The evaluation of facial and cerebral abnormalities with MR imaging is likely to provide superior information than that routinely available from CT [3]. In addition to providing the surgeon with multiple views of the brain in different planes, the relationships of abnormal or ectopic brain tissue with the cranial structures can be clearly demonstrated. Three-dimensional CT imaging has been used in the evaluation of craniofacial abnormalities in children but anatomicopathologic correlation is not frequently reported.

The complementary role of MR imaging and three-dimensional CT is clearly demonstrated in this patient with a complex craniofacial malformation that was confirmed at surgery.

REFERENCES

1. Naidich TP, McLone DG, Bauer BS, Kernahan DA, Zapparackas ZG. Midline craniofacial dysraphism. Midline cleft upper lip, basal encephalocele, callosal agenesis and optic nerve dysplasia. In: Humphreys RP, ed. *Concepts in pediatric neurosurgery*. Basel: Karger, 1983:186-207
2. Nager GT. Cephaloceles. *Laryngoscope* 1987;97:77-84
3. Lusk RP, Dunn VD. Magnetic resonance imaging in encephaloceles. *Ann Otol Rhinol Laryngol* 1986;95:432-433