

# Generic Contrast Agents

Our portfolio is growing to serve you better. Now you have a *choice*.



[VIEW CATALOG](#)

# AJNR

## **Aneurysms of the petrous portion of the internal carotid artery: results of treatment with endovascular or surgical occlusion.**

V V Halbach, R T Higashida, G B Hieshima, C F Dowd, S L Barnwell, M S Edwards and M Melicharek

This information is current as  
of May 13, 2025.

*AJNR Am J Neuroradiol* 1990, 11 (2) 253-257  
<http://www.ajnr.org/content/11/2/253>

# Aneurysms of the Petrous Portion of the Internal Carotid Artery: Results of Treatment with Endovascular or Surgical Occlusion

Van V. Halbach<sup>1,2</sup>  
 Randall T. Higashida<sup>1,2</sup>  
 Grant B. Hieshima<sup>1,2</sup>  
 Christopher F. Dowd<sup>1</sup>  
 Stanley L. Barnwell<sup>1,2</sup>  
 Michael S. B. Edwards<sup>2,3</sup>  
 Martin Melicharek<sup>4</sup>

Seven patients with symptomatic aneurysms involving the petrous segment of the internal carotid artery were treated by endovascular techniques (six patients) or surgical ligation (one patient). Patients' ages at the time of treatment ranged from 7 to 62 years (mean, 30 years). The presenting symptoms were pain (seven patients), eighth nerve dysfunction (three patients), seventh nerve dysfunction (one patient), fifth nerve dysfunction (two patients), and bruit (one patient). Two patients, ages 7 and 19, respectively, presented with giant, partially thrombosed petrous aneurysms and had hemiatrophy of the body ipsilateral to the side of the aneurysm. Only one patient had a history of trauma; aneurysms in the remaining patients were presumed to be congenital in origin. In one patient with a saccular aneurysm, a balloon could be navigated into the aneurysm, obliterating it but preserving the parent artery. The remaining six patients had fusiform aneurysms with intraluminal thrombus and underwent proximal occlusion (four patients) or trapping procedure (two patients). In all patients, symptoms were alleviated after thrombosis of the aneurysm. The only complication was a transient visual loss in a hypercoagulable patient, occurring after carotid occlusion.

Petrous carotid aneurysms can produce a wide clinical spectrum of signs and symptoms in younger patients; these aneurysms frequently are fusiform and contain chronic thrombus. They can be treated effectively by endovascular or surgical occlusive procedures.

*AJNR* 11:253-257, March/April 1990

Aneurysms arising in the petrous segment of the internal carotid artery are rare, with only 30 cases reported in the literature. The vast majority of these are case reports [1-24]. Patients with these aneurysms have been reported to present with a wide clinical spectrum of signs and symptoms, including dysfunction of the fifth [6, 13], sixth [3, 7, 9, 22, 23], seventh [4, 9, 22], eighth [1, 4, 7-10, 15, 17-20, 23], ninth [4], 10th [4], and 12th [4] cranial nerves; Horner syndrome [7]; otorrhea [2, 5, 15, 25]; epistaxis [1, 9, 19]; and purulent otorrhea [12]. Reported treatments have included ligation of the internal carotid artery [17, 20] and the common carotid artery [1-3, 6, 16-18], trapping procedures [7, 15], direct operative exposure [4, 11, 12], and, recently, transvascular balloon embolization [21, 24]. We report our experience with the endovascular and surgical treatment of seven patients with this disorder.

## Materials and Methods

Seven patients with symptomatic petrous carotid aneurysms were treated by surgical (one patient) or endovascular (six patients) techniques. Patient data, including age, sex, side on which aneurysm occurred, presenting symptoms, treatment, outcome, complications, and follow-up, are summarized in Table 1. Patients' ages ranged from 7 to 62 years of age, with a mean of 30.3 years. Four patients were younger than 20 at the time of presentation. The presenting symptoms were as follows: pain (seven patients), eighth nerve dysfunction (three patients), fifth nerve dysfunction (two patients), and seventh and third nerve dysfunction (one

Received June 5, 1989; revision requested July 31, 1989; revision received August 29, 1989; accepted August 29, 1989.

<sup>1</sup> Department of Radiology, University of California Hospitals, 505 Parnassus Ave., San Francisco, CA 94143. Address reprint requests to V. V. Halbach.

<sup>2</sup> Department of Neurological Surgery, University of California Hospitals, San Francisco, CA 94143.

<sup>3</sup> Department of Neurological Surgery and Pediatrics, Division of Pediatric Neurosurgery, University of California Hospitals, San Francisco, CA 94143.

<sup>4</sup> Department of Neurological Surgery, Kaiser-Permanente Hospital, Sacramento, CA 95825.

0195-6108/90/1102-0253

© American Society of Neuroradiology



patient each). One patient presented with two episodes of amaurosis fugax as the result of emboli arising from the aneurysm sac (case 2). Only one patient (case 3) had a history of blunt trauma to the neck 7 years prior to presentation. None of the other patients had a history of trauma or head or neck infection. Two patients (cases 1 and 2) had unexplained hemiatrophy of the body ipsilateral to the aneurysm. In addition, case 2 had areas of increased pigmentation on the ipsilateral back, thorax, and extremity. All the patients had arteriography for definitive diagnosis of the lesion. In addition, patients 2–6 had CT scanning with contrast enhancement prior to treatment. Patients 1, 2, 3, and 7 had MR scans before treatment. In all seven patients intraluminal thrombus was identified within the aneurysm (see Figs. 1A and 2A). Case 1 had surgical ligation of the proximal internal carotid artery after successful test occlusion. Patients 2–7 had transvascular balloon embolization procedures. Following trans-femoral arteriography, a 7.5-French sheath was placed in the right femoral artery. Systemic anticoagulation was given with 5000 units of heparin for a 70-kg patient. A 7.0-French Meditech (Cook, Inc., Bloomington, IL) end-hole balloon occlusion catheter was placed in the proximal internal carotid artery and inflated to produce complete occlusion. Careful neurologic monitoring was performed for 30 min. All six patients tolerated carotid occlusion without neurologic deficits. This catheter was removed and exchanged for a 7.3/5.0-French polyethylene catheter system. In case 5, the inner 5-French catheter was removed and a 4/2-French coaxial polyethylene system (Cook Inc., Bloomington, IL) with an attached silicone detachable balloon (Interventional Therapeutics, Oyster Point, CA) was navigated into the aneurysm and solidified with 2-hydroxyethyl methylacrylate. In cases 2, 3, 4, 6, and 7, a second catheter system was placed from a left femoral approach into the proximal internal carotid artery, and two balloons were simultaneously inflated proximal to the aneurysm (cases 2, 6, and 7) or on either side of the aneurysm (cases 3 and 4) and detached. The balloons were inflated with slightly hypertonic metrizamide (Amipaque, Winthrop Laboratories, New York, NY) of a concentration of 200 mg/dl iodine. Control angiograms were obtained at the completion of the procedure following the reversal of the systemic heparin with protamine sulfate (1 mg reverses approximately 100 units of circulating heparin). In addition, plain skull films were obtained in the anteroposterior and lateral projections to document the position, size, and location of the balloons producing aneurysm occlusion. During a period from 1 to 7 months after the procedure,

all seven patients had thin-section CT scans with and without contrast material to document aneurysm thrombosis.

### Representative Case Reports

Case 2 is a 7-year-old boy with congenital left-body hemiatrophy who presented with progressive hearing loss and headaches on the left, and two episodes of amaurosis fugax in the left eye. An MR scan (Fig. 1A), a CT scan, and an angiogram (Fig. 1B) revealed a giant, largely thrombosed, fusiform aneurysm arising from the petrous carotid artery and extending into the cavernous carotid artery. A carotid test occlusion was tolerated and permanent occlusion obtained by placing two balloons proximal to the aneurysm. One week after the procedure the patient had a single 10-min episode of visual loss in the left eye. A work-up included a CT scan and follow-up angiogram (Fig. 1C), which revealed complete thrombosis of the aneurysm and internal carotid artery. A subsequent evaluation revealed a hypercoagulable state due to an increased platelet count ( $>1$  million) and protein C deficiency, which were treated with anti-platelet medication (aspirin and dipyridomide). Follow-up at 27 months revealed no recurrence of symptoms in a neurologically stable child.

Case 3 is a 14-year-old girl with a history of blunt neck trauma at age 7 who presented with complaints of increasingly severe headaches, right-sided pulsatile tinnitus, hearing loss, and vertigo. A physical examination revealed diminished hearing and a right pulsatile red eardrum. An MR scan (Fig. 2A), a CT scan, and an angiogram (Fig. 2B) revealed a partially thrombosed right petrous carotid aneurysm. A test occlusion of the right internal carotid artery was tolerated. One balloon was positioned proximal to the aneurysm and a second balloon distal to the aneurysm (Fig. 2C). The patient's presenting symptoms completely resolved, and follow-up MR scans at 6 months and 2 years confirmed thrombosis of the aneurysm.

Case 5 is a 62-year-old woman with severe left-sided headaches and fifth nerve hypersensitivity. An angiogram (Fig. 3A) and a CT scan revealed a partially thrombosed petrous carotid aneurysm with a well-defined neck. A balloon was navigated into the dome of the aneurysm (Fig. 3B) and detached. A control angiogram (Fig. 3C) and CT scan at 4 months confirmed thrombosis of the aneurysm dome; the patient subsequently has had complete resolution of her symptoms.

**TABLE 1: Summary of Seven Patients with Symptomatic Petrous Carotid Aneurysms**

Case No.	Age	Sex	Side	Presenting Symptoms	Treatment	Outcome	Complications	Follow-up
1	19	M	L	5th and 7th nerve palsy, bruit	ICA ligation	Cure	None	16 mo
2	7	M	L	HA, 8th nerve dysfunction, amaurosis fugax	Balloon ICA occlusion	Cure	One episode of amaurosis fugax	23 mo
3	14	F	R	HA, 8th nerve dysfunction	Balloon trapping ICA	Cure	None	8 mo
4	31	F	L	HA, 8th nerve dysfunction	Balloon trapping ICA occlusion	Cure	None	16 mo
5	62	F	L	HA, 5th nerve dysfunction	Balloon occlusion of aneurysm	Cure	None	24 mo
6	60	F	L	HA	Balloon ICA occlusion	Cure	None	24 mo
7	19	M	R	HA, 3rd nerve dysfunction	Balloon ICA occlusion	Cure	None	1 mo

Note.—L = left, R = right, ICA = internal carotid artery, HA = headache.



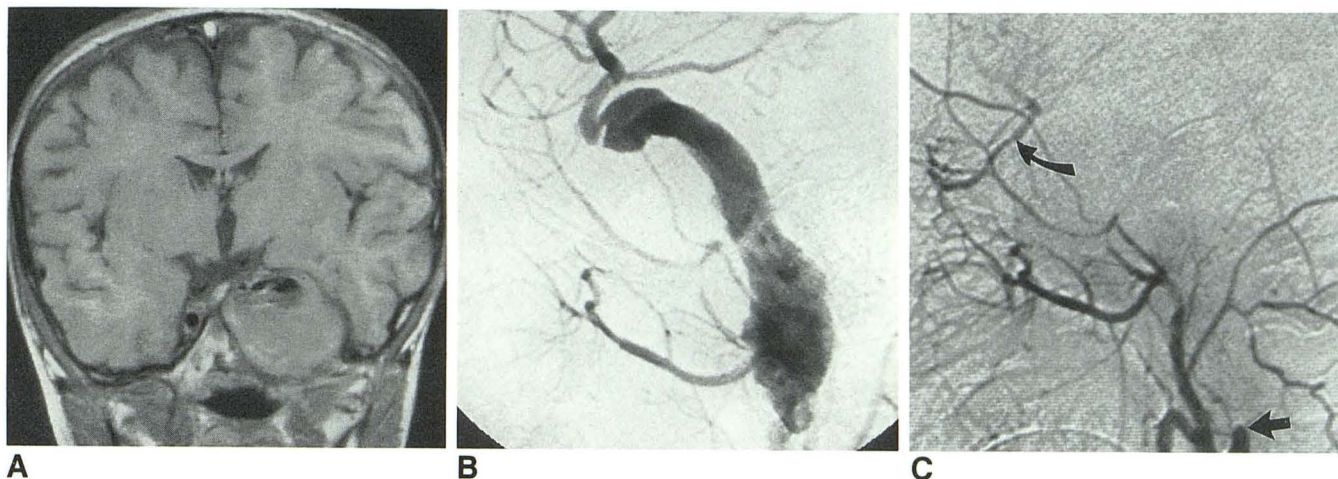


Fig. 1.—Case 2: 7-year-old boy with decreased hearing on the left and two episodes of amaurosis fugax 2 months prior to treatment.  
 A, Coronal T1-weighted image (800/20) shows mass eroding skull base, displacing pituitary gland to the right. An area of signal void is located superiorly, suggestive of flow phenomena.  
 B, Left common carotid injection, lateral projection, demonstrates a fusiform aneurysm arising in petrous segment and extending into cavernous internal carotid artery. The patent lumen corresponds to only a fraction of the overall size of the aneurysm as imaged on CT and MR scans.  
 C, Left common carotid angiogram, lateral view, at 2-month follow-up, shows occlusion of internal carotid artery (straight arrow) and aneurysm. External carotid collaterals fill ophthalmic artery retrograde to supraclinoid carotid artery (curved arrow).

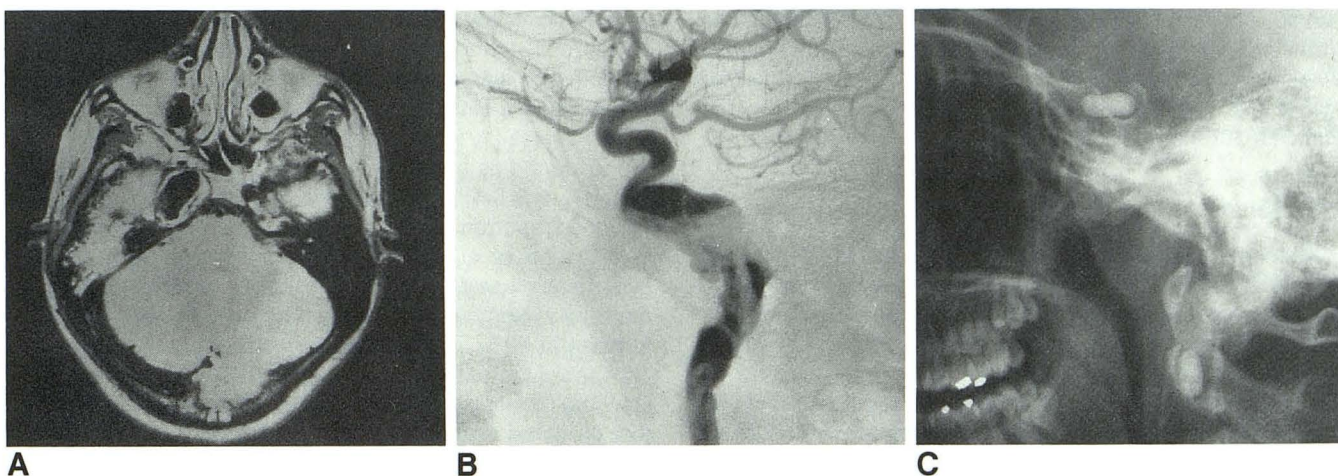


Fig. 2.—Case 3: 14-year-old girl with severe unilateral headaches presented with pulsatile mass behind right eardrum.  
 A, Axial T1-weighted image (800/30) shows expansile lesion involving right petrous bone with flow void.  
 B, Right internal carotid angiogram, lateral projection, demonstrates an irregular petrous aneurysm partially filled with intraluminal thrombus.  
 C, Plain film shows two silicone balloons located in ascending cervical carotid and horizontal cavernous carotid, producing occlusion of the aneurysm.

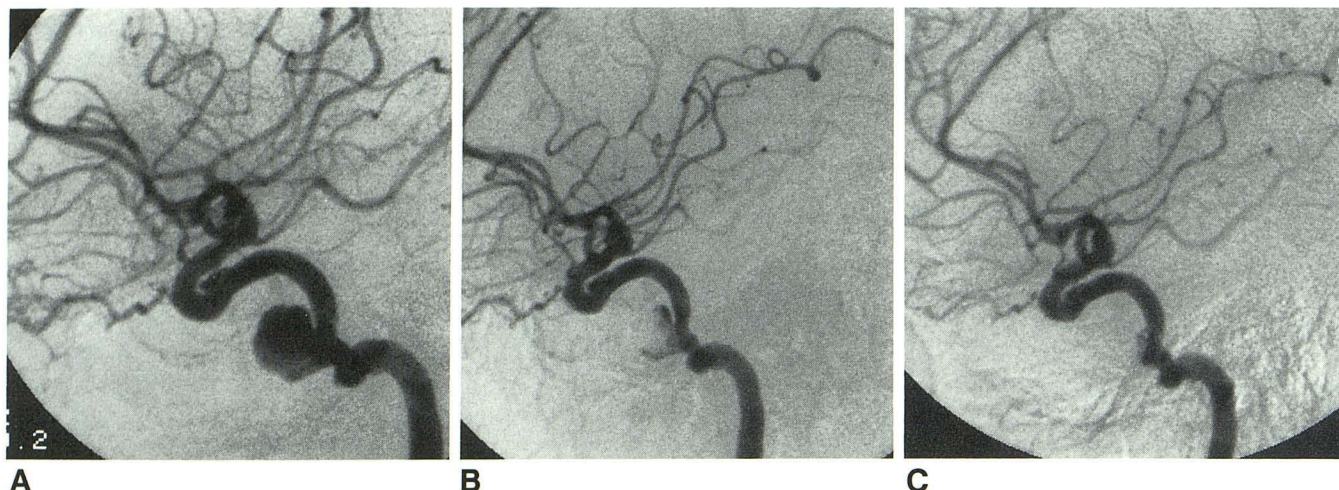
## Results

In all seven patients, complete aneurysm thrombosis was documented on posttreatment CT scans. All seven patients had complete resolution of their presenting symptoms except for a persistent seventh nerve palsy in case 1. Cases 2–7 had complete neurologic examinations at 2-month intervals until complete resolution of symptoms was documented, then at 8-month intervals. Case 1 was followed for 6 months with improvements in all symptoms except for an unchanged facial nerve palsy. He was subsequently lost to follow-up. The follow-up period ranged from 4 to 27 months, with a mean of 19 months. In case 1, surgical ligation proximal to the aneu-

rysm resulted in aneurysm thrombosis. Balloon trapping procedures (cases 3 and 4) and proximal ligations with two detachable balloons (cases 2, 6, and 7) resulted in complete aneurysm thrombosis. In case 5, the balloon was navigated into the aneurysm with a well-defined neck and detached, which produced obliteration of the aneurysm with preservation of the carotid arterial flow (Fig. 3).

The only complication occurred in case 2, a 7-year-old boy who presented with amaurosis fugax and underwent an uneventful occlusion of the petrous and cavernous aneurysm by means of two balloons placed proximal to the aneurysm. One week after the procedure the patient had one episode of transient visual loss lasting 10 min, which completely re-





**Fig. 3.**—Case 5: 62-year-old woman presented with severe pain related to fifth nerve ganglion.  
**A,** Left internal carotid angiogram, lateral projection, demonstrates an aneurysm arising from petrous cavernous junction of the internal carotid artery. Irregularity of walls suggests intraluminal thrombus.  
**B,** Placement of a silicone balloon within aneurysm immediately after embolization shows some residual filling of the aneurysm.  
**C,** 1-week follow-up angiogram demonstrates thrombosis of the dome of the aneurysm and a small remaining neck remnant.

solved. Additional work-up revealed a hypercoagulable state (protein C deficiency and increased platelet count). The patient was treated with aspirin (325 mg/day) and has had no further symptoms. A follow-up CT scan and arteriogram revealed complete thrombosis of the aneurysm.

## Discussion

Aneurysms involving the petrous segment of the internal carotid artery are rare, with only 30 cases reported in the literature. None were reported in a cooperative study of over 3000 aneurysms [26]. The cause of these rare aneurysms is unknown: some authors have suggested a traumatic [2, 3, 9, 13, 14], mycotic [2, 5, 12], or inflammatory (petrositis) origin. Pathology in two reported cases [4, 5] has shown degeneration of the internal elastic membrane and media aplasia, which is similar to the histological changes seen with intracranial berry aneurysms. The mean age of onset of symptoms in the reported cases and in our series is younger than for aneurysms in other locations. Both multiple [26] and bilateral aneurysms [19] in the petrous carotid have been reported. It is interesting to note that two patients in our series had hemiatrophy ipsilateral to the side of their aneurysm. Although hemihypertrophy [22], cerebral hemisphere hemiatrophy with a hypoplastic internal carotid [27], and facial hemangiomas [28] have been reported in association with intracranial aneurysms, we could not find any previously reported associations between hemiatrophy and the development of ipsilateral intracranial aneurysm. The infrequency of these two diseases made their occurrence more than coincidental.

A variety of presenting symptoms have been reported in patients with petrous aneurysms, depending on the direction of expansion. Eighth cranial nerve dysfunction is the most common symptom, found in 43% of patients [7–10, 15, 17–20, 23], followed by sixth nerve palsy (23%) [3, 7, 9, 22, 23],

seventh nerve paresis (20%) [4, 9, 22], fifth nerve dysfunction (17%) [6, 13], and lower cranial nerve involvement (3%) [4]. Hemorrhage was a presenting symptom in 27% of reported cases, equally distributed between otorrhagia [2, 5, 15, 25] and epistaxis [1, 9, 19]. Epistaxis, sometimes massive [18, 19], occurred as a result of rupture of the aneurysm into the middle ear [4] with drainage via the eustachian tube. Bruit has been reported in only 10% of patients [21] and was noted in only one of our patients. In our series, the presenting symptoms closely correlated with those reported in the literature, with eighth nerve involvement in 43%, fifth nerve dysfunction in 29%, and third or seventh nerve involvement in 14%. All of the patients in our series had (1) a history of long-standing unilateral headaches (often attributed to migraines) that predated discovery of their aneurysm by several years, and (2) intraluminal thrombus within the aneurysm; however, only one patient (case 2) had evidence of a thromboembolic event, probably aggravated by an underlying hypercoagulable state. Most of the aneurysms in our series as well as those reported in the literature were giant and fusiform. Interestingly, despite the proximity of the surrounding sympathetic fibers coursing toward the superior orbital fissure to supply the eye [3], only one case of Horner syndrome has been reported [7]. Several deaths have been reported [4, 5, 9] following direct open biopsy of an aneurysm as a result of an otologic surgeon confusing the pulsating mass for a glomus tumor.

The location of petrous aneurysms makes direct neurosurgical approaches unsuitable, and the majority of reported cases have been managed by carotid ligation procedures. Most of the patients reported in the literature and the one patient (case 1) in our series have done well with surgical ligation of the cervical internal carotid artery. Anderson et al. [15], however, reported two patients who had persistent symptoms after this procedure and required trapping procedures to produce aneurysm occlusion. A possible explanation



is that following proximal occlusion, there is reversal of flow down the distal internal carotid to supply the caroticotympanic, vidian, and periosteal branches above the ligation, which keep the aneurysm patent. Endovascular occlusion of the internal carotid artery is an alternative with considerable merit, as it allows occlusion of the aneurysm at a point proximal to, or on either side of, the aneurysm, and, as well, allows the evaluation of the patient's tolerance to carotid occlusion. Fox et al. [29] reported a series of 37 aneurysms arising below the ophthalmic artery treated by proximal balloon occlusion of the carotid artery with a low permanent morbidity. Balloon trapping procedures have been reported [21] to have a decreased incidence of thromboembolic complications as compared with proximal balloon or surgical occlusion. The risk of dislodging a clot while traversing a partially thrombosed aneurysm with a detachable balloon must be weighed against this potential benefit. The single delayed embolic episode in our series occurred in a patient who had undergone an occlusion just proximal to the aneurysm, and had an underlying hypercoagulable state. This patient was treated effectively with antiplatelet medications. In our experience with over 100 cases of balloon carotid occlusion, delayed embolic events are very unusual. Since the desired goal is aneurysm thrombosis, we do not routinely use antiplatelet medications after carotid occlusion unless embolic symptoms occur.

The most desirable goal would be occlusion of the aneurysm with preservation of the parent carotid artery, which was accomplished in case 5 and reported in one other case [24]. Unfortunately, the majority of petrous aneurysms are fusiform in shape, and parent artery preservation is therefore impossible.

All of our patients had improvement of their symptoms associated with the aneurysms. The presenting symptoms of bruit resolved immediately after carotid occlusion (case 1). The remaining symptoms of cranial nerve dysfunctions resolved slowly over several months. Headaches were the last symptom to resolve, persisting up to 4 months in case 4. The severe unilateral retroorbital headaches that occurred as a result of aneurysm thrombosis usually improved to baseline levels within several weeks.

In conclusion, petrous aneurysms tend to occur in younger patients, and often present with external hemorrhage or eighth nerve dysfunction. They are most often large and fusiform, contain intraluminal clot, and can be most effectively treated by endovascular techniques.

## REFERENCES

- Pierini EA, Agra A. Epistaxis como signo de hemorragia de la carotida interna en su porcion timpanica. *Presna Med Argent* 1954;41:945-948
- Barrett JH, Lawrence VL. Aneurysm of the internal carotid artery as a complication of mastoidectomy. *Arch Otolaryngol* 1960;72:366-368
- Pecker J, Hoel J, Javalet A, et al. Paralysie du moteur oculaire externe par aneurysme intra-petreux traumatique de la carotide interne. *La Presse Medicale* 1960;1023-1026
- Guirguis S, Tadros FW. An internal carotid aneurysm in the petrous temporal bone. *J Neurol Neurosurg Psychiatry* 1961;24:84-85
- Hiranandani LH, Chandra O, Malpani N, et al. An internal carotid aneurysm in the petrous temporal bone. *J Laryngol Otol* 1962;76:703-706
- Harrison TH, Odom GL, Kunkle EC. Internal carotid aneurysm arising in the carotid canal. *Arch Neurol* 1963;8:112-115
- Wemple JB, Smith GW. Extracranial carotid aneurysm. *J Neurosurg* 1966;24:667-671
- Allen GW. Angiography in otolaryngology. *Laryngoscope* 1967;77:1909-1961
- Busby DR, Slemmons DH, Miller TF. Fatal epistaxis via carotid aneurysm and eustachian tube. *Arch Otolaryngol* 1968;87:293-296
- Steffen TN. Vascular anomalies of the middle ear. *Laryngoscope* 1968;78:171-197
- Conley J, Hildyard V. Aneurysm of the internal carotid artery presenting in the middle ear. *Arch Otolaryngol* 1969;90:61-64
- Stallings JO, McCabe BF. Congenital middle ear aneurysm of the internal carotid. *Arch Otolaryngol* 1969;90:65-69
- Dinakar I, Rao B. Aneurysm of the internal carotid artery in the carotid canal. *Indian J Radiol* 1971;25:134-135
- Teal JS, Bergeron RT, Rumbaugh CL, et al. Aneurysms of the petrous or cavernous portions of the internal carotid artery associated with nonpenetrating head trauma. *J Neurosurg* 1973;38:568-574
- Anderson RD, Liebeskind A, Schechter M, et al. Aneurysms of the internal carotid artery in the carotid canal of the petrous temporal bone. *Radiology* 1972;102:639-642
- Reddy DR, Rao G, Carla JM, et al. Carotid canal and cavernous sinus aneurysms. *J Postgrad Med* 1973;19:188-189
- Morantz RA, Kirchner F, Kishure P. Aneurysm of the petrous portion of the internal carotid artery. *Surg Neurol* 1976;6:313-318
- Holtzman RN, Parisier SC. Acute spontaneous otorrhagia resulting from a ruptured petrous carotid aneurysm. *J Neurosurg* 1979;51:258-261
- Mofet DA, O'Conner AFF. Bilateral internal carotid aneurysms in the petrous temporal bones. *Arch Otolaryngol* 1980;106:172-175
- Kudo S, Colley DP. Multiple intrapetrous aneurysms of the internal carotid artery. *AJNR* 1983;4:1119-1121
- Berenstein A, Ransohoff J, Kupersmith M, Flamm E, Graeb D. Transvascular treatment of giant aneurysms of the cavernous carotid and vertebral arteries. Functional investigation and embolization. *Surg Neurol* 1984;21:3-12
- Fisher EG, Strand RD, Shapiro F. Congenital hemihypertrophy and abnormalities of the cerebral vasculature. Report of two cases. *J Neurosurg* 1984;61:163-168
- Kelly WM, Harsh GR IV. CT of petrous carotid aneurysms. *AJNR* 1985;6:830-832
- Willinsky R, Lasjaunias P, Pruvost P, Boucherat M. Petrous internal carotid aneurysm causing epistaxis: balloon embolization with preservation of the parent vessel. *Neuroradiology* 1987;29:570-572
- Chiappetta F, Vangelista S, Pirrone R. Recurrent massive otorrhagia caused by a petrous carotid aneurysm. *J Neurosurg Sci* 1982;26:205-207
- Sahs AA, Perret GE, Locksley HB, et al. *Intracranial aneurysms and subarachnoid hemorrhage: a cooperative study*. Philadelphia: Lippincott, 1969:296
- Afifi AK, Godersky JC, Menezes A, Smoker WR, Bell WE, Jacoby CG. Cerebral hemiatrophy, hypoplasia of internal carotid artery, and intracranial aneurysm. A rare association occurring in an infant. *Arch Neurol* 1987;44:232-235
- Mizuno Y, Kurokawa T, Numaguchi Y, Goya N. Facial hemangioma with cerebrovascular anomalies and cerebellar hypoplasia. *Brain Dev* 1982;4:375-378
- Fox AJ, Vinuela F, Pelz PM, et al. Use of detachable balloons for proximal artery occlusion in the treatment of unclippable cerebral aneurysms. *J Neurosurg* 1987;66:40-46