

Generic Contrast Agents

Our portfolio is growing to serve you better. Now you have a *choice*.



FRESENIUS
KABI

[VIEW CATALOG](#)

AJNR

Cervical epidural hematomas: CT diagnosis in two cases that resolved spontaneously.

J P Laissy, P Milon, P Freger, N Hattab, P Creissard and J Thiebot

AJNR Am J Neuroradiol 1990, 11 (2) 394-396

<http://www.ajnr.org/content/11/2/394.citation>

This information is current as
of May 10, 2025.

Cervical Epidural Hematomas: CT Diagnosis in Two Cases That Resolved Spontaneously

Jean-Pierre Laissy,¹ Patrick Milon,¹ Pierre Freger,² Nejib Hattab,² Pierre Creissard,² and Jacques Thiebot¹

Cervical epidural hematomas are rare entities [1–6] that can develop from such causes as trauma, arteriovenous malformations, coagulation disturbances, pregnancy, and neoplasms. In most cases, however, they occur spontaneously or without evident cause.

As vital and neurologic prognoses are unpredictable upon admission, these hematomas are considered to be neurosurgical emergencies by most authors [1, 2, 4, 5, 7, 8].

We describe two cases of cervical epidural hematomas that resolved without any complication or sequelae under medical therapy and CT follow-up.

Case Reports

Case 1

A 55-year-old man experienced an acute onset of severe pain in the scapula, followed by dizziness. Salicylates were unsuccessful in relieving the pain. He had a history of myocardial infarction 4 years earlier for which he was taking Coumadine.

On clinical examination, the patient had thermohypesthesia in the left lower extremity and trunk, right hemiplegia that was rapidly improving, and bladder dysfunction.

Initial cervical plain CT disclosed a regular biconvex high-density lesion corresponding to a small amount of blood in the epidural space at the level of C4 and C5, with shifting of the subarachnoid spaces and spinal cord toward the left (Fig. 1A).

Since symptomatology decreased rapidly, surgery was not performed. A cervical CT scan obtained 1 week later showed that the hematoma had disappeared (Fig. 1B).

Case 2

A 38-year-old man had a sudden onset of cervical and dorsal pain, 6 hr after a thoracic trauma with another player during a game of football. Simultaneously, he complained of weakness in both lower limbs, bladder dysfunction, and clumsiness of the left upper extremity.

Clinical examination demonstrated hyperreflexia of the lower extremities without deficit, bilateral foot clonus, muscle weakness in the C7 dermatome, and no sensory disturbance.

Cervical CT exhibited a left-sided epidural mass extending from the body of C6 to the lower margin of D1, with a slight displacement of the spinal cord and dura to the right (Fig. 2A), best appreciated on sagittal and oblique reformatted images from 2D reconstruction (Fig. 2B).

A spontaneous and rapid improvement of neurologic status obviated surgery. A CT scan obtained 1 week later was normal, and clinical follow-up after the patient was discharged from the hospital revealed no residual neurologic signs.

Discussion

In most published reports, acute cervical epidural hematoma is regarded as a neurosurgical emergency, as are epidural hematomas located elsewhere. The progression of such a lesion without treatment threatens neurologic prognosis and is often fatal [1–9].

Patients with cervical epidural hematomas usually present with acute cervical and/or interscapular pain, radicular pain in the upper extremities, and radicular deficits. Lower extremity involvement can also occur with spinal cord compression.

Received April 11, 1989; revision requested May 24, 1989; revision received June 22, 1989; accepted July 17, 1989.

¹ Department of Neuroradiology, Hôpital Charles Nicolle, 76031 Rouen Cédex, France.

² Department of Neurosurgery, Hôpital Charles Nicolle, 76031 Rouen Cédex, France.

Fig. 1.—A and B, The spontaneous epidural (right) hyperdensity (A) has virtually disappeared 1 week later (B).

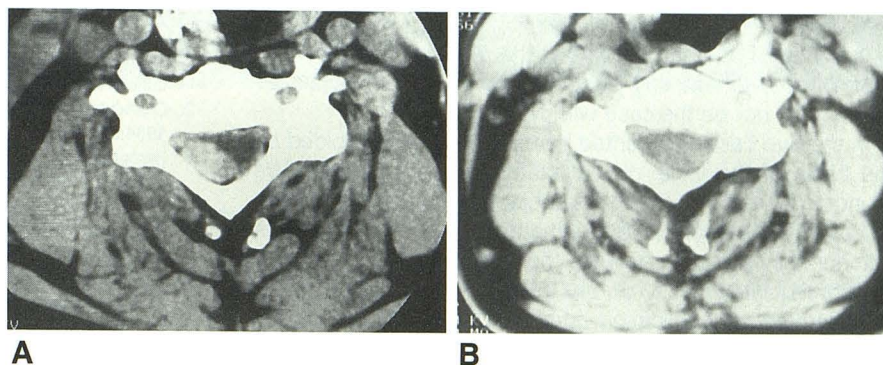



Fig. 2.—In this patient, CT was initially performed before (not shown) and after contrast material injection.

A, Thin rim of enhancement at internal border of hematoma (inset) is consistent with epidural vascular opacification, somewhat similar to the enhancement of the anterior venous plexuses in disk herniation.

B, Frontal oblique 2D reformatted image depicts the volume and craniocaudal extension of this epidural hematoma (arrows).



The most frequent level of involvement is the lower cervical segment (C6 and/or C7). The longitudinal extent reaches three to four vertebrae in more than 50% of patients [1]. Lower locations (i.e., thoracic and lumbar segments) [3, 9] are unusually affected alone, and often correspond to a caudad extension of the cervical involvement.

In some cases, spinal epidural hematoma can be related to a predisposing factor, such as spinal trauma; anticoagulant therapy; and hemorrhagic diatheses such as hemophilia, arteriovenous malformations, and spinal cord neoplasms; collagen vascular disorders, including systemic lupus erythematosus; and to an iatrogenic origin, such as peridural anesthesia. In about 50% of cases, however, these hematomas occur spontaneously, without demonstrable underlying morbidity or association with arterial hypertension or pregnancy.

Although the source of the hemorrhage is usually not found [2, 4], several mechanisms have been described. The first one, assumed on the basis of recent experimental studies, results from a mechanical arterial disruption of "longitudinal channels" [1]. These are anastomotic arterial branches between epidural arteries, which run along cervical nerve roots and the meningeal sheath inside the spinal canal. They are in part free in the epidural space between mobile nerve roots and meninges, so that they represent a vulnerable area. As the cervical level involved is more often the lower cervical spine, it has been assumed that the corresponding nerves during motion had a greater excursion than the upper cervical nerves. Any excessive stretching of nerves can theoretically provoke epidural bleeding, which is often found posterolat-

erally on CT and at surgery [1]. However, one can argue against this hypothesis, because epidural hematoma is never associated with radicular avulsion.

The second proposed mechanism advocates venous bleeding as the cause [1]. Spinal epidural veins are less well protected than intracranial ones. They form an important network in the epidural space, which is itself composed of loose, fatty tissue. All changes in central venous pressure (i.e., intrathoracic or intraabdominal) involve epidural venous plexuses, which can be partially disrupted. Blood accumulation is usually more pronounced posteriorly because the epidural space is larger than anteriorly.

This hypothesis can account for the mechanism of trauma in our case 2, and for the spontaneous improvement seen clinically and on CT in both patients. It disagrees with the generally known fact that, regardless of position and degree of relaxation, the pressure in the epidural veins is less than the intrathecal pressure at the same spinal level.

All the more recent papers agree on the usefulness of CT in early recognition of this condition [1, 2, 4, 7, 9]. Plain CT assesses the presence of recent hematoma because of its high density, its location, and its size.

Thin slices (5-mm-thick sections or less) are recommended, and sagittal reconstructions can be useful to better appreciate the longitudinal extent of the lesion. In our experience, thin overlapped images (4-mm incremental slices) are necessary for obtaining high-resolution 2D reformatted images.

It is worth saying that the spontaneous resolution shown on CT would happen normally even though the hematoma

may still be there, because it loses its density on CT in about a week, or a little longer. Thus, the important thing is the clinical improvement, and the CT resolution is really incidental. That would not be the case with MR imaging.

In the two cases presented here, surgery was avoided on the basis of the initial clinical status and progression. We found no CT data on the same subject that determine criteria of severity. The size of the hematoma on CT is perhaps a criterion, since in both patients the length was less than two vertebral bodies.

We found no publication comparing MR with CT in the evaluation of intraspinal hematomas. Indeed, plain CT is sufficient to explore these hematomas, but MR promises to be very useful. However, it is not always possible to perform MR in an emergency. So CT remains at this time the first examination to do, both for initial screening and follow-up, the latter being imperative if surgery is not performed.

REFERENCES

1. Beatty RM, Winston KR. Spontaneous cervical epidural hematoma. A consideration of etiology. *J Neurosurg* **1984**;61:143-148
2. Costabile G, Husag L, Probst C. Spinal epidural hematoma. *Surg Neurol* **1984**;21:489-492
3. Hernandez D, Vinuela F, Freasby TE. Recurrent paraplegia with total recovery from spontaneous spinal epidural hematoma. *Ann Neurol* **1982**;11:623-624
4. Matsumae M, Shimoda M, Shibuya N, Ueda M, Yamamoto I, Sato O. Spontaneous cervical epidural hematoma. *Surg Neurol* **1987**;28:381-384
5. Solymosi L, Wappenschmidt J. A new neuroradiologic method for therapy of spinal epidural hematomas. *Neuroradiology* **1985**;27:67-69
6. Freger P, Meneses M, Creissard P, Vanier JP, Tadie M, Godlewski J. Epidural haematoma in hemophilia. *Neurochirurgie* **1986**;32:486-489
7. Post MJD, Seminer DS, Quencer RM. CT diagnosis of spinal epidural hematoma. *AJNR* **1982**;3:190-192
8. Kirkpatrick D, Goodman SJ. Combined subarachnoid and subdural hematoma following lumbar puncture. *Surg Neurol* **1975**;3:109-111
9. Levitan LH, Wiens CW. Chronic lumbar extradural hematoma: CT findings. *Radiology* **1983**;148:707-708