

Generic Contrast Agents

Our portfolio is growing to serve you better. Now you have a *choice*.



FRESENIUS
KABI

[VIEW CATALOG](#)

AJNR

Gd-DTPA enhancement in CNS extramedullary hematopoiesis.

P C Buetow, J J Perry and C A Geyer

AJNR Am J Neuroradiol 1990, 11 (2) 411-412

<http://www.ajnr.org/content/11/2/411.citation>

This information is current as
of May 12, 2025.

Gd-DTPA Enhancement in CNS Extramedullary Hematopoiesis

Extramedullary hematopoiesis involving the meninges is an uncommon sequela in patients with myelofibrosis. Its dramatic regression after radiation therapy, however, makes it an important and treatable entity. We describe the exquisite Gd-DTPA enhancement of the meninges in the brain and spinal canal of a patient with extramedullary hematopoiesis and the expected course after irradiation.

Case Report

Polycythemia vera was diagnosed in a 53-year-old woman who had erythrocytosis, thrombocytosis, and splenomegaly. The patient was treated with phlebotomies for 8 years and then with alkylating agents, and finally splenectomy was performed 14 years after diagnosis because of progressive splenomegaly and refractory thrombocytopenia. Two years later, she had atypical headache for several months, and physical examination showed unsteady gait and mild left ptosis. Histologic examination of a specimen obtained by bone marrow biopsy revealed extensive myelofibrosis with less than 5% myeloblasts. MR with Gd-DTPA showed enhancement of the meninges and focal deposits (Figs. 1A and 1B). The extent of disease was not well appreciated on unenhanced MR and was less evident on contrast-enhanced CT. Antimony-sulfur colloid-^{99m}Tc scintigraphy confirmed the reticuloendothelial nature of the deposits, obviating an invasive biopsy procedure. The diagnosis was meningeal myeloid metaplasia from myelofibrosis caused by polycythemia vera. The patient was treated with low-dose external-beam radiation to the cranium and spine (750 cGy over 5 weeks), which caused complete and stable regression of signs and symptoms. Gd-DTPA-enhanced MR performed after treatment showed subtotal regression of the meningeal deposits (Figs. 1C and 1D). To date, none of the neurologic signs and symptoms have recurred.

Discussion

Many studies have reported the increased ability of Gd-DTPA-enhanced MR in the evaluation of CNS disease [1]. Although enhancing extraaxial masses on CT in patients with myelofibrosis and meningeal myeloid metaplasia have been reported [2-10], as well as complimentary use of radionuclide scanning [8], our case illustrates

the remarkable ability of this technique in the detection of extramedullary deposits. Its adjunctive use with radionuclide scanning obviated a biopsy in a thrombocytopenic patient.

Extramedullary hematopoiesis commonly is encountered in patients with myelofibrosis, which occurs in about 25% of patients who have polycythemia vera. As the bone marrow cavities are crowded by fibrous tissue, other sites are recruited for hematopoiesis, usually the spleen, lymph nodes, and liver [9]. Clinically, the CNS rarely is involved, yet the meninges is a site of hematopoiesis during early ontogeny [10]. Splenectomy and chemotherapy often precede and may predispose to meningeal extramedullary hematopoiesis. In an autopsy study [3], meningeal involvement was found incidentally in three of 11 patients with myelofibrosis, suggesting that this is more common than clinically recognized. Whether this will be detected with similar frequency by Gd-DTPA-enhanced MR remains to be determined.

The enhancement of the extramedullary regions in our case was greater than any enhancement seen in normal medullary spaces and far greater than that seen in this patient's abnormal, fibrous medullary cavity. Extramedullary deposits are made up of pure hematopoietic tissue; they are markedly cellular and have thin-walled arteries that open into large sinuses, similar to those seen in normal bone marrow. No blood-brain barrier exits, and no intervening bony trabeculae are present to decrease the average MR signal per voxel. It is, therefore, the lack of low-signal components and the presence of such vascularity that account for the exquisite enhancement of these extramedullary hematopoietic deposits.

Radiation therapy was highly effective in reversing all signs and symptoms and in causing partial regression of the meningeal deposits. It is important to recognize this life-threatening complication of extramedullary hematopoiesis and its extent because of the dramatic improvement that occurs after irradiation. This should be a prominent consideration in patients with myelofibrosis who have neurologic signs or symptoms. Gd-DTPA-enhanced MR allows prompt detection and assessment of this extramedullary hematopoiesis.

Peter C. Buetow

J. J. Perry

C. A. Geyer

Walter Reed Army Medical Center
Washington, DC 20307-5001

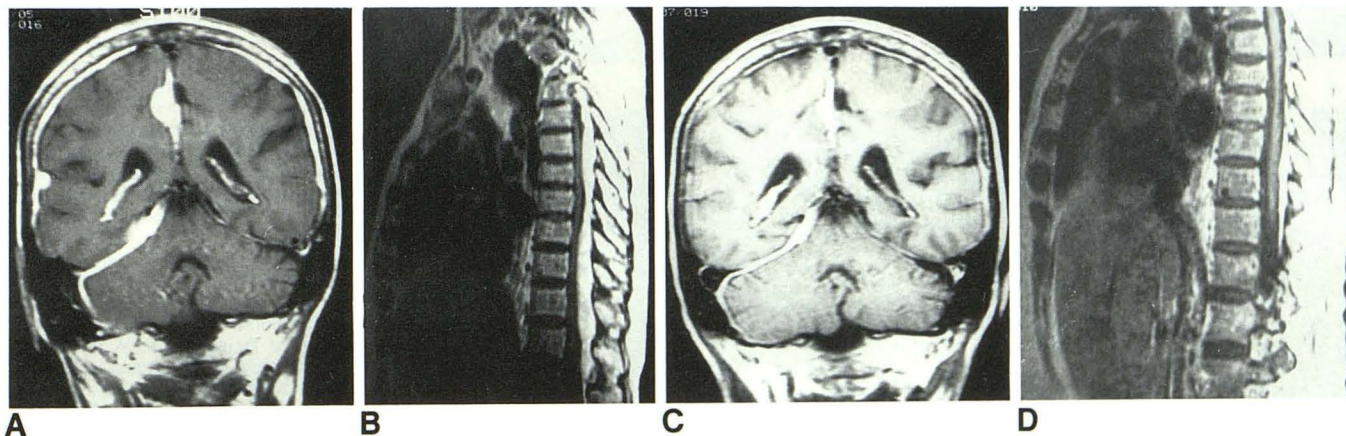


Fig. 1.—Gd-DTPA-enhanced MR images in CNS extramedullary hematopoiesis.

A and B, Coronal image through tentorium and brainstem (A) and sagittal image through spine (B) show enhancement of meninges and focal deposits. C and D, Coronal (C) and sagittal (D) images obtained after radiation therapy show decrease in size of deposits.

Note.—The opinions herein are the authors' and should not be construed as those of the Department of the Army or the Department of Defense.

REFERENCES

1. Sze G, Abramson A, Krol G, et al. Extramedullary spinal disease. *AJR* **1988**;150:911-921
2. Landolfi R, Colosimo C, DeCandia E, et al. Meningeal hematopoiesis causing exophthalmus and hemiparesis in myelofibrosis: effects of radiotherapy. *Cancer* **1988**;62:2346-2349
3. Ligumski M, Polliack A, Benbasset J. Myeloid metaplasia of the central nervous system in patients with myelofibrosis and agnogenic myeloid metaplasia: report of 3 cases and review of the literature. *Am J Med Sci* **1979**;275:99-103
4. Lundh H, Lennart B, Cronqvist S, Eyrich R. Intracranial myeloid metaplasia. *Scand J Haematol* **1982**;28:91-94
5. Brown JA, Gomez-Leon G. Subdural hemorrhage secondary to extramedullary hematopoiesis in postpolycythemic myeloid metaplasia. *Neurosurgery* **1984**;14:588-591
6. Avrahani E, Yust Y, Cohn DF. Falx myeloid metaplasia in myelofibrosis: a CT demonstration. *Neuroradiology* **1981**;21:165-166
7. Lund RE, Aldridge NH. Computed tomography of intracranial extramedullary hematopoiesis. *J Comput Assist Tomogr* **1984**;8:788-790
8. Cornfield DB, Shipkin P, Alavi A, Backer J, Peyster R. Intracranial myeloid metaplasia: diagnosis by CT and Fe52 scans and treatment by cranial irradiation. *Am J Hematol* **1983**;15:273-278
9. Shaver RW, Clore FC. Extramedullary hematopoiesis in myeloid metaplasia. *AJR* **1981**;127:874-876
10. Ward HP, Block MH. The natural history of agnogenic myeloid metaplasia (AMM) and a critical evaluation of its relationship with the myeloproliferative syndrome. *Medicine* **1971**;50:357-420