

# Generic Contrast Agents

Our portfolio is growing to serve you better. Now you have a *choice*.



FRESENIUS  
KABI

[VIEW CATALOG](#)

# AJNR

## **Balloon occlusion of the carotid artery prior to surgery for neck tumors.**

C F Gonzalez and J Moret

*AJNR Am J Neuroradiol* 1990, 11 (4) 649-652

<http://www.ajnr.org/content/11/4/649>

This information is current as  
of May 13, 2025.

# Balloon Occlusion of the Carotid Artery Prior to Surgery for Neck Tumors

Carlos F. Gonzalez<sup>1</sup>  
Jacques Moret<sup>2</sup>

We present the results of presurgical balloon occlusion of the carotid artery in 22 patients with cervical lymphadenopathy stage N3. The procedure was found to be extremely useful in preventing rupture of the carotid artery, considered the most dangerous complication of neck cancer surgery. Complications of the balloon procedure were few (10%) when compared with surgical ligation of the carotid artery (41–54% stroke frequency and 32–60% mortality). This procedure also allows testing of the collateral circulation before final detachment of the balloon, a maneuver that prevents stroke in many patients.

*AJNR* 11:649–652, July/August 1990

Carotid artery rupture is the most dangerous complication in the surgical treatment of patients with cervical lymphadenopathy stage N3 cervical metastasis. The direct invasion of the carotid artery by the neoplastic disease is the most frequent cause of arterial rupture. Other factors that can contribute to carotid arterial rupture include preoperative irradiation, infection, necrosis, and exposure of the vessel during surgery. The end result of carotid rupture is usually severe stroke and, in many cases, death.

Patients with threatening carotid rupture have been traditionally treated by surgical ligation of the involved carotid artery. This procedure is both difficult and risky, particularly when performed on an emergency basis. Endovascular balloon occlusion of the artery with detachable balloons offers an excellent alternative in the prevention of surgical complications or spontaneous rupture of the artery [1]. The procedure is simple to perform, low in risk, and allows testing of the collateral circulation to the affected hemisphere of the brain. This can be done by temporarily occluding the carotid artery before finally detaching the occluding balloon.

Our results with presurgical balloon occlusion of the carotid artery in 22 patients with cervical lymphadenopathy stage N3 demonstrate the efficiency and safety of this procedure.

Received May 22, 1989; revision requested July 26, 1989; revision received February 21, 1990; accepted March 5, 1990.

Presented at the annual meeting of the American Society of Neuroradiology, Orlando, March 1989.

<sup>1</sup> Department of Radiology, Thomas Jefferson University Hospital, Suite 1009, Main Building, 10th and Sansom Sts., Philadelphia, PA 19107. Address reprint requests to C. F. Gonzalez.

<sup>2</sup> Fondation Adolphe de Rothschild, 25 A29 Rue Manin, 75940 Paris, Cedex 19, France.

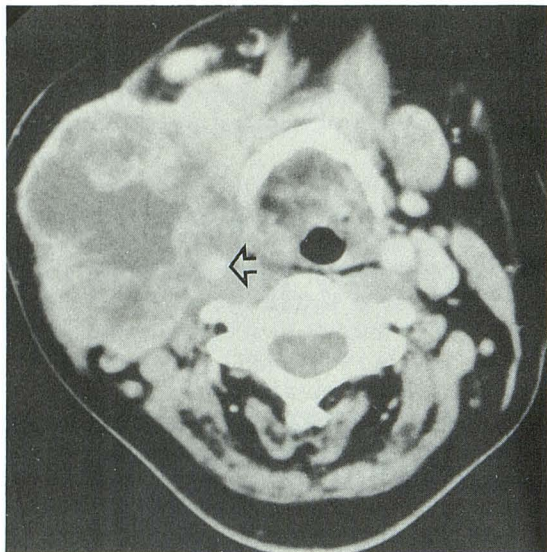
0195–6108/90/1104–0649

© American Society of Neuroradiology

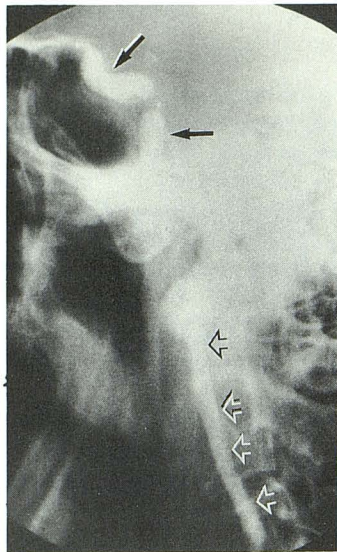
## Materials and Methods

Twenty-seven patients (three women, 24 men) with cervical lymphadenopathy stage N3 were included in this study. Of these, 22 patients had a history of previous surgery, radiation therapy, or chemotherapy. Owing to arteriosclerosis or intolerance to brain ischemia, the balloon was detached permanently in only 22 patients. CT was performed in all 27 patients before angiography to demonstrate carotid involvement and extension of tumor into the carotid wall (Fig. 1). Selective four-vessel extra- and intracranial angiography was performed in all patients after catheterization of the femoral artery using the Seldinger technique. A thin-walled 7-French introducer (Balt Co., France) was used in all cases. Cervical lymphadenopathy stage N3 is a disorder characterized by the American Joint Committee on Cancer as having massive homolateral node(s), bilateral nodes, or contralateral node(s).





1



2

Fig. 1.—Axial CT scan of neck in a 45-year-old patient with cervical lymphadenopathy stage N3. A large, infiltrating heterogeneous mass is seen involving the carotid artery on the right (arrowhead).

Fig. 2.—Lateral view of skull shows position of the two detached balloons (arrows). Histoacryl mixture fills carotid below second balloon (arrowheads).

All procedures were performed under neuroleptic analgesia to ensure that the patients would be awake and responsive during the procedure. Neuroanalgesia was achieved with flunitrazepam or medazolam associated with fentanyl or R1406. Blood pressure was carefully monitored during the whole procedure. Systemic heparinization was used in all patients, both before and during the procedure.

A Pur-Sil catheter (Balt Co., France) of progressive suppleness with detachable balloon was used. This new microcatheter system has greatly improved the safety and efficacy of therapeutic endovascular techniques. The catheter combines total flexibility with an excellent torque control. The remarkable suppleness of the last 25 cm removes almost entirely the risk of arterial spasm. The Teflon tip has been adapted for use with detachable inner valve balloons, which can be detached by continuous gentle traction.

The balloon was placed in the internal carotid artery immediately proximal to the origin of the ophthalmic artery (Fig. 2). Catheterization of the contralateral carotid artery was done by using the opposite femoral artery. A 30-min occlusion test by balloon inflation was administered to all patients. During this time, the patients were maintained under careful neurologic control. A control injection into the opposite carotid artery was done to demonstrate the presence of collateral circulation to the potentially ischemic hemisphere. In five patients, the balloon was not detached because of either arteriosclerosis or intolerance to ischemia (positive occlusion test). In the remaining 22 patients, the balloon was detached and the catheter withdrawn. A second balloon was put in place below the first and also detached (Fig. 2). Histoacryl (Braun-Melsugen AG, Germany), an embolizing agent, was then injected into the occluded carotid artery down to the level of the carotid bifurcation. Histoacryl contains an active adhesive agent (butyl 2-cyanoacrylate). This compound, like other similar cyanoacrylates when applied to the intima or media of the blood vessels, produces rapid thrombosis. The amount of Histoacryl injected below the second balloon varied between 0.5 and 0.7 ml. This amount is sufficient to produce a clot large enough to occlude the carotid from the second balloon to the level of the bifurcation. The injection is progressively done under fluoroscopic control down to the level of the carotid bifurcation. A mixture of 50% Histoacryl and 50% Lipiodol and tantalum powder is usually injected. The time required for a complete occlusion of the vessel is usually a few seconds.

All 22 patients in the study were out of bed 3 days after the procedure. To allow normalization of blood perfusion in the affected brain hemisphere, a period of at least 10 days was necessary before surgical removal of the neck tumor.

## Results

Of the 27 patients with cervical lymphadenopathy stage N3, 22 had complete presurgical endovascular balloon occlusion of the carotid artery. The final occlusion was not performed in five cases because two patients demonstrated significant arteriosclerotic vascular disease and three patients had positive occlusion tests. In these three patients, the procedure had to be discontinued owing to the appearance of neurologic signs (hemiparesis) indicating poor tolerance to brain ischemia (positive occlusion test). In all cases there was complete recovery after the balloon was deflated. Of the 22 patients who had the occlusion done, on close follow-up only two (10%) showed neurologic changes after the occlusion. These changes, which consisted of progressive hemiplegia that started 24 hr after the procedure, were most likely due to a decrease in brain perfusion after the occlusion. This figure (10%), however, is significantly lower when compared with the percentage of complications reported after surgical ligation of the carotid artery (41–54% stroke with severe hemiplegia and 32–60% mortality) [2]. No occlusion test was done before ligation of the artery in this series.

To evaluate the results of the balloon occlusion itself, we have compared the number of complications in two groups of patients who had the same endovascular procedure performed for different diseases: patients with neck cancer and patients in whom the procedure was performed to treat giant aneurysms. In both groups, the technical aspects of the embolization were similar except for the additional injection of Histoacryl in patients with neck cancer. This injection, however, was done only as an extra security measure to ensure complete occlusion of the carotid artery; it does not significantly affect the end result of both procedures, which is the complete occlusion of the carotid artery. We believe, therefore, that a fair comparison of complications between these two groups of patients has been done.

In a group of 103 patients at the Rothschild Foundation in whom the carotid artery was occluded by balloon occlusion to treat 53 large carotid artery aneurysms, 29 cavernous fistulas, and 21 miscellaneous vascular tumors, the compli-



cations resulted in only three transient ischemic deficits (3%), one hemiplegia (1%), and one death (1%). These figures are significantly lower than the complications seen after treating cancer patients (10%). Since the procedure is almost identical in both cases, the direct involvement of the carotid artery by the tumor and probably the poor general condition of the patient are the two factors most likely responsible for these results.

## Discussion

The surgical treatment of cervical lymphadenopathy stage N3 usually presents a significant number of problems. If the carotid artery is involved, only partial removal of the tumor is possible. On the other hand, if the artery ruptures or has to be removed during the tumor surgery, ligation must be performed under emergency conditions, a procedure that carries a significant risk of brain ischemia. Disastrous consequences of ligation of the carotid artery occur mainly in those patients in whom ligation has been performed at a time when the blood pressure is low because of preceding hemorrhage or shock [3]. Aggressive surgical approaches such as carotid resection and surgical replacement (bypass) and axillo-internal carotid bypass have been proposed to prevent brain ischemia [4, 5]. The results of these procedures are not yet clearly established. Even when the artery is not invaded directly by the tumor, owing to the postsurgical exposure of the artery, the risk of a spontaneous rupture after the surgery is significant. By destroying the adventitia of the vessel, radiation necrosis (if the patient has had radiation therapy) and infection also create an ideal set-up for an arterial rupture [6–12]. The result of carotid rupture is life-threatening and manifested by hypotension, shock, brain ischemia, and/or death [2–12].

Other factors that complicate radical surgery in patients with neck cancer are related to the patient's poor general condition. For example, anemia and hypoproteinemia are factors that prevent normal healing and facilitate arterial rupture [13]. Arteriosclerotic disease in the involved artery and/or the other arteries leading to the brain is also an important factor that may influence the results of neck surgery. Owing mainly to the fear of carotid artery rupture, the surgeon is quite limited in his attempt to remove the entire tumor; most lesions, therefore, are only partially removed.

In our experience with the 27 patients with cervical lymphadenopathy stage N3 who were treated with preoperative endovascular detachable balloon occlusion of the carotid artery, we found that this procedure significantly facilitated surgery and improved the surgical results. Since the procedure is considered low risk, it can be performed before neck surgery in the majority of patients. In our series, after the balloon occlusion and Histoacryl injection, cancer patients had a slightly higher number of complications when compared with patients treated with carotid aneurysms who had only the balloon occlusion. Since the injection of Histoacryl was done only as a safety measure in case of balloon rupture or deflation, this procedure plays no significant role in the occlusion of the artery and related complications. The results obtained are not surprising. The patients treated for aneurysms are usually younger, their general condition is better

than the patients with cancer, and there is no tumor invading the artery in the neck. It seems, therefore, that the complication rate in balloon occlusion of the carotid artery is related mainly to the patient's clinical condition rather than to the occlusion itself. It should also be mentioned that, in our study, the five patients not treated with balloon occlusion would most likely have developed significant complications if the arteries had been occluded without the benefit of an arteriogram and the occlusion test. In patients in whom the occlusion test is positive, external carotid-middle cerebral artery or other bypass procedures can be performed prior to a new occlusion test and final detachment of the balloon. No bypass procedures were performed in our patients because of the nature and extension of the neck tumor and the life expectancy of the patients. In all of them it was decided that under these conditions this procedure was not justifiable.

In reference to the occlusion test as a means to preselect the patients sensitive to brain ischemia before the operation, an interesting new application of the stable xenon/CT cerebral blood flow (Xe/CT/CBF) technique has been described (Schwartz M, Horton JA, DeVries E, Sekhar L, Pentheny S, Yonas H. A new method to predict safe resection of the internal carotid artery. Presented at the annual meeting of the American Society of Neuroradiology, Orlando, March 1989) and [14]. Abnormalities of blood flow were detected in 11% of the patients who clinically tolerated well a brief balloon occlusion test of the internal carotid artery. These patients, of course, have a significant risk of cerebral infarction if the tested artery is sacrificed. Since this moderate-risk group of patients cannot be identified with any other traditionally known method of measuring blood flow, we think that Xe/CT/CBF should be done preoperatively in all patients for whom balloon occlusion of the carotid artery is considered. Although we did not perform this test at the time of this study, we believe that it could have been of help to avoid the few complications we found. Routine EEG monitoring to detect signs of early ischemia during the occlusion test, as currently done to monitor carotid endarterectomy, may also be a valuable procedure to reduce the number of complications [15, 16].

In evaluating the patient before the occlusion, it is important to perform four-vessel angiography to determine the presence of arteriosclerotic changes. The degree of arterial stenosis is a determining factor in the decision to perform arterial occlusion or even tumor removal. Significant vascular disease of the opposite carotid artery, for example, is a contraindication for endovascular occlusion [17]. CT should be performed because angiography cannot always demonstrate the extent of arterial tumoral invasion.

Another advantage of the procedure is that balloon occlusion also prevents emboli or clots from reaching the cerebral vessels, a problem commonly seen after surgical ligation of the artery. In this situation, the site of occlusion becomes a source of emboli. This risk is particularly high if the ligature is placed on the internal carotid artery above the bifurcation. Figure 3 shows in detail the pathophysiology of this phenomenon. When an occluding balloon is placed at the carotid siphon, clots originating anywhere below this region cannot reach the cerebral circulation.



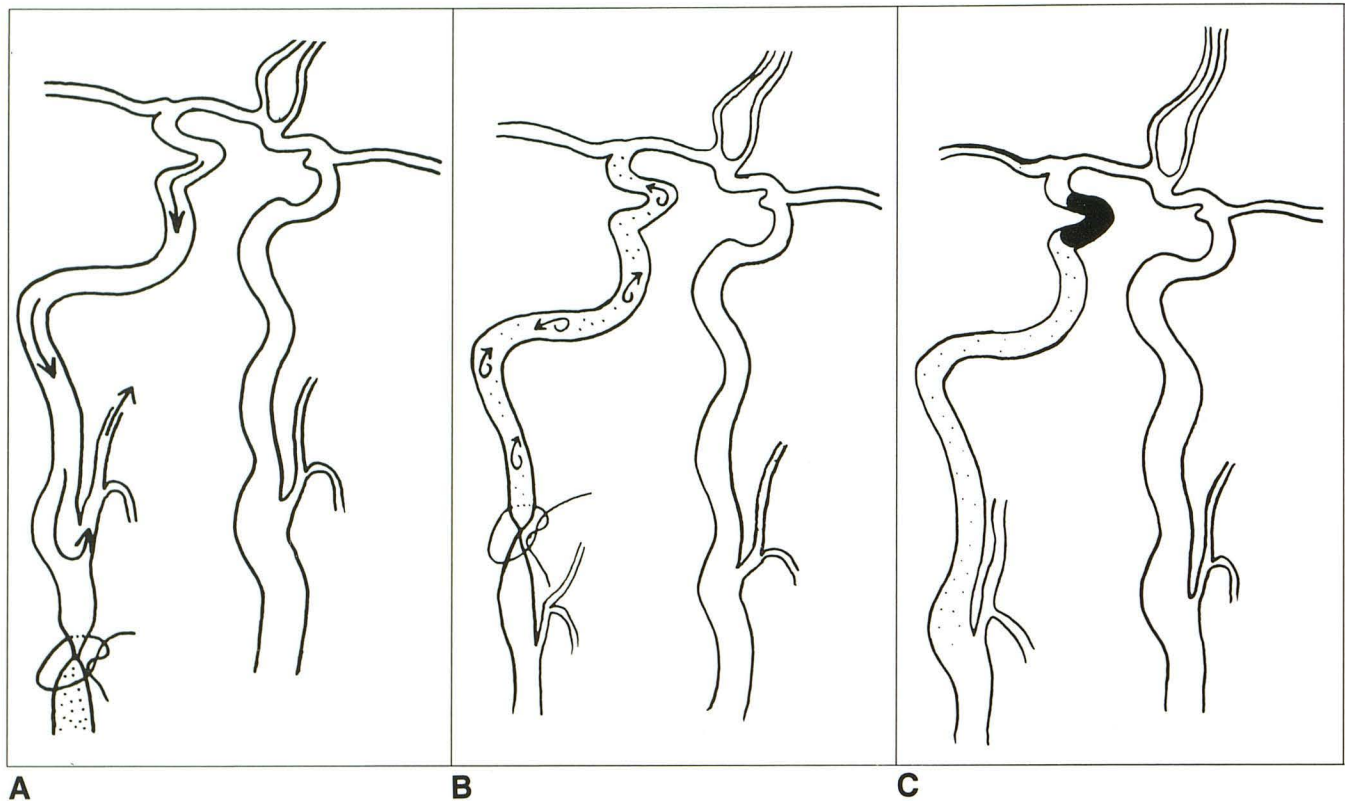


Fig. 3.—A–C, Schematics show the risk of cerebral embolization after surgical ligation of common carotid artery (A), internal carotid artery (B), and balloon occlusion (C). Notice that the risk of emboli is greater when the ligature is placed on the internal carotid artery. The endovascular balloon occlusion is totally free of emboli.

After successful occlusion of the artery, the surgeon is finally free to perform radical tumor removal, which may significantly improve the patient's overall treatment [18]. It is our opinion that complete removal of the tumor certainly benefits the patient's condition. However, we have not as yet compared the results of the treatment of the patients with complete removal versus those who had only partial tumor removal because of fear of arterial rupture. For best results, the patient's final neck surgery should take place at least 10 days after the occlusion procedure to permit normalization of the brain perfusion in the affected hemisphere.

In conclusion, we believe that all patients with cervical lymphadenopathy stage N3 involving the carotid artery may benefit significantly if preoperative endovascular detachable balloon occlusion of the carotid artery is performed before radical neck surgery. This procedure is simple, prevents embolic complications, and allows a presurgical evaluation of the brain response to ischemia. This technique also permits radical surgery for patients with carotid lymphadenopathy stage N3, thus improving the final response to treatment.

#### REFERENCES

- Serbinenko FA. Balloon catheterization and occlusion of major cerebral vessels. *J Neurosurg* 1974;41:125–145
- Razack MS, Sako K. Carotid artery hemorrhage and ligation in head and neck cancer. *J Surg Oncol* 1982;19:189–192
- Martis C, Karabouta I, Lazariou M. The internal carotid artery in the surgery of extensive oral cancer. *Int J Oral Maxillofac Surg* 1986;15:113–118
- Carabasi RA III, DeLaurentis DA. Axillo-internal carotid artery bypass in the treatment of neck metastases. *J Vasc Surg* 1985;2:578–580
- Biller HF, Urken M, Lawson W, Haimov M. Carotid artery resection and bypass for neck carcinoma. *Laryngoscope* 1988;98:181–183
- Marchetta FC, Sako K, Maxwell W. Complications after radical head and neck surgery performed through previously irradiated tissues. *Am J Surg* 1967;114:835–838
- Nieto CS, Solano JME, et al. The carotid artery in head and neck oncology. *Clin Otolaryngol* 1980;5:403–417
- Swain RE, Biller HG, Ogura JH, Harvey HE. An experimental analysis of causative factors and protective methods in carotid artery rupture. *Arch Otolaryngol* 1974;99:235–241
- Martinez SA, Oller DW, Gee W, de Fries HO. Elective carotid artery resection. *Arch Otolaryngol* 1975;101:744–747
- Heller KS, Strong EW. Carotid arterial hemorrhage after radical head and neck surgery. *Am J Surg* 1979;138:607–610
- Hillerman BL, Kennedy TL. Carotid rupture and tissue coverage. *Laryngoscope* 1982;92:985–988
- Ketcham AS, Hoyer RC. Spontaneous carotid artery hemorrhage after head and neck surgery. *Am J Surg* 1965;110:649–655
- Sanders EM, Davis KR, Whelan CS, Deckers PJ. Threatened carotid artery rupture: a complication of radical neck surgery. *J Surg Oncol* 1986;33:190–193
- Erba SM, Horton JA, Latchaw RE, et al. Balloon test occlusion of the internal carotid artery with stable xenon/CT cerebral blood imaging. *AJNR* 1988;9:533–538
- Blume WT, Ferguson GG, McNeill DK. Significance of Ee EEG changes at carotid endarterectomy. *Stroke* 1986;17:891–897
- Cho I, Smullens SN, Streletz LJ, Fariello RG. The value of intraoperative EEG monitoring during carotid endarterectomy. *Ann Neurol* 1986;20:508–512
- Atkinson DP, Jacobs LA, Weaver AW. Elective carotid resection for squamous cell carcinoma of the head and neck. *Am J Surg* 1984;148:483–488
- Magee HR. The carotid artery in head and neck surgery. *Aust NZ J Surg* 1986;56:863–864