



Discover Generics

Cost-Effective CT & MRI Contrast Agents



[VIEW CATALOG](#)

AJNR

Benign lumbar arachnoiditis: MR imaging with gadopentetate dimeglumine.

C E Johnson and G Sze

AJNR Am J Neuroradiol 1990, 11 (4) 763-770

<http://www.ajnr.org/content/11/4/763>

This information is current as of September 14, 2025.

Benign Lumbar Arachnoiditis: MR Imaging with Gadopentetate Dimeglumine

Carl E. Johnson^{1,2}
Gordon Sze³

MR imaging was performed in 13 patients with benign lumbar arachnoiditis both before and after IV injection of gadopentetate dimeglumine. The arachnoiditis was proved by previous myelography in 12 patients and by noncontrast MR imaging in one patient. The disease was presumably the result of previous myelography and/or surgery. It was characterized as mild in two patients, moderate in two patients, and severe in nine patients. Imaging was performed on a 1.5-T unit, and both short and long TR images were obtained before and after contrast administration. Noncontrast MR images demonstrated changes consistent with arachnoiditis in all patients. After contrast, three patients had no enhancement, three patients had minimal enhancement, three patients had mild enhancement, and four patients had moderate enhancement. In no case did contrast enhancement alter the diagnosis or reveal additional findings that could not be seen on the noncontrast images.

Gadopentetate dimeglumine enhancement plays little role in the diagnosis of lumbar arachnoiditis. If used for another reason, however, short TR scans may show enhancement of adherent roots in some cases. In addition, administration of gadopentetate dimeglumine will not cause sufficient enhancement to hinder the detection of arachnoiditis on long TR images and may aid in recognition of adherent roots on short TR images.

AJNR 11:763-770, July/August 1990; *AJR* 155: October 1990

Previous work has shown the utility of gadopentetate dimeglumine in the MR imaging evaluation of neoplastic extradural, intradural, extramedullary, and intramedullary spinal disease [1-7]. Gadopentetate dimeglumine enhancement has also proved of great benefit in the postoperative spine for differentiating recurrent or residual disk herniation from scar [8]. However, the role of gadopentetate dimeglumine, if any, in the detection or characterization of benign lumbar arachnoiditis has not been established. In this study, we sought to determine if gadopentetate dimeglumine can aid in the evaluation of lumbar arachnoiditis.

Subjects and Methods

Thirteen patients with lumbar arachnoiditis were included in this study. In 12 cases the disease was proved by previous myelography. The time between myelography and MR ranged from approximately 3 years (three patients) to less than 6 weeks (seven patients). In one patient findings of lumbar arachnoiditis were present on noncontrast MR images.

Eleven patients had had previous lumbar spine surgery followed by intractable low back pain and/or radicular pain with variable degrees of functional disability. All 13 patients had had previous myelography, 11 with iophendylate (Pantopaque). Four had residual Pantopaque within their thecal sacs.

Arachnoiditis was categorized on myelograms as mild (two patients), moderate (two patients), or severe (eight patients). It was considered mild if myelography showed an absence of filling of single or multiple nerve root sleeves and segmental nerve root fusion. Moderate arachnoiditis, in addition to a lack of nerve root sleeve filling, also demonstrated multisegmental nerve root fusion or a featureless thecal sac secondary to peripherally adherent nerve

Received August 8, 1989; revision requested October 16, 1989; revision received January 12, 1990; accepted January 18, 1990.

¹ Sloan-Kettering Cancer Center and The New York Hospital-Cornell Medical Center, New York, NY 10021.

² Present address: Department of Diagnostic Radiology, Long Island College Hospital, 340 Henry St., Brooklyn, NY 11201. Address reprint requests to C. E. Johnson.

³ Yale University School of Medicine, New Haven, CT 06510.

0195-6108/90/1104-0763
© American Society of Neuroradiology

roots. Severe arachnoiditis exhibited a large cordlike mass of nerve roots, a soft-tissue mass filling the thecal sac, or myelographic block. The patient in whom arachnoiditis was proved by noncontrast MR was considered to have severe disease on the basis of the finding of a multisegmental cordlike mass of adherent roots.

MR imaging was performed on superconductive magnets operating at 1.5 T in 12 patients and at 0.6 T in one patient. Surface coils were employed in all studies. Using the 1.5-T unit, we obtained short TR axial images with parameters of 400–800/20/2–4 (TR/TE/excitations), 5–10 mm slice thickness, 16–20 cm field of view (FOV), and a 256 × 256 matrix. Short TR sagittal images were acquired at 400–600/20/2–4, with a 3–5 mm slice thickness, 22–28 cm FOV, and a 256 × 256 (10 patients) or 256 × 192, (one patient), or 256 × 128 (one patient) matrix. Multiecho long TR sagittal images were obtained at 2000/35,70 (seven patients), 2000/40,80 (one patient), 2000/30,80 (one patient), 2000/30,90 (one patient), and 1800/35,70 (two patients), with a 3–5 mm slice thickness, 22–28 cm FOV, 1–2 excitations, and a 256 × 256, 256 × 192, or 256 × 128 matrix. Long TR axial images were acquired using similar parameters with the exception that either 5- or 10-mm-thick slices were obtained using a 16–20 cm FOV and 2 excitations. In one patient gradient-echo axial images were obtained at 450/17 with a 20° flip angle. Gradient-moment nulling techniques were employed during acquisition of the long TR images, while presaturation techniques were used for the short TR sequences. For the single patient studied at 0.6 T, the following parameters were used: short TR sagittal images were obtained at 500/35/4 with a 3-mm slice thickness, a 28-cm FOV, and 256 × 192 matrix. Short TR axial images were obtained similarly but at 750/35. Long TR sagittal images were acquired at 2000/40,80/2 with a 3-mm slice thickness, 28-cm FOV, and 256 × 128 matrix. No long TR axial images were acquired owing to patient discomfort.

Both short and long TR images were obtained before and after contrast administration in the first six patients studied. Short TR sagittal and short TR axial images were acquired followed by long TR sagittal and long TR axial images. After these sequences were completed, 0.1 mmol/kg of gadopentetate dimeglumine was injected intravenously. After the injection, short TR axial and short TR sagittal scans were acquired followed by long TR sagittal and long TR axial images. The long TR postcontrast images were omitted in the last six patients when it became clear from the earlier examinations that there was no discernible difference between the noncontrast and contrast-enhanced long TR images and that the postcontrast sequences did not add to the detection of arachnoiditis. In one patient, long TR sagittal and gradient-echo axial images were obtained after contrast injection. Also, postcontrast long TR axial images could not be obtained in one patient early in this study owing to fatigue from the long time spent in the scanner. Actual imaging time for the majority of patients ranged from approximately 60–90 min with the examination time ranging from 1¼ to 3½ hr.

The images were evaluated as follows: First, the unenhanced images were assessed for findings indicative of arachnoiditis [9]. Second, the unenhanced and enhanced short TR images were subjectively compared for evidence of enhancement associated with arachnoiditis. The contrast-enhanced images were scored on a scale of 0–3: 0 indicated absence of enhancement, 1 = minimal enhancement, 2 = mild enhancement, and 3 = moderate enhancement. Only the presence of enhancement of adherent nerve roots or of the soft-tissue mass within the thecal sac was evaluated. Enhancement of the dural tube secondary to peripherally thickened meninges or peripherally adherent nerve roots was seen in seven patients. However, in view of the history of previous surgery, this finding was not used to determine if there was enhancement associated with arachnoiditis. Third, the pre- and postcontrast long TR images in the initial patients were also compared to determine if contrast administration might interfere with the detection of arachnoiditis on long TR images.

Finally, the contrast-enhanced MR findings were compared with the severity and chronicity of the patients' symptoms and with the results of the CSF analysis, if available. Specifically, any correlation between the clinical histories and the presence or absence of enhancement was sought.

Results

The results are summarized in Table 1. MR findings consistent with changes of arachnoiditis were found in all patients. These included clumps of adherent roots centrally located within the thecal sac, peripherally adherent nerve roots with resultant thickened meninges giving rise to an "empty" thecal sac, and a soft-tissue mass replacing the subarachnoid space [9]. In general, the MR appearance correlated well with that of myelography and postmyelographic CT, although three of the seven patients with severe arachnoiditis had myelographic block that could not be accurately predicted by MR.

In the two patients with mild arachnoiditis, no enhancement of adherent roots demonstrated on the noncontrast MR scans was seen in one and minimal enhancement was seen in the other. Minimal enhancement was seen in one patient with moderate arachnoiditis, while moderate enhancement was found in the other. Of the nine patients with severe arachnoiditis, two showed no enhancement, one had minimal enhancement (Fig. 1), three had mild enhancement (Fig. 2), and three were judged to have moderate enhancement (Figs. 3 and 4). In no patient was intense enhancement seen after contrast infusion, and in no case did contrast enhancement alter the diagnosis or reveal findings indicative of arachnoiditis that could not be seen on the noncontrast images. In five patients, however, clumped nerve roots were easier to recognize on the enhanced images because of greater CSF-nerve root contrast.

Aggregates of adherent nerve roots were most easily recognized on long TR axial images, although in no cases were centrally clumped roots shown on long TR images that were not evident on the short TR axial images. An amorphous soft-tissue mass replacing the subarachnoid space was more easily recognized on the short TR images, however. In two patients, inhomogeneous signal intensity was present on the long TR images, although the fact that an amorphous soft-tissue mass filled the thecal sac was not obvious. In another patient, the soft-tissue mass could be recognized on the long TR/short TE images but not on the long TR/long TE images.

Short TR sagittal images were the least sensitive to the detection of centrally clumped roots. In the two patients who had mild arachnoiditis with only segmentally adherent nerve roots within the thecal sac, no abnormality was discernible on the sagittal images. No qualitative difference between long TR images obtained before or after contrast injection was observed.

There was inconsistent correlation among the severity and chronicity of the patients' symptoms, CSF protein analysis, and contrast-enhanced MR findings. MR findings of severe arachnoiditis were seen most often in patients with more severe and chronic disabilities. Enhancement, however, was variable. Six patients with severe disability (chronic low back

TABLE 1: Myelography, Postmyelographic CT, and MR Findings in Lumbar Arachnoiditis

Case No.	Age (years)	Sex	Degree of Arachnoiditis on Myelographic/Postmyelographic CT	MR Findings	Enhancement
1	50	M	Mild	Focally clumped nerve roots at L3.	0
2	37	F	Severe with block	Centrally and peripherally adherent roots at L3 and S1; loculation in thecal sac at L4-L5 at site of myelographic block	3
3	41	F	Severe	Central cordlike nerve root mass from L2 through L4; "empty" thecal sac from L4 through S1	2
4	31	M	Mild	Focally adherent roots at L4	1
5	54	F	Severe	Centrally clumped roots from L4 through S1; stenosis at L4-L5 with irregularly tapered distal sac	2
6	51	F	Severe	Peripherally adherent nerve root mass at L3; amorphous soft-tissue mass filling sac from L4 through S1	0
7	63	M	Severe with block at L3	Amorphous soft-tissue mass filling thecal sac from L3 through S1	3
8	48	M	Severe with block at L3	Amorphous soft-tissue mass filling sac from L3-L4 through L5-S1	0
9	55	F	Moderate	Centrally and peripherally clumped roots at L3 and L4; "empty" thecal sac below L4	1
10	59	F	Moderate	Centrally clumped roots from L2 through L4; "empty" thecal sac from L4 through S1 with peripherally adherent roots	3
11	68	M	Severe	Ill-defined soft-tissue mass filling thecal sac from L2 through L4; centrally clumped roots at L4-L5 with peripherally adherent roots from L4-L5 through S1	1
12	45	M	—	Focally clumped roots at L2 and L3; cordlike mass of adherent roots at L4 and L5	2
13	66	F	Severe	Eccentric cordlike nerve root mass from L2 through L5	3

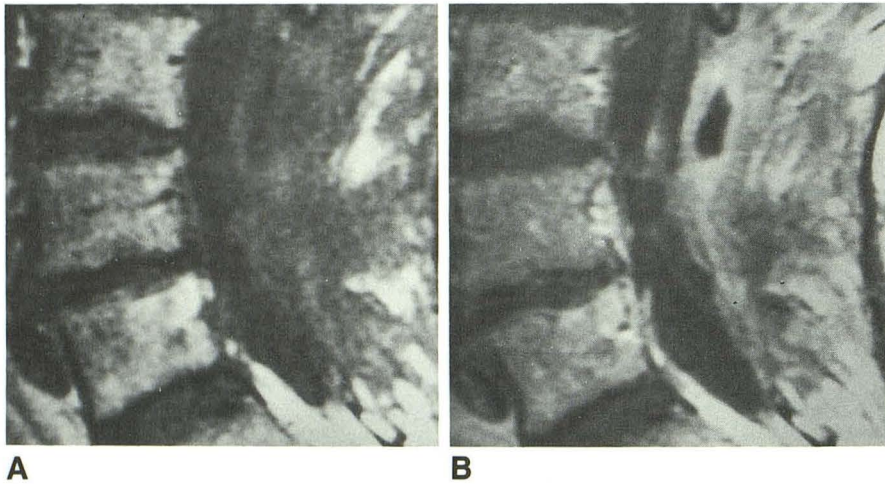


Fig. 1.—Case 11. Severe arachnoiditis with minimal enhancement.

A and B, Short TR images (600/20) of lumbar spine before (A) and after (B) contrast administration show severe arachnoiditis with minimal enhancement.

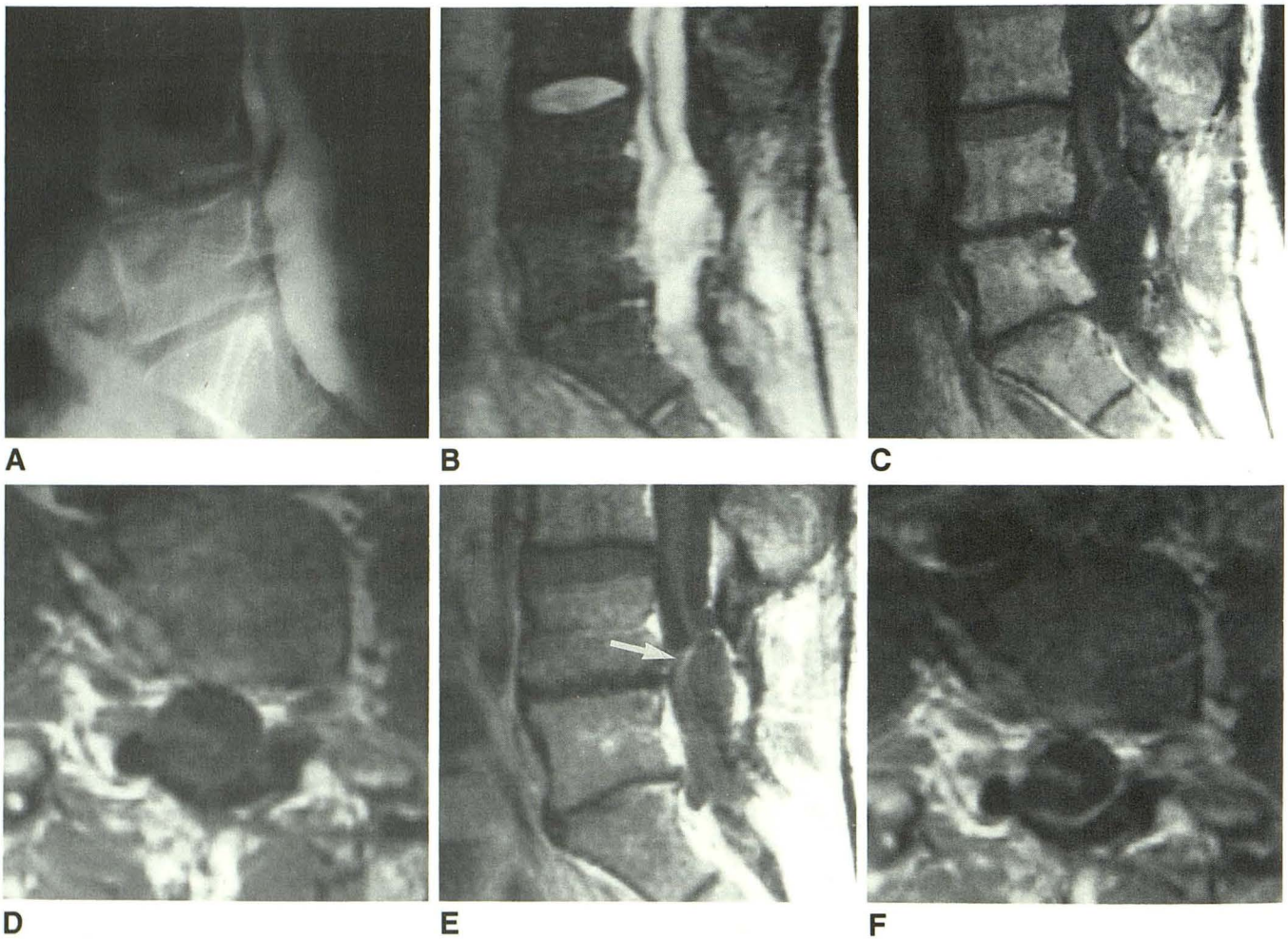


Fig. 2.—Case 3: Severe arachnoiditis with mild enhancement.

A, Lateral view of lumbar myelogram shows a thick cord of adherent nerve roots within thecal sac. No nerve roots are identified within thecal sac below level of L5.

B, Sagittal long TR image (2000/70) shows thick cord of nerve roots within thecal sac closely corresponding to myelographic appearance.

C-F, Cordlike mass of nerve roots is seen faintly within thecal sac on precontrast sagittal (C) and axial (D) short TR images (600/20). On postcontrast images (E and F) there is minimal to mild enhancement of this nerve root cord (arrow in E).

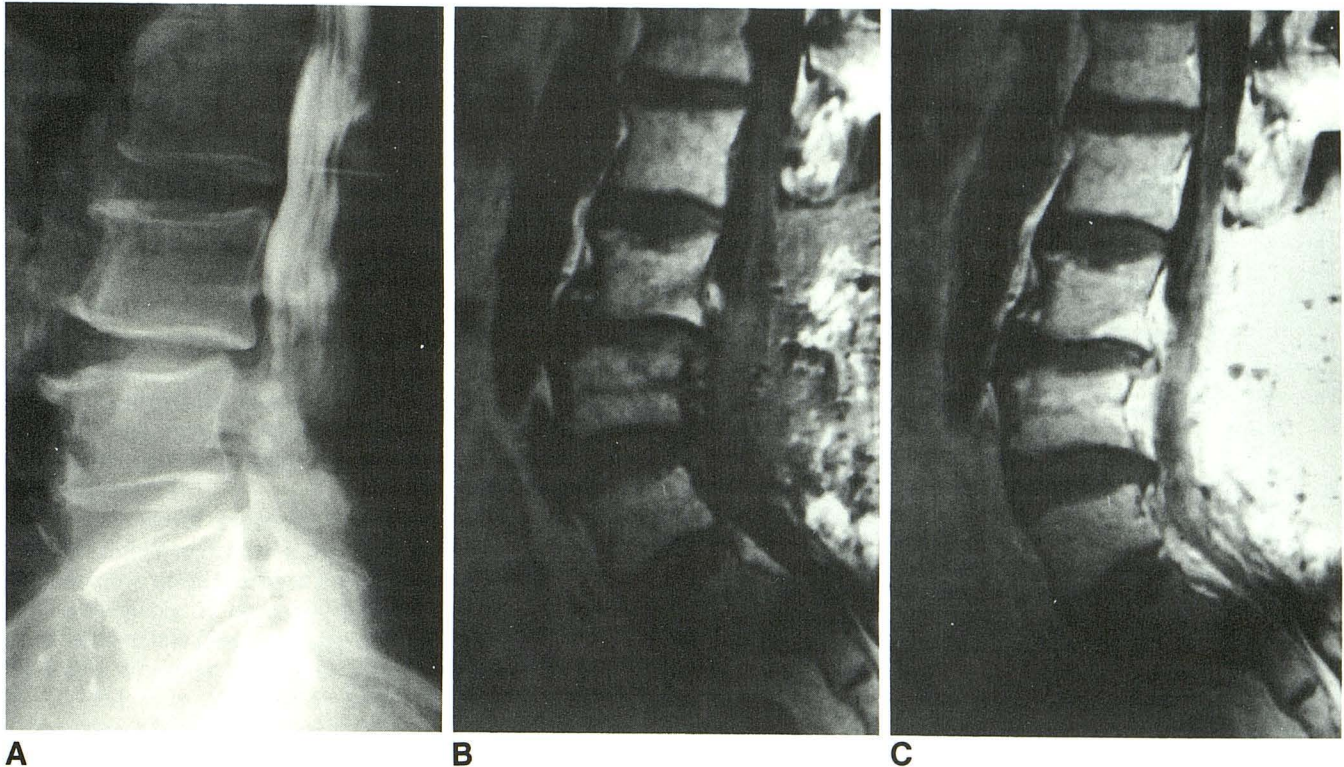


Fig. 3.—Case 7: Severe arachnoiditis with moderate enhancement. **A**, Lateral view of lumbar myelogram shows irregular collection of contrast within the most distally filled aspect of thecal sac, thickened nerve roots, and block at L3–L4. **B** and **C**, Sagittal precontrast (**B**) and postcontrast (**C**) short TR images (500/20) of lumbar spine. After contrast infusion there is inhomogeneous, amorphous enhancement of contents of thecal sac. Note also the marked enhancement of postoperative scar posterior to thecal sac at the site of previous laminectomy, and enhancement of the epidural venous plexus and/or postoperative scar posterior to L3 and L4 vertebral bodies.

and radicular pain, leg weakness, gait disorder, and incontinence) demonstrated centrally clumped nerve roots or an amorphous distal thecal sac mass; yet, enhancement ranged from none (two patients) to moderate (two patients). One patient with severe disability had only mild arachnoiditis, which did not enhance. The five patients with symptoms moderate in severity (chronic low back and multilevel radicular pain and paresthesias) showed MR findings of moderate to severe arachnoiditis with minimal to moderate enhancement. One patient with mild symptoms had mild arachnoiditis with minimal enhancement. Similarly, little correlation was seen between the chronicity of patients' symptoms and the contrast-enhanced MR findings. Patients with more chronic symptoms (greater than 5 years) had MR findings of severe arachnoiditis with no to moderate enhancement, while those with less than a 5-year history had mild to severe arachnoiditis with variable degrees of enhancement.

CSF protein analysis was available in nine patients. The protein was normal in six patients with mild to severe arachnoiditis with variable enhancement. One patient with mildly elevated CSF protein (62 mg/dl) had severe arachnoiditis with mild enhancement. Two patients with markedly elevated protein (306 and 1110 mg/dl) had severe arachnoiditis with minimal and no enhancement, respectively. The patient with

the protein of more than 1000 mg/dl had lumbar myelographic block secondary to arachnoiditis and cervical block related to a Chiari malformation. The protein returned to normal after decompressive cervical laminectomy.

Discussion

Chronic adhesive arachnoiditis stems from a variety of causes, including agents injected into the subarachnoid space (contrast media, anesthetic agents, and intradural steroids), infection, trauma, intradural or extradural surgery, and intrathecal hemorrhage [10]. All of the patients in this study had previous myelography and 11 had previous surgery. Iophendylate (Pantopaque) had been used for myelography in 11 patients including the two patients with no prior surgery. One of the patients without prior surgery had also received multiple facet blocks and steroid injections.

The initial inflammatory response in the development of arachnoiditis consists of a fibrinous exudate with a minimal vascular inflammatory cellular reaction [10]. In the absence of cell-released fibrolytic enzymes, the fibrin-coated nerve roots and arachnoid membrane adhere to one another. Subsequently, collagenized adhesions are formed by proliferating

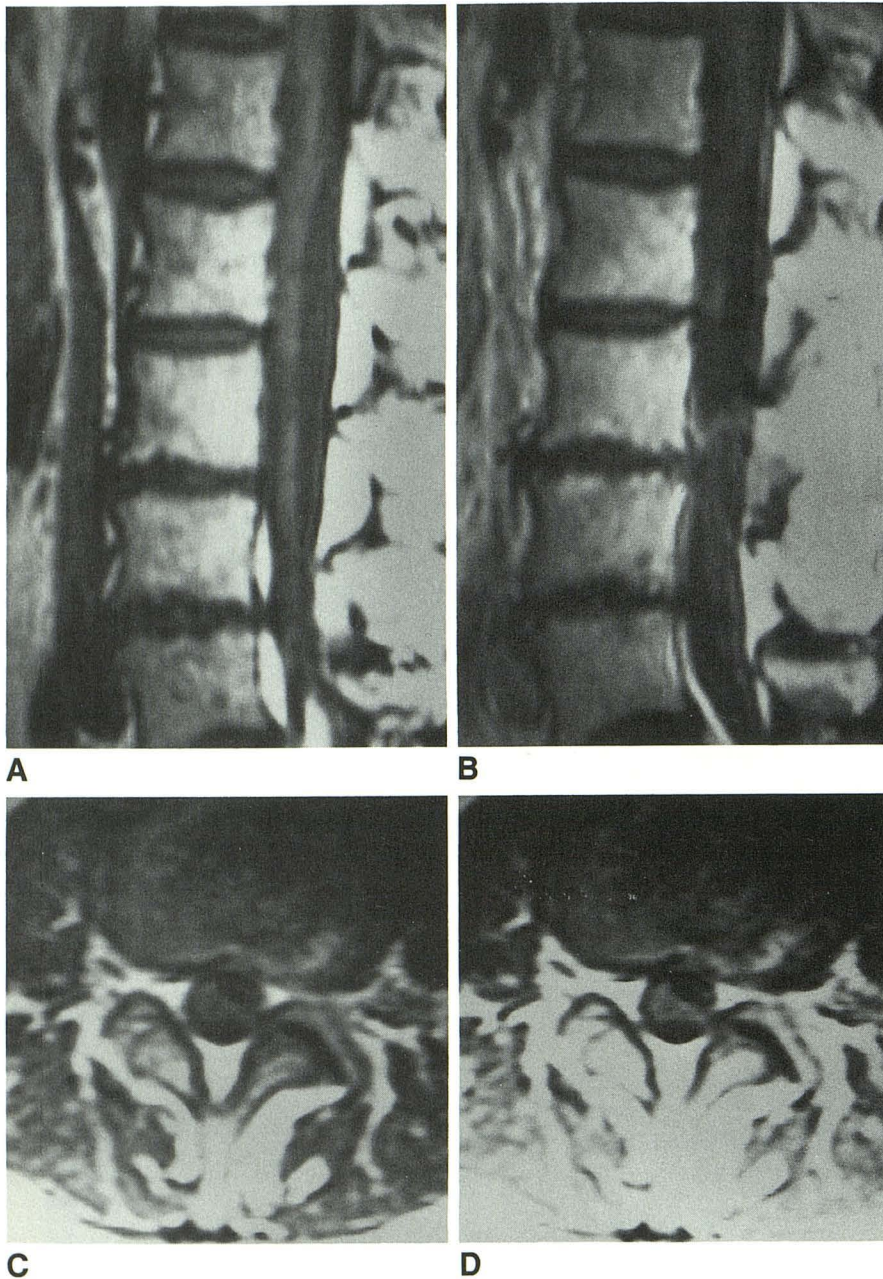


Fig. 4.—Case 13. Severe arachnoiditis with moderate enhancement.

A–D, Sagittal short TR images (500/20) before (A) and after (B) contrast administration and axial short TR images (700/20) before (C) and after (D) contrast show severe arachnoiditis with moderate enhancement.

fibroblasts leading to the well-recognized myelographic findings of arachnoiditis.

On myelography mild arachnoiditis may show only lack of filling of one or more nerve root sleeves, segmental nerve root fusion, and small irregularities of the contrast column [11]. Progression of nerve root fusion with peripheral adherence of the nerve roots to the dural tube leads to the appearance of the so-called "featureless" or "empty" thecal sac. With more severe arachnoiditis, progression of nerve root clumping and leptomenigeal adhesions occur and there may be bizarre, large angular defects on the contrast column with a mass of fibrotic nerve roots filling the thecal sac. This may

cause myelographic block found in up to two thirds of patients with severe arachnoiditis [12].

In this study findings of arachnoiditis were visible on MR in all patients, correlating well with those found on myelographic or postmyelographic CT. Admittedly, our observations were biased by the fact that in all but one of the patients studied the diagnosis had been previously confirmed. In the absence of a known diagnosis, subtle MR findings of arachnoiditis such as segmental nerve root fusion may be difficult to detect. This is particularly true if the clumped nerve roots do not reside in the region imaged on the short TR axial images, which may occur in routine lumbar spine imaging since axial

images are only obtained through the lower intervertebral disks and vertebral endplates adjacent to the disk spaces.

In spite of the relatively avascular nature of the inflammatory response leading to the development of spinal arachnoiditis, varying degrees of focal contrast enhancement were observed involving nerve roots clumped centrally within the thecal sac in eight patients with moderate to severe arachnoiditis. Enhancement was also seen in one patient who had a soft-tissue mass filling the proximal aspect of the lumbar sac with focally adherent roots distally and in one patient in whom only an amorphous soft-tissue mass filling the thecal sac was present. Enhancement presumably occurred secondary to development of a vascular network within the proliferating fibrous stroma, allowing for accumulation of contrast medium in the extracellular space. Proliferating blood vessels have been observed histologically within fibrous tissue in arachnoiditis [13].

Enhancement of thickened meninges was seen in seven patients. Enhancement of a thickened meningeal tube in the postoperative spine has been previously described in patients who presumably do not have arachnoiditis. This peripheral enhancement has been variously attributed to peridural fibrosis, focally thickened meninges, or peripherally adherent roots [8, 14, 15]. It is uncertain to what extent this peripheral enhancement represents thickened dura or the adjacent arachnoid. It would be interesting to determine if enhancement of the meninges is seen in cases of arachnoiditis without prior surgery. This may indeed be an MR finding of arachnoiditis. However, in view of the uncertain nature of the enhancement of the meningeal tube, this finding should not be used as a sole criterion to determine if arachnoiditis is present in the absence of an obvious clump of centrally or peripherally adherent roots.

Although variable enhancement of centrally adherent nerve roots or of a soft-tissue mass filling the thecal sac was observed, the enhancement was never striking and did not aid in establishing the diagnosis in this study. Although clumped nerve roots were easier to recognize on the contrast-enhanced images in five patients, in no case were adherent nerve roots or soft-tissue mass within the thecal sac apparent only on the contrast-enhanced images. Furthermore, contrast enhancement in lumbar arachnoiditis was an inconstant finding at best, since one patient with mild arachnoiditis and two with severe arachnoiditis had no enhancement. While this is a small series and some instances may arise in which enhancement of adherent roots leads one to recognize the presence of lumbar arachnoiditis, enhancement should not be relied upon for diagnosis. On the other hand, if gadopentetate dimeglumine is administered for another reason, such as to differentiate recurrent disk herniation from scar, it will not hinder the detection of arachnoiditis on either short or long TR images and may actually be of some aid in recognition of adherent roots on short TR images. Enhancement of clumped nerve roots will not prevent visualization of the changes of arachnoiditis when they are surrounded by high-intensity CSF on long TR sequences.

The paucity of enhancement in arachnoiditis may help to differentiate this entity from leptomeningeal tumor spread.

Marked enhancement of subarachnoid deposits of tumor can occur [1]. Therefore, the finding of prominent enhancement in the intradural extramedullary space is generally more consistent with the diagnosis of leptomeningeal tumor than with benign arachnoiditis. This distinction may be particularly important in patients with known systemic tumors who have also had a history of either previous back surgery or Pantopaque myelography. However, if only mild or no enhancement is seen, then the use of gadopentetate dimeglumine does not have predictive value. Clearly, some cases of proved leptomeningeal tumor demonstrate minimal enhancement in the intradural extramedullary space [1]. Therefore, the absence of enhancement or the presence of only mild enhancement cannot be used to help to differentiate leptomeningeal tumor from benign arachnoiditis.

In conclusion, spinal arachnoiditis often has an obscure clinical presentation related to its slow progression and the simultaneous or variable occurrence of symptoms referable to the cord and multiple nerve roots [11, 16]. With the ever more prevalent use of MR as the primary and often only imaging method for examination of patients with low back pain, radiculopathy, and myelopathy, the recognition of arachnoiditis on MR is becoming more important. In this series, MR imaging correlated well with myelographic and postmyelographic CT. Our findings support those of Ross et al. [9] that moderate to severe arachnoiditis can be diagnosed with unenhanced MR imaging. Long TR axial images perhaps best demonstrate centrally clumped or peripheral adherent roots, although these changes can be seen on short TR images. In mild cases of arachnoiditis the diagnosis may be suspected if there are segmentally clumped roots centrally located in the lower lumbar thecal sac, provided they are included in the axial images obtained. Gadopentetate dimeglumine enhancement plays little role in the diagnosis of lumbar arachnoiditis.

ACKNOWLEDGMENTS

We thank Richard Becker and Jerry Van Dyke for each contributing a case to this series.

REFERENCES

1. Sze G, Abramson A, Krol G, et al. Gadolinium-DTPA in the evaluation of intradural extramedullary spinal disease. *AJNR* 1988;9:153-163, *AJR* 1988;150:911-921
2. Sze G, Krol G, Zimmerman RD, Deck MDF. Malignant extradural spinal tumors: MR imaging with Gd-DTPA. *Radiology* 1988;167:217-223
3. Sze G. MR of the spine: contrast agents. *Radiol Clin North Am* 1988;26:1009-1024
4. Sze G, Krol G, Zimmerman RD, Deck MDF. Intramedullary disease of the spine: diagnosis using gadolinium-DTPA-enhanced MR imaging. *AJNR* 1988;9:847-858, *AJR* 1988;151:1193-1204
5. Stimac GK, Porter BA, Olson DO, Gerlach R, Genton M. Gadolinium-DTPA-enhanced MR imaging of spinal neoplasms: preliminary investigation and comparison with unenhanced spin-echo and STIR sequences. *AJNR* 1988;9:839-846, *AJR* 1988;151:1185-1192
6. Dillon WP, Norman D, Newton TH, Bolla K, Mark A. Intradural spinal cord lesions: Gd-DTPA-enhanced MR imaging. *Radiology* 1989;170:229-237
7. Parizel PM, Baleriaux D, Rodesch G, et al. Gd-DTPA-enhanced MR imaging of spinal tumors. *AJNR* 1989;10:249-258
8. Heuftle MG, Modic MT, Ross JS, et al. Lumbar spine: postoperative MR

- imaging with Gd-DTPA. *Radiology* **1988**;167:817-824
9. Ross JS, Masaryk TJ, Modic MT, et al. MR imaging of lumbar arachnoiditis. *AJNR* **1987**;8:885-892
 10. Quiles M, Marchisello PJ, Tsairis P. Lumbar adhesive arachnoiditis. Etiologic and pathologic aspects. *Spine* **1978**;3:45-50
 11. Shapiro R. Inflammatory lesions. In: Shapiro R, ed. *Myelography*, 4th ed. Chicago: Year Book Medical, **1984**;282-317
 12. Lombardi G, Passerini A, Migliavacca F. Spinal Arachnoiditis. *Br J Radiol* **1962**;35:314-320
 13. Marinesco G, Draganesco S, Hornet T. Contribution a l'etude de l'arachnoid spinale. *Rev Neurol* **1934**;3:321-341
 14. Teplick JG, Haskin ME. Intravenous contrast-enhanced CT of the postoperative lumbar spine: improved identification of recurrent disk herniation scar, arachnoiditis and diskitis. *AJNR* **1984**;5:373-383
 15. Firooznia H, Kricheff II, Rafii M, Golimbu C. Lumbar spine surgery: examination with intravenous contrast-enhanced CT. *Radiology* **1987**;163:221-226
 16. Jorgensen J, Hansen PH, Steenskov V, Ovesen N. A clinical and radiological study of chronic lower spinal arachnoiditis. *Neuroradiology* **1975**;9:139-144