

Generic Contrast Agents

Our portfolio is growing to serve you better. Now you have a *choice*.



[VIEW CATALOG](#)

AJNR

Contrast-enhanced MR imaging of tuberculous pachymeningitis cranialis hypertrophica: case report.

J Callebaut, D Dormont, B Dubois, J Chiras and J Bories

AJNR Am J Neuroradiol 1990, 11 (4) 821-822

<http://www.ajnr.org/content/11/4/821.citation>

This information is current as
of May 12, 2025.

Contrast-Enhanced MR Imaging of Tuberculous Pachymeningitis Cranialis Hypertrophica: Case Report

J. Callebaut,¹ D. Dormont,² B. Dubois,¹ J. Chiras,² and J. Bories²

Over the past 30 years, sequelae and mortality due to tuberculous meningitis have failed to decrease [1]. The most likely explanation is that the diagnosis of tuberculous meningitis is generally made on the basis of clinical and CSF findings, which come late in the course of the disease. In some cases, however, and especially in pachymeningeal forms with atypical clinical features, neuroradiologic investigations can be very useful in early diagnosis of this disease, as the present case demonstrates.

Case Report

A 56-year-old man was first seen in November 1987 for evaluation of a 2-month history of progressively increasing left-sided headache, subacute left palpebral edema, discrete ptosis, paresthesia in the territory of the ophthalmic nerve, and diplopia since October.

Clinical examination showed involvement of the left ophthalmic nerve with corneal hypoesthesia, the left abducens nerve, and the left oculomotor nerve. There was no anisocoria. The pupillary responses and the fundi were normal. Left exophthalmos was noted with minor palpebral inflammation. General examination was negative. At the time of admission the patient was afebrile.

CSF was clear, and repeated analysis showed no lymphocytes, no malignant cells, and normal protein and glucose levels. All cultures and smears were negative, as was the VDRL. Tuberculin test was positive. Radiologic examination of the thorax showed calcifications at the left apex without any progressive tuberculous lesions. Standard radiography and tomography of the orbits failed to show any bone lesion or evidence of tumor invasion.

CT was performed in October 1987 with contrast injection and was initially considered normal. However a more in-depth retrospective analysis showed left exophthalmos and greater contrast enhancement of the external wall of the left cavernous sinus compared with the right. A control, contrast-enhanced CT scan (Fig. 1), obtained 1 month later, showed more pronounced extension through the superior orbital fissure. In addition, there was involvement of the optic nerve and the internal and external rectus muscles as well as suspected extension from the wall of the left cavernous sinus to a part of the temporal lobe convexity. Left carotid arteriography showed no opacification on the venous phase of the left cavernous sinus.

MR imaging without and with gadopentetate dimeglumine (Fig. 2) was performed the day after the second CT examination. All images

were T1-weighted. The contrast-enhanced sequences showed enhancement of the lateral wall of the left cavernous sinus, which not only extended intraorbitally but also over the left frontal and temporal lobes and even over a small part of the parietal convexity. The images obtained without contrast showed only minor signal anomalies of the cavernous sinus and orbital fissure. The MR findings prompted a biopsy of the left frontotemporal dura 3 months after onset of symptoms. Pathologic examination showed fibrous tissue with micronodular inflammation formed of epitheliogigantocellular follicles. At the center there was a caseous necrosis that was surrounded by lymphoid cells. The diagnosis of follicular caseous tuberculosis was confirmed and triple antituberculous treatment was initiated. The course was favorable and clinical examination was normal 5 months after onset of therapy. A control MR image obtained with gadopentetate dimeglumine (Fig. 3) 11 months after antituberculous therapy showed lesion regression. Only a small signal asymmetry of the left temporal and frontal convexity still persisted.

Discussion

Our patient presented with a progressive clinical syndrome of the left superior orbital fissure of unknown origin. CT evaluation, initially considered normal, showed slight anomalies of the cavernous sinus wall and of the superior orbital fissure upon closer examination. These findings were not specific and several differential diagnoses were considered, including meningioma en plaque, dural carcinomatosis [2], neurosarcoidosis [3–5], syphilis [6, 7], tumor [8, 9], lymphoma [10], and idiopathic progressive leptomeningeal fibrosis. Only

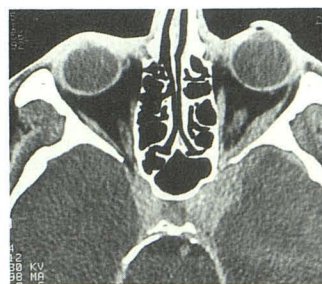


Fig. 1.—Contrast-enhanced CT scan 2 months after symptom onset. Contrast enhancement of wall of left cavernous sinus with extension intraorbitally is shown, as well as possible extension to the temporal convexity. Mild exophthalmos can also be seen.

Received July 23, 1989; revision requested August 29, 1989; revision received October 2, 1989; accepted October 11, 1989.

¹ Department of Neurology, La Salpêtrière Hospital, Paris, France.

² Department of Neuroradiology, La Salpêtrière Hospital, 47 Bd de l'Hôpital, 75634 Paris, Cedex 13, France. Address reprint requests to D. Dormont.

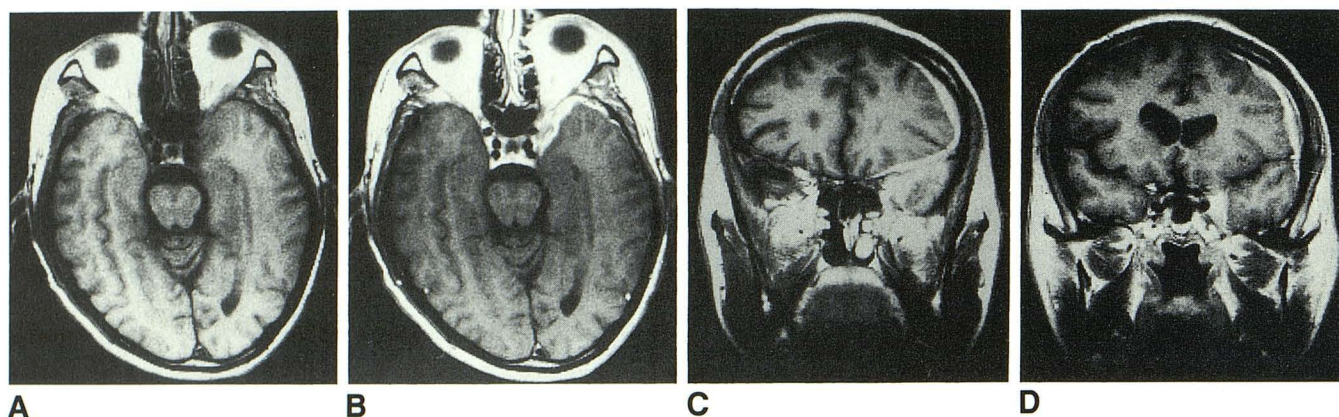


Fig. 2.—A, T1-weighted axial MR image (400/21) without contrast 2 months after symptom onset shows only asymmetry of left cavernous sinus. B, T1-weighted axial MR image (400/21) after injection of gadopentetate dimeglumine shows large extension to temporal convexity. C and D, T1-weighted coronal MR images (400/21) show large extension to frontal and temporal convexities.

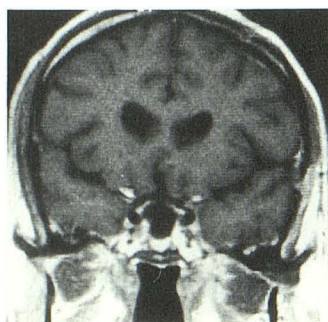


Fig. 3.—Coronal contrast-enhanced MR image 11 months after onset of treatment shows only minor signal anomalies over the left frontal convexity.

gadopentetate-dimeglumine-enhanced MR imaging made it possible to visualize the large extent of the lesions [11], which were not seen on CT 2 months after onset. The MR findings led to biopsy of the lesion, which in turn led to earlier diagnosis and treatment.

Prognosis of tuberculous meningitis and the prevention of severe sequelae have not greatly improved over the last 30 years [1]. To see improvement in these areas the disease must be diagnosed earlier than is generally done at present. In a review of the literature [12] we found an average delay of 2 months between the appearance of pathologic CT images and the onset of clinical signs. Consequently, MR appears to be much more effective than CT in making an early diagnosis. Moreover, until now no good means of a follow up of the course of tuberculous meningitis with treatment has been found [1, 13]. MR with gadopentetate dimeglumine allowed

us to monitor the decrease in lesion extent during treatment, and this corresponded well with clinical improvement.

REFERENCES

1. Abdolghader Molavi, Le Frock JL. Tuberculous meningitis. *Med Clin North Am* 1985;69:315-331
2. Tyrrell II RL, Bundschuh CV, Modic MT. Dural carcinomatosis: MR demonstration. *J Comput Assist Tomogr* 1987;11:329-332
3. Leeds NE, Zimmerman RD, Elkin CM, Nussbaum M, Le Van AM. Neurosarcoidosis of the brain and meninges. *Semin Roentgenol* 1985;20:387-392
4. Hovda E, Wall M, Numaguchi Y, Varma DGK. Neurosarcoidosis involving optic nerves and leptomeninges: computed tomography findings. *J Comput Tomogr* 1986;10:129-133
5. Heaton EB, Zito G, Chamhan P, Benst JCM. Intracranial subdural sarcoid granuloma. *J Neurosurg* 1982;56:728-731
6. Moore AP, Rolfe EB, Jones EL. Pachymeningitis cranialis hypertrophica. *J Neurol Neurosurg Psychiatry* 1985;48:942-944
7. Hassin GB, Zeitlin H. Syphilitic cerebral hypertrophic pachymeningitis. *Arch Neurol* 1940;43:362-374
8. Boyle R, Thomas M, Hume AJ. Diffuse involvement of the leptomeninges by tumour: clinical and pathological study of 63 cases. *Postgrad Med J* 1980;56:149-158
9. Enzmann DR, Krikorian J, Yorke C, Hayward R. Computed tomography in leptomeningeal spread of tumors. *J Comput Assist Tomogr* 1978;2:448-455
10. Pagani JJ, Libshitz IH, Wallau S, Hayman LA. Central nervous system leukemia and lymphoma. *AJNR* 1981;2:397-403
11. Brant-Zawadzki M. MRI of the brain. *Radiology* 1988;166:1-10
12. Bonafé A, Manelfe C, Gomez MC, et al. Tuberculous meningitis. *J Neuro-radiol* 1985;12:302-316
13. Rovito M, Romero F, Torrent O, Ibarra B. Study of tuberculous meningitis by CT. *Neuroradiology* 1980;19:137-140