



Get Clarity On Generics

Cost-Effective CT & MRI Contrast Agents



FRESENIUS
KABI

WATCH VIDEO

AJNR

Cocaine- and methamphetamine-induced acute cerebral vasospasm: an angiographic study in rabbits.

A M Wang, J N Suojanen, V M Colucci, C L Rumbaugh and N K Hollenberg

This information is current as
of August 30, 2025.

AJNR Am J Neuroradiol 1990, 11 (6) 1141-1146
<http://www.ajnr.org/content/11/6/1141>

Cocaine- and Methamphetamine-Induced Acute Cerebral Vasospasm: An Angiographic Study in Rabbits

A-M Wang^{1,2}
J. N. Suojanen^{1,3}
V. M. Colucci¹
C. L. Rumbaugh¹
N. K. Hollenberg¹

Stroke is a frequently reported, though uncommon, complication of drug abuse, primarily cocaine. The pathogenesis is uncertain, although such cerebrovascular events may result from sympathetically mediated vasoconstriction of cerebral vessels. Amphetamine, another sympathomimetic amine that is commonly abused, may also cause strokes by producing cerebral vasospasm and/or vasculitis. Amphetamine and its derivatives are frequent adulterants of illegally obtained cocaine and may also be used concurrently; the effect(s) of this combination of drugs upon the cerebral vasculature is not known. Our aim was to develop an animal model that would enable us to study the ability of these drugs to produce acute cerebral vasospasm and to observe the response to IV administration of amphetamine and cocaine, either alone or together.

Magnified basilar artery arteriograms were obtained in 12 New Zealand white rabbits before and after IV administration of cocaine, methamphetamine, or both, at various dosages. Low doses produced mild vasodilatation. At higher doses, the animals who received cocaine and methamphetamine alone showed little or no basilar artery spasm, but coadministration produced definite basilar artery vasospasm, reflecting a synergistic vasoconstrictive effect. If a similar response exists in the human cerebral vasculature, then this could help explain the cause of strokes associated with drug abuse.

AJNR 11: 1141–1146, November/December 1990

By 1985, lifetime prevalence of cocaine use was over 22 million, and current prevalence is nearly 6 million [1, 2]. Additionally, the average dose has tripled to 1–3 g/week, with more frequent administration by the IV route and by smoking of the freebase alkaloid form, crack, which produces plasma levels three to four times higher than levels obtained via intranasal administration [1–6]. Along with these changes have come increased reports of medical complications [1, 2, 6, 7]. From 1981 to 1985, nonfatal emergencies and fatalities associated with cocaine abuse increased threefold [1]. Among those medical problems temporally related to cocaine abuse are cerebral vascular accidents (CVAs), including strokes and intracerebral and subarachnoid hemorrhages [2, 4, 8–15]. The rate of occurrence of cocaine-related CVAs is unknown, but clearly they represent a frequently reported though uncommon medical complication.

The cause of these CVAs is also unknown. In some patients, hemorrhage from a cerebral vascular anomaly (e.g., arteriovenous malformation or aneurysm) seems to be precipitated by cocaine-induced systemic hypertension [2, 9, 10]. In patients with no underlying anomaly, the arteriogram may be normal or may show diffuse vasospasm [8, 9, 12]. This vasospasm might be sympathetically mediated, induced by cocaine's blockade of norepinephrine reuptake at appropriate perivascular adrenergic nerve terminals, which does occur in the peripheral circulation [2, 4, 8, 9, 16]. Amphetamine, which is both a common adulterant of cocaine [2–4, 17] and a concurrent drug of abuse [2, 17–21], can also produce both acute CVAs and vasoconstriction [18, 22–28]. Although this may also be sympathetically mediated, amphetamine acts by inducing release of norepinephrine from the presynaptic adrenergic nerves and by some direct effects postsynaptically [19, 30]. Thus,

Received March 12, 1990; revision requested April 25, 1990; revision received June 14, 1990; accepted July 3, 1990.

Presented at the annual meeting of the American Society of Neuroradiology, Chicago, May 1988.

¹ Department of Radiology, Brigham and Women's Hospital, Harvard Medical School, Boston, MA 02125.

² Department of Diagnostic Radiology, William Beaumont Hospital, Royal Oak, MI 48072.

³ Present address: Department of Diagnostic Radiology, New England Deaconess Hospital, 185 Pilgrim Rd., Boston, MA 02215. Address reprint requests to J. N. Suojanen.

0195-6108/90/1106-1141

© American Society of Neuroradiology

because of their different pharmacologic mechanisms, coadministration of these two drugs might produce a synergistic effect at the adrenergic synapses, which help regulate cerebral blood vessel tone, and result in vasospasm.

We sought to develop an animal model to determine whether either drug alone or a combination of the two drugs could produce acute cerebral vasospasm. Since vasospasm is commonly assessed angiographically, this seemed the most appropriate means of initial evaluation. Further, since the rabbit cerebral vessels have rich, sympathetic perivascular innervation similar to that in humans, it seemed a reasonable species to use in developing this model [31, 32]. To see whether a dose-response relationship existed, incremental doses were used up to cumulative doses near the lethal dose for this vertebrate species [16].

Materials and Methods

Thirty-one New Zealand white rabbits of either sex weighing 3.8–4.3 kg were anesthetized with pentobarbital IV and a tracheostomy was performed. A 4-French catheter was then placed in a femoral artery for blood pressure monitoring and blood gas sample collection, and another into a femoral vein for drug administration. The other femoral artery was cannulated by a 4-French sheath through which a 3-French catheter was selectively placed in the left vertebral artery. Iohalamate meglumine (Conray 60, Mallinckrodt Medical, St. Louis) was injected at 2 ml/sec for a total volume of 3 ml. Arteriograms were performed as a baseline and then 5 min after administration of each drug; arteriograms of the basilar artery were obtained at $\times 10$ magnification. At the conclusion, animals were destroyed by IV administration of pentobarbital and potassium chloride. All animals were treated in compliance with NIH and Harvard University guidelines.

Cocaine hydrochloride at various dilutions was administered intravenously in log-dose increments of 0.1, 0.3, 0.7, 1.0, 3.0, and 7.0 mg/kg; for a cumulative dose of 12.1 mg/kg. Methamphetamine, a commonly abused amphetamine, was administered in a similar manner. Because of the time required for processing the angiographic runs and their initial evaluation, the time between doses averaged 15 min. The lethal dose for IV cocaine in rabbits is 15 mg/kg [16], so the cumulative dose was kept below this level. No data exist for methamphetamine, but the animals showed much less physiologic instability (i.e., arrhythmias, change in systemic blood pressure, change in respiratory rate) when given similar doses. When both drugs were administered simultaneously, cocaine was usually given first, followed by methamphetamine to cumulative doses of 7 mg/kg each, giving total doses of sympathomimetic drugs of 14 mg/kg, similar to levels achieved with either drug alone. Higher doses were then administered, especially when spasm was observed, to determine (1) if a dose-response relationship existed and (2) tolerance to these higher dose levels. A single bolus injection of 12.1 mg/kg was given to one animal, respectively, of each drug alone or the combination.

Blood gas levels were obtained for four animals prior to drug injection and at intervals during the experiment. These showed no significant variation in $p\text{CO}_2$, pH, $p\text{O}_2$, or hematocrit during the procedure. Three animals were monitored continuously throughout the experiment by an end expiratory $p\text{CO}_2$ monitor (Ohmeda; Englewood, CO); no significant variation (>5 mm $p\text{CO}_2$) was observed during the monitored period. Body temperature was monitored rectally and maintained at $38^\circ\text{C} \pm 1^\circ\text{C}$ by heat lamp. Blood pressure was monitored continuously, and EKGs were monitored in 16 animals.

All these physiologic parameters, especially $p\text{CO}_2$, have significant effects on cerebral blood flow and vessel diameter because of autoregulatory responses [33]. Their stability during experiments was therefore essential for attributing observed blood vessel diameter changes to drug administration.

Angiograms were evaluated for spasm by two separate observers. Control arteriograms were reviewed simultaneously with arteriograms obtained after drug administration, with the observer blinded as to the drug and its dosage. The basilar artery was evaluated for the presence of dilatation or constriction and a level of certainty was assigned, ranging from high certainty that no change had occurred through increasing degrees of confidence that spasm or dilatation was present. Disagreements between observers of greater than 1 point occurred in eight cases, which were then submitted to a third observer and resolved by consensus. Statistical significance was assessed by the Fisher exact test.

Nineteen animals were not included in the results. Of these, eight animals received chlorpromazine as a preanesthetic agent and their arteriograms showed no variation. Since this drug is a potent alpha antagonist, use of this agent was discontinued. Four animals died during induction of anesthesia; three animals developed cardiac arrhythmias and sustained systemic hypotension (25 mm Hg fall in mean arterial pressure) after cocaine administration; two animals suffered respiratory arrest after receiving supplemental doses of pentobarbital; one animal had a seizure after cocaine administration; and one animal had vasospasm on the initial, control angiogram. Of the 12 animals reported, four had intermittent blood gas monitoring during the experiment and one had continuous expiratory $p\text{CO}_2$ monitoring.

Administration of the drugs paradoxically caused mild systemic hypotension (10–20 mm Hg), which returned to normal within 2 min. Blood pressure at the time of contrast injection was the same as before drug administration, so the observed spasm was not thought to be the result of autoregulatory responses.

Results

Figures 1 through 3 show representative angiographic images. The results are summarized in Table 1. As all monitored physiologic parameters were stable during the experiment, the observed changes are secondary drug effects rather than purely autoregulatory responses. Low doses of both cocaine and methamphetamine, employed alone or in combination, seemed to induce modest dilatation of the basilar artery in every rabbit (Table 1 and Fig. 2). The dilatation was lost with increasingly higher doses.

When high doses of cocaine or amphetamine were employed alone, basal artery spasm occurred in only three of eight rabbits, and was always at the lowest level of certainty, whether the high dose was achieved through incremental doses or a single high dose. When a combination of cocaine and methamphetamine was employed, every animal responded with evident basilar artery spasm ($p = .04$). Indeed, the only responses rated as 2+ or 3+ in the blinded evaluation occurred with the high dose combination ($p = .015$). Interestingly, the spasm appeared at combined totals of the two drugs of 10 mg/kg or less in two animals receiving the combined drugs incrementally, suggesting a nonadditive or synergistic effect.

Fig. 1.—A and B, Frontal views of basilar artery (arrows) in a rabbit before (A) and after (B) IV administration of 12 mg/kg of cocaine. No vascular changes were observed.

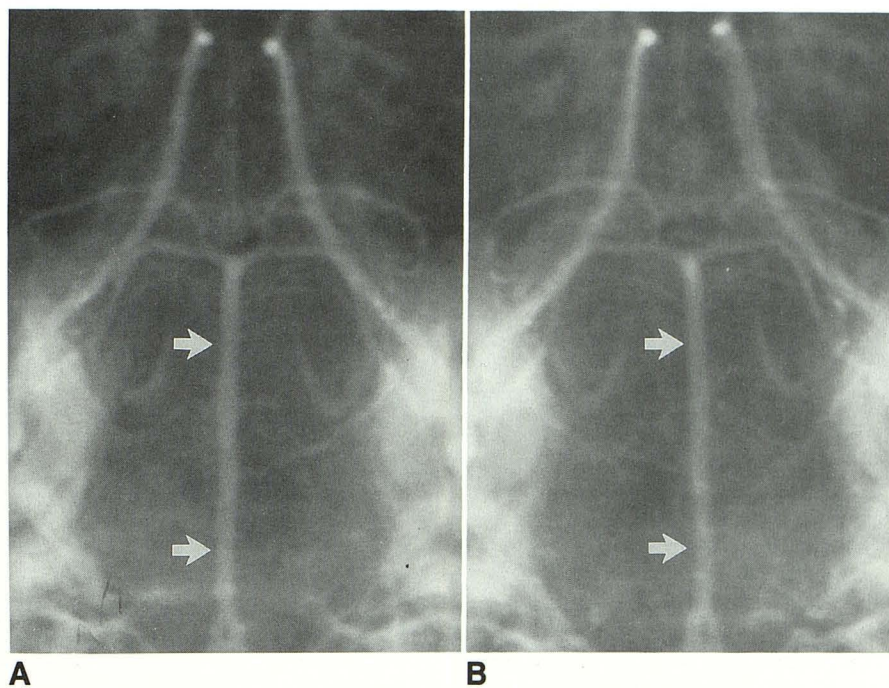
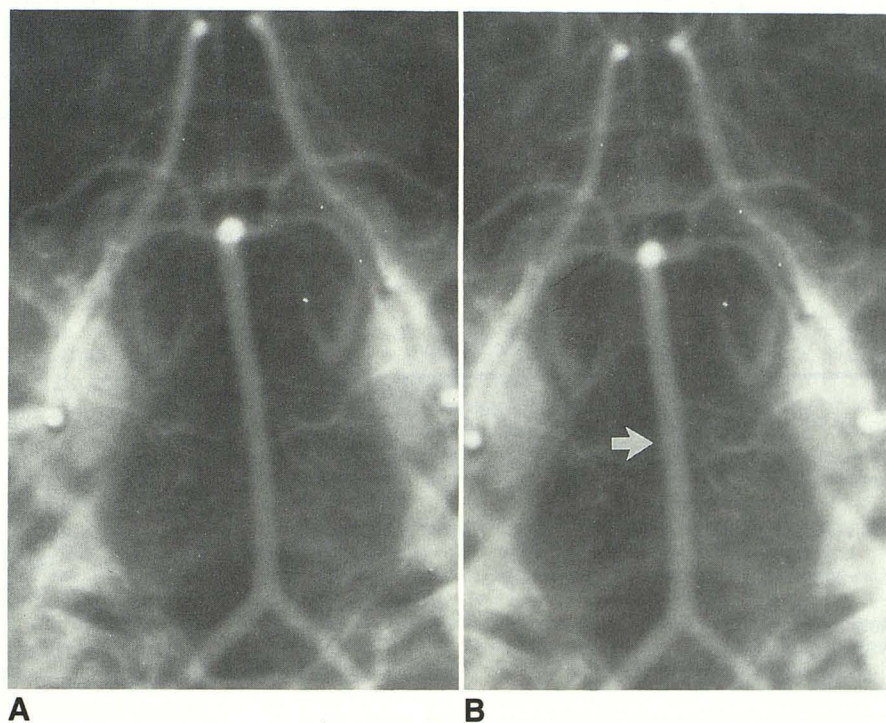


Fig. 2.—Frontal views of basilar arteriogram in a rabbit after incremental dosages of cocaine and methamphetamine.

A, Control study.
B, Mild dilatation (arrow) after 1 mg/kg of each drug.



Discussion

Both cocaine and amphetamine can produce cerebral vascular spasm clinically. Cocaine is well known for its intense local vasoconstrictive effects when applied topically [2, 3, 16]. In vitro, cocaine potentiates the contraction of cat and rat cerebral arteries exposed to physiologic concentrations of

norepinephrine [34, 35]. Studies of four patients with acute CVA after cocaine use reported angiographic findings of vasospasm [8, 12, 15]. Position emission tomography (PET) scans have shown diminished prefrontal cortical blood flow in human chronic cocaine abusers [36]. Amphetamine administration produced vasospasm [23] and diminished cerebral blood flow at high doses [37] in baboons. In this respect, our

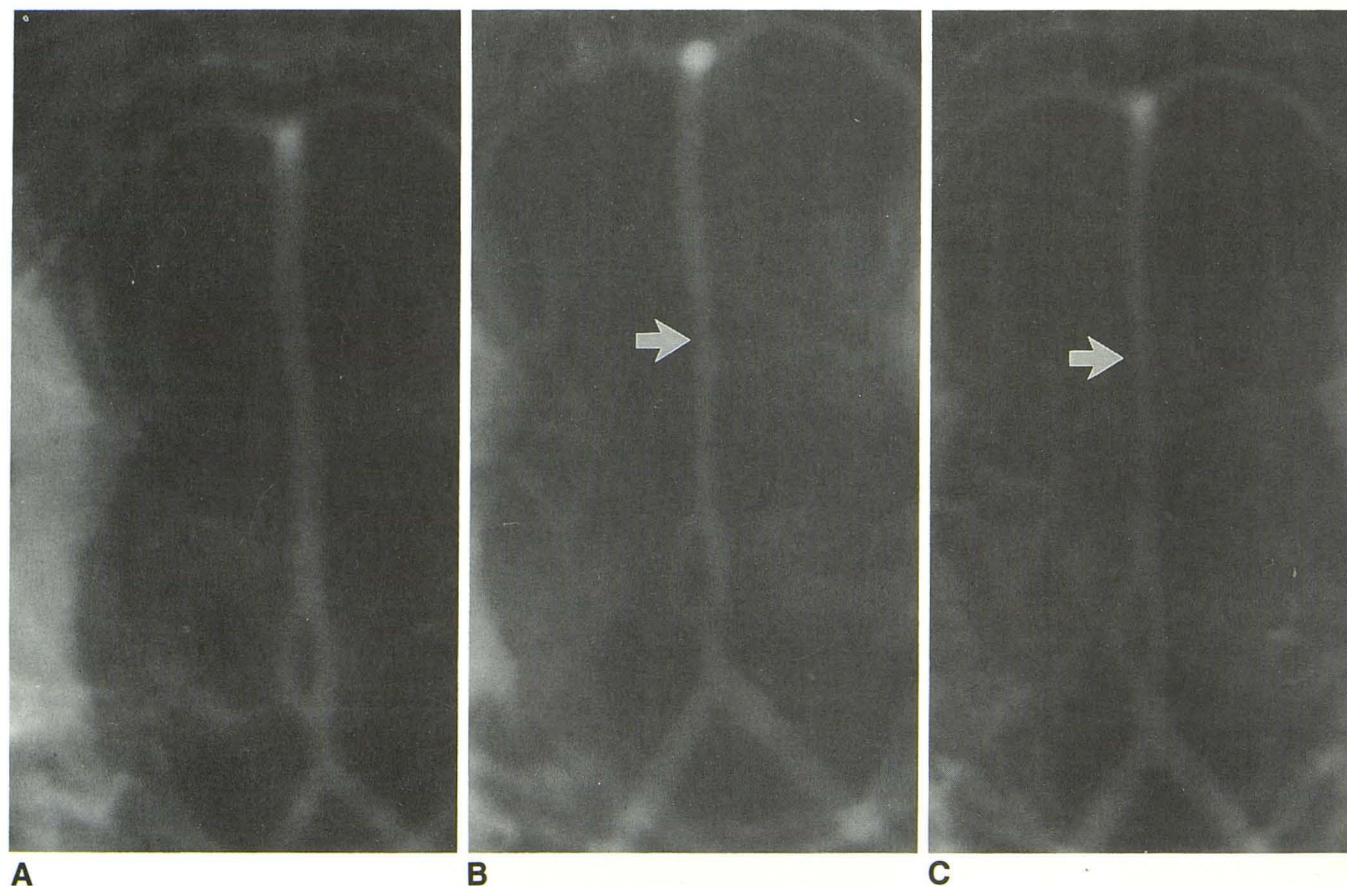


Fig. 3.—Frontal views of basilar arteriogram in a rabbit after incremental dosages of cocaine and methamphetamine.
 A, Control study.
 B, Moderate basilar artery spasm (arrow) after incremental dosages of 3 mg/kg of each drug.
 C, Severe basilar artery spasm (arrow) after incremental dosages of 7 mg/kg of each drug.

TABLE 1: Record of Angiographic Observations

Drug Treatment	Basilar Artery Dilatation	Basilar Artery Spasm
Cocaine alone		
Single high dose ($n = 1$)	—	—
Incremental doses ($n = 3$)		
Low dose	+ (3)	— (3)
High dose	— (3)	+ (2)
		— (1)
Methamphetamine alone		
Single high dose ($n = 1$)	—	—
Incremental doses ($n = 3$)		
Low dose	+ (3)	— (3)
High dose	— (3)	+ (1)
		— (2)
Combination		
Single high dose ($n = 1$)	—	+
Incremental doses ($n = 3$)		
Low dose	+ (3)	— (3)
High dose	— (3)	+++ (1)
		++ (1)
		+ (1)

Note.—Number of +’s represents degree of confidence relative to control arteriogram that dilatation or spasm was present; numbers in parentheses represent the number of animals; — = no change from control arteriogram.

results seem puzzling because high doses of either drug alone showed little tendency to produce spasm.

Perhaps our results are not unexpected. Since the rabbit basilar artery appears fairly resistant to norepinephrine-induced contraction, and its adrenergic response is not affected by the presence of cocaine [32], circulating cocaine may have little effect upon this vessel. Lee et al. [38] suggest that the endogenous norepinephrine releasable from sympathetic nerves in the rabbit basilar artery is insufficient to produce vasoconstriction. Amphetamine administration causes increased cerebral blood flow in many species [39–42], and this could account for our observation of vasodilatation at low doses. Increased blood flow might tend to inhibit the development of vasospasm because of some autoregulatory response. Additionally, many people use cocaine, yet few have acute, symptomatic cerebrovascular events. Many of those who do have an underlying cerebral vascular anomaly [2, 9, 10, 15]. Some authors [25, 26] have suggested an immune-mediated vasculitis as the cause of acute cerebrovascular events, akin to that seen with amphetamine abuse [18, 22, 23, 27–29]. The short exposure our animals had to the drugs would not allow them to develop an immune-mediated response. Further, the diagnosis of cocaine-associated cerebral

vasculitis is quite specious in that there was no pathologic proof in either case cited above, and, despite enormous numbers of users, no other cases have come to light.

Coadministration of the drugs apparently produces a synergistic response. Amphetamine is generally regarded as an indirectly acting sympathomimetic [19]; that is, it exerts its effects by entering the presynaptic nerve terminal, causing the release of norepinephrine at presynaptic nerve terminals. With coadministration, this increased release would be accompanied by a cocaine-induced decrease in the reuptake at presynaptic nerve terminals. Intrasympathetic norepinephrine concentrations might then become sufficiently high to produce neuronal transmissions that result in vascular smooth muscle contraction (i.e., spasm). Alternatively, tyramine, an indirect-acting sympathomimetic closely related to amphetamine, has a direct effect upon rabbit basilar artery perivascular postsynaptic adrenergic nerve endings [38]. If methamphetamine had a similar effect, then the vasoconstrictive effects of elevated endogenous norepinephrine produced by cocaine blockage of reuptake could be augmented by methamphetamine's direct adrenergic actions. A combination of mechanisms could also be operative.

Is this model valuable clinically? Our results suggest that some CVAs temporally related to cocaine abuse may result from cerebral vasospasm induced by intentional or inadvertent coadministration of an amphetamine derivative. This may be a common event on the street [2-4, 17-21]. Although Olsen and Rowley [26] found no amphetamine in 12 of 16 patients with cocaine-related CVAs, the usual screening test for amphetamine involves urine samples and is often limited owing to cross reactivity [43]. Because it is less sensitive than serum measurements and can become negative before similar cocaine measurements, the urinary test may also be falsely negative [43-45]. In vitro experiments suggest that numerous other drugs, including alcohol, may produce cerebral vasospasm [46, 47]. Given that cocaine is a potent vasoconstrictor elsewhere, it is probably capable of producing similar effects within the cerebral vessels. However, since cocaine produces an increase in cerebral blood flow, autoregulatory demands may preclude vasoconstriction unless other factors are present; for example, other drugs, such as methamphetamine. Obviously, further work must be done to validate this model, determine its clinical utility, and study both the long- and short-term effects on the cerebral vasculature of cocaine, methamphetamine, and other drugs of abuse.

ACKNOWLEDGMENTS

We thank Patricia Egan and Ohmeda Corporation for the use of their capnography equipment.

REFERENCES

- Kozel NJ, Adams EH. Epidemiology of drug abuse: An overview. *Science* 1986; 234:907-974
- Johanson CE, Fischman MW. The pharmacology of cocaine related to its abuse. *Pharmacol Rev* 1989; 41:3-52
- Van Dyck C, Byck R. Cocaine. *Sci Am* 1982; 246:128-141
- Adams EH, Durell J. Cocaine: a growing public health problem. In: Grabowski J, ed. *Cocaine: pharmacology, effects, and treatment of abuse*. NIDA Research Monograph 50. DHHS Pub. No. (ADM) 84-1326, Washington, DC: U.S. Govt. Printing Office, 1984; 9-14
- Washton AM, Gold MS, Pottash AC. The 800-cocaine helpline: survey of 500 callers. In: Harris LS, ed. *Problems of drug dependence, 1984. Proceedings of the 46th annual scientific meeting*. The Committee on Problems of Drug Dependence, Inc., Washington, DC: U.S. Government Printing Office, 1985: 224-230
- Isner JM, Estes NAM III, Thompson PD, et al. Acute cardiac events temporally related to cocaine abuse. *N Engl J Med* 1986; 315:1438-1443
- Rogers JN, Henry TE, Jones AM, Froede RC, Byers JM III. Cocaine-related deaths in Pima County, Arizona, 1982-1984. *J Forensic Sci* 1986; 31:1404-1408
- Golbe LI, Merkin MD. Cerebral infarction in a user of free-base cocaine ("crack"). *Neurology* 1986; 36:1602-1603
- Wojak JC, Flamm ES. Intracranial hemorrhage and cocaine use. *Stroke* 1987; 18:712-715
- Lichtenfeld PJ, Rubin DB, Feldman RS. Subarachnoid hemorrhage precipitated by cocaine snorting. *Arch Neurol* 1984; 41:223-224
- Chasnoff IJ, Bussey ME, Savich R, Stack CM. Clinical and laboratory observations. Perinatal cerebral infarction and maternal cocaine use. *J Pediatr* 1986; 108:456-459
- Levine SR, Washington JM, Moen M, Kieran SN, Sly J, Welch KMA. Crack-associated stroke (letter to the editor). *Neurology* 1987; 37:1092-1093
- Tuchman AJ, Daras M, Zalzal P, Mangiardi J. Intracranial hemorrhage after cocaine abuse (letter to the editor). *JAMA* 1987; 257:1175
- Schwartz KA, Cohen JA. Subarachnoid hemorrhage precipitated by cocaine snorting (letter to the editor). *Arch Neurol* 1984; 41:705
- Jacobs IG, Roszler MH, Kelly JK, Klein MA, Kling GA. Cocaine abuse: neurovascular complications. *Radiology* 1989; 170:223-227
- Van Dyck C, Byck R. Cocaine 1884-1974. In: Ellinwood EH Jr, Kilbey MM, eds. *Cocaine and other stimulants*. New York: Plenum Press, 1977: 1-30
- Siegel RK. New trends in drug use among youth in California. *Bull Narc* 1985; 37:7-17
- Bostwick D. Amphetamine induced cerebral vasculitis. *Hum Pathol* 1981; 12:1031-1033
- Weiner N. Norepinephrine, epinephrine, and the sympathomimetic amines. In: Gilman AG, Goodman LS, Rall TW, Murad F, eds. *The pharmacological basis of therapeutics*. New York: Macmillan, 1985:145-180
- Mule SJ. The pharmacodynamics of cocaine abuse. *Psychiatr Ann* 1984; 14:724-727
- Newcomb MD, Bentler PM. Cocaine use among adolescents: longitudinal associations with social context, psychopathology, and use of other substances. *Addict Behav* 1986; 11:263-273
- Rumbaugh CL, Bergeron RT, Fang HCH, McCormick R. Cerebral angiographic changes in the drug abuse patient. *Radiology* 1971; 101:335-344
- Rumbaugh CL, Bergeron RT, Scanlan RL, et al. Cerebral vascular changes secondary to amphetamine abuse in experimental animals. *Radiology* 1971; 101:345-351
- Berglund M, Risberg J. Regional cerebral blood flow in a case of amphetamine intoxication. *Psychopharmacology* 1980; 70:219-221
- Kaye BR, Fainsfat M. Cerebral vasculitis associated with cocaine abuse. *JAMA* 1987; 258:2104-2105
- Olsen WL, Rowley HA. Neuroradiology of cocaine abuse. Presented at the twenty-sixth annual meeting of the American Society of Neuroradiology, Chicago, May 1988
- Caplan LR, Hier DB, Banks G. Current concepts of cerebrovascular disease-stroke: stroke and drug abuse. *Stroke* 1982; 13:869-872
- Rumbaugh CL. Small vessel cerebral vascular changes following chronic amphetamine intoxication. In: Ellinwood EH Jr, Kilbey M, eds. *Cocaine and other stimulants*. New York: Plenum Press, 1977: 241-251
- Leeds NE, Malhotra V, Zimmerman RD. The radiology of drug addiction affecting the brain. *Semin Roentgenol* 1983; 18:227-233
- Jaffe J. CNS sympathomimetics: amphetamine, cocaine and related drugs. In: Gilman AG, Goodman LS, Rall TW, Murad F, eds. *The pharmacologic basis of therapeutics*. New York: Macmillan, 1985: 550-554
- Edvinsson L, Owman C, Suoberg N-O. Autonomic nerves, mast cells, and amine receptors in human brain vessels. A histochemical and pharmacological study. *Brain Res* 1976; 115:377-393
- Duckles SP, Bevan JA. Pharmacological characterization of adrenergic

- receptors of a rabbit cerebral artery in vitro. *J Pharmacol Exp Ther* **1976**; 197:371-378
33. Winn HR, Dacey RGI, Mayberg MR. Cerebral circulation. In: Paton HD, Fuchs AE, Hille B, Scher AM, Steiner R, eds. *Textbook of physiology*. Philadelphia: Saunders, **1989**; 952-960
34. Edvinsson L, Aubineau P, Owman C, Sercombe R, Seylaz J. Sympathetic innervation of cerebral arteries: prejunctional supersensitivity to norepinephrine after sympathectomy or cocaine treatment. *Stroke* **1975**; 6: 525-530
35. Hirst GDS, Neild TO, Silverberg GD. Noradrenaline receptors on the rat basilar artery. *J Physiol* **1982**; 328:351-360
36. Volkow ND, Mullani N, Gould KL, Adler S, Krajewski K. Cerebral blood flow in chronic cocaine users: a study with positron emission tomography. *Br J Psychol* **1988**; 152:641-648
37. McCulloch J, Deshmukh VD, Harper AM. Indirect sympathomimetics and cerebral blood flow and metabolism. *Acta Neurol Scand* **1977**; 56(Suppl 64):94-95
38. Lee TJF, Araki H, Su C. Tyramine-induced contractions in the rabbit ear and basilar arteries. *J Cardiovasc Pharmacol* **1981**; 3:965-976
39. Carlsson C, Hagerdal M, Siesjo BK. Influence of amphetamine sulphate on cerebral blood flow and metabolism. *Acta Physiol Scand* **1975**; 94: 128-129
40. McCulloch J, Harper AM. Cerebral circulatory and metabolism changes following amphetamine administration. *Brain Res* **1977**; 121:196-199
41. Rovere AA, Rannald AC, Scremin OU. On the mechanism of the amphetamine induced vasodilatation at the rat's cerebral cortex. *Experientia* **1977**; 33/11:1461-1463
42. Berntman L, Carlsson C, Hagerdal M, Siesjo BK. Circulatory and metabolic effects in the brain induced by amphetamine sulphate. *Acta Physiol Scand* **1978**; 102:310-323
43. Bailey DN, Shaw RF. Cocaine- and methamphetamine-related deaths in San Diego County (1987): homicides and accidental overdoses. *J Forensic Sci* **1989**; 34:407-422
44. Dixon SD. Effects of transplacental exposure to cocaine and methamphetamine on the neonate. *West J Med* **1989**; 150:436-442
45. Miller LG, Bakht FR, Baker T, Kirshon B. Possible cocaine predisposition to adverse cerebrovascular and cardiovascular sequelae of bromocriptine administered postpartum. *J Clin Pharmacol* **1989**; 29:781-785
46. Altura B, Altura BT, Gerrewold A. Alcohol-induced spasms of cerebral blood vessels: relation to cerebrovascular accidents and sudden death. *Science* **1983**; 220:331-332
47. Altura BT, Altura BM. Phencyclidine, lysergic acid diethylamide, and mesaline cerebral artery spasms and hallucinogenic activity. *Science* **1981**; 212:1051-1052