

# Generic Contrast Agents

Our portfolio is growing to serve you better. Now you have a *choice*.



FRESENIUS  
KABI

[VIEW CATALOG](#)

# AJNR

## **Treatment of arteriovenous malformations of the mandible by arterial and venous embolization.**

J Chiras, D Hassine, P Goudot, J F Meder, J F Guilbert and J Bories

*AJNR Am J Neuroradiol* 1990, 11 (6) 1191-1194

<http://www.ajnr.org/content/11/6/1191.citation>

This information is current as  
of May 15, 2025.

# Treatment of Arteriovenous Malformations of the Mandible by Arterial and Venous Embolization

J. Chiras,<sup>1</sup> D. Hassine,<sup>1</sup> P. Goudot,<sup>2</sup> J. F. Meder,<sup>3</sup> J. F. Guilbert,<sup>2</sup> and J. Bories<sup>1</sup>

High-flow arteriovenous malformations (AVMS) of the mandible, though rare, may cause death from intractable bleeding, usually following a dental extraction [1–3]. Treatment is difficult, as evidenced by the large range of therapies that have been proposed. These include repetitive embolization, embolization and/or surgical resection, and curettage [1, 4–6]. Nevertheless, some authors have described successful AVM embolization with the use of superselective catheterization in direct proximity to the nidus [3, 7, 8].

We report two cases in which arterial embolization was followed by percutaneous transmandibular occlusion of the venous drainage, producing complete disappearance of the AVM with osseous reconstruction.

## Case Reports

### Case 1

A 10-year-old girl developed arterial bleeding during surgical removal of a mandibular cyst. The bleeding was controlled by wax packing, whereupon the patient was referred to the department of facial surgery. An orthopantomograph on admission disclosed a well-delimited unilocular, radiolucent lesion of the right body of the mandible near the ramus (Fig. 1). The bone was expanded with root resorption of the first molar. MR imaging at 0.5T (Magniscan) demonstrated a complete lack of signal in the AVM on T1-weighted sequences, indicating high flow. Right external carotid arteriography showed branches of the facial, inferior dental, and lingual arteries directly feeding a large venous pouch located in the body of the mandible near the ramus, with a single inferior dental draining vein (Fig. 2).

Selective arterial embolization with particles (small pieces of dura mater) of the main feeders (internal maxillary, facial, and lingual arteries) resulted in complete devascularization of the AVM.

A control MR study showed high signal on T1- and T2-weighted sequences, corresponding to thrombosis of the AVM and the major part of the venous pouch, although a signal void remained in the draining dental vein.

MR imaging 1 month later showed increased flow void in the venous pouch. A control angiogram 1 month after that showed persistent unocclusion of the main feeders but the development of new,

small feeding arteries arising from the facial and internal maxillary arteries (Fig. 3A).

Direct percutaneous puncture of the venous pouch was performed with a 14-gauge needle under fluoroscopy. A latex balloon (Debrun no. 16) was introduced through the needle, inflated with metrizamide contrast medium, and detached. Occlusion was completed by the injection of large pieces of Gelfoam soaked in a thrombotic agent (Thrombase) during ipsilateral jugular vein compression (Figs. 3B and 3C).

A control angiogram obtained immediately after the embolization demonstrated the complete absence of arterial contribution (Fig. 3D).

The patient was followed for 1 year and had no complications or recurrence of bleeding. MR signal hyperintensity of the pouch decreased to isointensity. Reossification of the pouch and normalization of the dental germs were observed at the end of this period (Fig. 4).

### Case 2

An 8-year-old boy developed severe bleeding following extraction of his left first molar. The hemorrhage was difficult to stop by packing. An orthopantomograph showed a multilocular radiolucent lesion of the left hemimandible and widening of the left dental canal (Fig. 5A). Left external carotid arteriography revealed a high-flow AVM fed by branches of the facial and inferior dental arteries, which surrounded a venous pouch located in the body and ramus of the mandible. It drained solely via the inferior dental vein (Figs. 5B–5D).

Emergency arterial embolization of the main feeders with small particles of dura mater was incomplete (Fig. 6A). Direct percutaneous puncture of the venous pouch under fluoroscopy with a 14-gauge needle was performed a few days later. Embolization was accomplished by using large pieces of Gelfoam soaked in a thrombotic

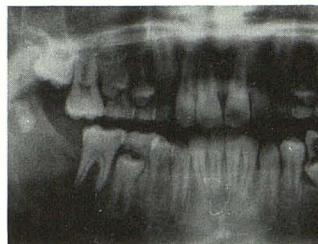

Fig. 1.—Case 1: Orthopantomograph shows large radiolucent lesion of right body of mandible near the ramus.

Received January 10, 1990; revision requested May 5, 1990; revision received July 11, 1990; accepted July 15, 1990.

<sup>1</sup> Department of Neuroradiology, Hôpital de la Salpêtrière, 47,83 boulevard de l'Hôpital, 75651 Paris, Cedex 13, France. Address reprint requests to J. Chiras.

<sup>2</sup> Department of Facial Surgery, Hôpital de la Salpêtrière, Paris, France.

<sup>3</sup> Department of Neuroradiology, Hôpital Sainte-Anne, Paris, France.

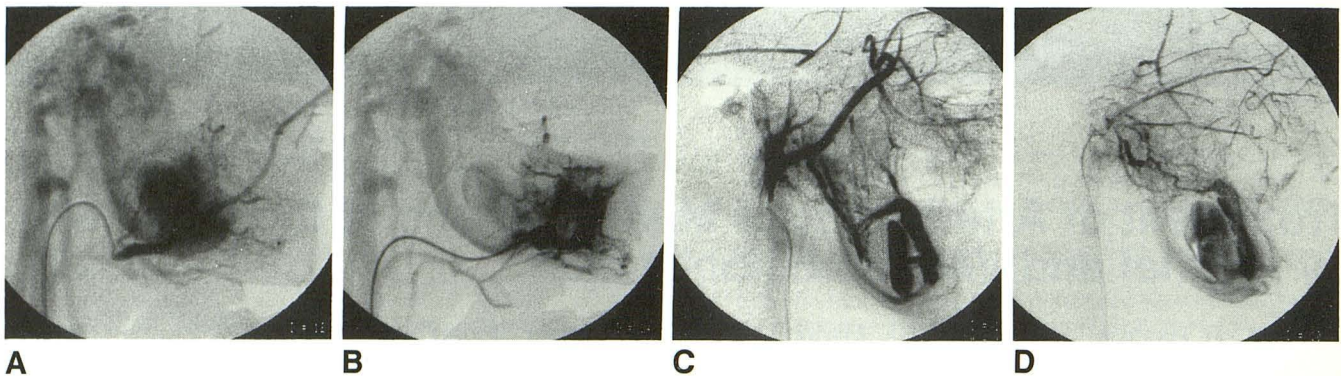


Fig. 2.—A–D, Selective angiography in case 1 confirmed the diagnosis of an arteriovenous malformation, which was fed by the facial (A), lingual (B), internal maxillary (C), and transverse facial (D) arteries. In C and D, note stagnation of contrast material in the pouch caused by prior embolization of the other feeders.

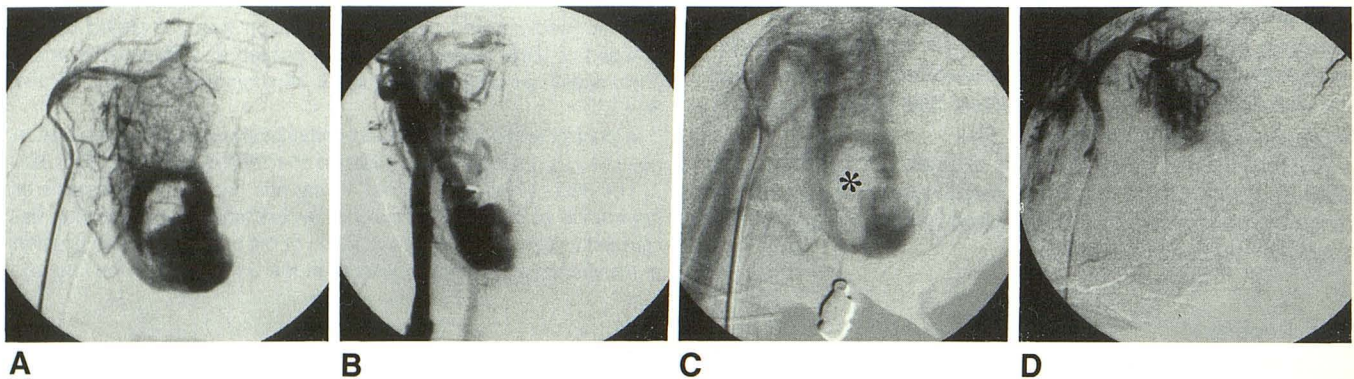


Fig. 3.—A, Control angiogram in case 1, 1 month after Fig. 2 shows persistent occlusion of main feeders but development of new small feeding arteries arising from facial and internal maxillary arteries.

B and C, Percutaneous angiogram shows opacification of venous pouch (frontal view) (B) and incomplete embolization of venous pouch after balloon detachment (asterisk).

D, Control angiogram after complete embolization of the pouch by a mixture of Gelfoam and thrombotic agents. Venous opacification completely disappeared with absence of flow in the feeding arteries.

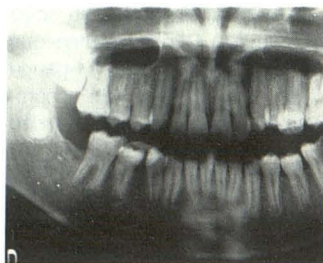


Fig. 4.—Orthopantograph in case 1 shows resolution of the lesion with reossification and normal migration of the dental germ.

agent (Thrombase) delivered through the needle during jugular vein compression (Fig. 6B). One day later, a control angiogram showed nearly complete disappearance of the AVM; the venous pouch remained slightly opacified, with extremely reduced flow and no venous drainage (Fig. 6C).

The initial hemorrhage was stopped, but periodontal hemorrhage occurred twice, 8 days and 5 months later, respectively, but each stopped spontaneously. During clinical examination, a vascular network was still visible near the second left premolar collar. An MR study 3 months after the occlusion showed high signal within the

AVM on T1-weighted sequences. At 6 months, the MR signal became heterogeneous, with isointense areas most likely corresponding to reossification, which was demonstrated on an orthopantograph (Fig. 6D).

## Discussion

The treatment of mandibular AVMs is difficult and the methods are not well defined. The goals of treatment are to stop the hemorrhage (which is the most frequent presentation) and to prevent recurrence of bleeding. Treatment should be as conservative as possible, with respect for the growth and functional role of the mandible, since these hemorrhages often occur in children.

Although many therapies have been proposed, few of them preserve the mandible, and ligation of the external carotid artery is now completely proscribed [1, 4, 9–11], for even if it stops the hemorrhage it neither treats the AVM nor prevents recurrence of bleeding, and it increases the difficulty of future treatment.

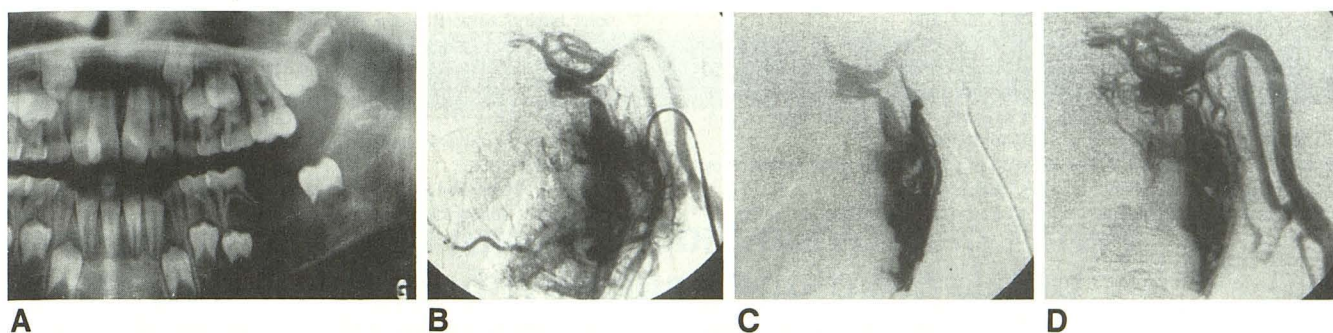


Fig. 5.—Case 2.

A, Orthopantomograph shows large radiolucent lesion involving the body and ramus of the left hemimandible.  
B–D, Selective arteriography of the facial (B) and dental (C and D) arteries shows a large arteriovenous malformation with a multilocular pouch draining into a single inferior dental vein.

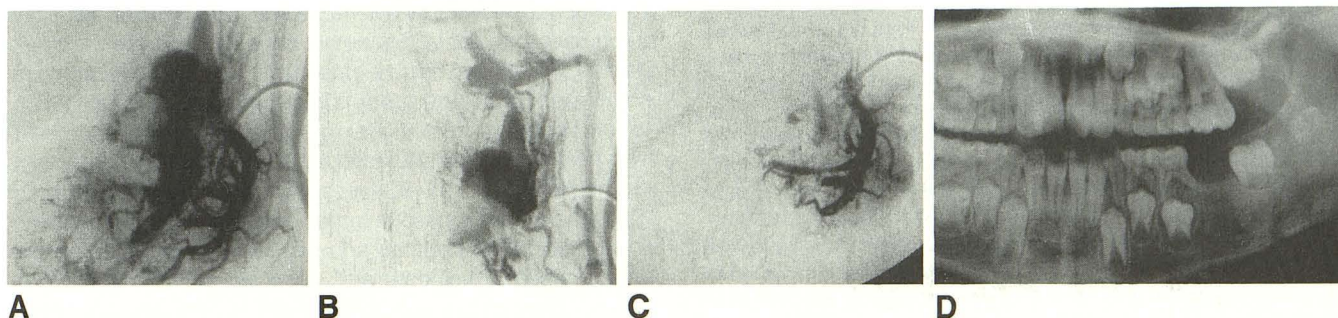


Fig. 6.—A, In same patient, selective arteriogram of the facial artery after incomplete embolization shows persistent arteriovenous malformation.

B, A few days later, percutaneous puncture of venous pouch produced direct opacification.  
C, Control angiogram of facial artery after percutaneous embolization of the pouch by a mixture of thrombotic agents and Gelfoam.  
D, Orthopantomograph 6 months later shows reossification of the lesion and normal migration of a dental germ.

Complete resection of an AVM after partial embolization has been the safest treatment, but it may induce major functional damage as it fails to respect mandibular growth [1, 4, 5]. Surgical curettage after preoperative embolization or ligature has been proposed [5, 6]. This treatment method appears more conservative, but its long-term efficacy is uncertain and the risk of recurrence is not negligible.

Superselective arterial embolization with particles or glue (using coaxial balloon catheters or direct puncture of the feeders) has been reported [3, 7, 8]. Embolization with glue seems more effective than with particles [3] when the embolic agents can be delivered close to the nidus, but it is rarely complete. It can be responsible for mucosal or cutaneous necrosis and does not prevent recurrence.

Successful venous approaches have been previously reported for the treatment of arteriovenous communications such as carotidocavernous fistulas or aneurysms of the vein of Galen [12, 13]. In our cases, such an approach was possible because of the particular architecture of the AVM; that is, enlarged arteries feeding a single, sometimes multilocular venous pouch draining into a unique single vein [1].

Ferromagnetic embolic agents should not be used, as MR seems to be reliable for demonstrating the thrombosis of the

AVM, persistent venous drainage, and other evidence of possible recurrence. Nevertheless, the best criterion to assess a definitive treatment of the AVM seems to be the conventional orthopantomograph when it shows complete reossification of the lesion, as it did in our two patients. A late control angiogram should only be necessary in case of doubt about recurrence of the AVM.

#### REFERENCES

1. Guibert-Tranier F, Piton J, Riche MC, Merland J, Caille JM. Vascular malformations of the mandible (intraosseous haemangiomas). *Eur J Radiol* 1982;2:257–272
2. Maurizi M, Fiumicelli A, Paludetti G, Simoncelli C. Arteriovenous fistula of the mandible: a review of the literature and report of a case. *Int J Pediatr Otorhinolaryngol* 1982;4:171–179
3. Rudane ES, Douglas DR, Kenneth KK, et al. Treatment of a central arteriovenous malformation of the mandible with cyanoacrylate: a 4-year follow-up. *Oral Surg* 1988;65:267–271
4. Jackson IT, Clifford RJ, Aycock B, Duben B, Irons GB. The management of intraosseous arterio-venous malformations in the head and neck area. *Plast Reconstr Surg* 1989;84,1:47–54
5. Gallagher DM, Hilley D, Epker N. Surgical treatment of an arteriovenous malformation of the mandible in a child. A case report. *J Craniomaxillofac Surg* 1983;11:279–283
6. Mohnac AM, Smith JR. Central hemangioma and the mandible: report of

- a case. *J Oral Maxillofac Surg* **1972**;30:293-296
7. Van den Akker HP, Kuiper L, Peeters FLM. Embolization of an arteriovenous malformation of a mandible. *J Oral Maxillofac Surg* **1987**;45:255-260
  8. Hupp JR. Superselective angiography with digital subtraction and embolization of a maxillary hemangioma in a patient with Eisenmenger's syndrome. *J Oral Maxillofac Surg* **1986**;44:910-916
  9. Doppman JL, Pevsner P. Embolization of arteriovenous malformations by direct percutaneous puncture. *AJR* **1983**;140:773-778
  10. Yakes WF, Haas DK, Parker SH, et al. Symptomatic vascular malformations: ethanol embolotherapy. *Radiology* **1989**;170:1059-1066
  11. Zhao-Ju Z, Yun-Tang W, Guang-Xi S, et al. Clinical application of angiography of oral and maxillofacial hemangiomas. *Oral Surg* **1983**;55:437-447
  12. Teng MMH, Guo WY, Huang CI, et al. Occlusion of arteriovenous malformations of the cavernous sinus via the superior ophthalmic vein. *AJNR* **1988**;9:539-546
  13. Manelfe C, Berenstein A. Treatment of carotid cavernous fistulas by venous approach. *J Neuroradiol* **1980**;7:13-19