

# Generic Contrast Agents

Our portfolio is growing to serve you better. Now you have a *choice*.



FRESENIUS  
KABI

[VIEW CATALOG](#)

# AJNR

## **Contrast enhancement of the labyrinth on MR scans in patients with sudden hearing loss and vertigo: evidence of labyrinthine disease.**

S Seltzer and A S Mark

*AJNR Am J Neuroradiol* 1991, 12 (1) 13-16

<http://www.ajnr.org/content/12/1/13>

This information is current as  
of May 6, 2025.

# Contrast Enhancement of the Labyrinth on MR Scans in Patients with Sudden Hearing Loss and Vertigo: Evidence of Labyrinthine Disease

Sharon Seltzer<sup>1</sup>  
Alexander S. Mark<sup>2</sup>

The sudden onset of hearing loss and vertigo presents a difficult diagnostic problem. We describe the finding of labyrinthine enhancement on MR images in five patients with sudden unilateral hearing loss or vertigo or both and correlate the MR findings with audiologic and electronystagmographic studies. All patients were studied with T2-weighted axial images through the whole brain, contrast-enhanced 3-mm axial T1-weighted images through the temporal bone, and enhanced T1-weighted sagittal images through the whole brain. Cochlear enhancement, on the side of hearing loss only, was found in all five patients. The presence of associated vestibular enhancement correlates with objective measures of vestibular function on the electronystagmogram. In two patients, the resolution of symptoms 4–6 months later correlated with resolution of the enhancement on gadopentetate dimeglumine-enhanced MR images. Two patients had luetic labyrinthitis. No labyrinthine enhancement was seen in a series of 30 control subjects studied with gadopentetate dimeglumine-enhanced MR using the same protocol.

Labyrinthine enhancement in patients with auditory and vestibular symptoms is a new finding and is indicative of labyrinthine disease. While abnormalities on electronystagmograms and audiograms are nonspecific and indicate only a sensorineural problem, gadopentetate dimeglumine-enhanced MR may separate patients with retrocochlear lesions, such as acoustic neuromas, from those in whom the abnormal process is in the labyrinth or is intraaxial. This group of patients underscores the importance of identifying and commenting on the structures of the membranous labyrinth when evaluating MR studies of the internal auditory canal and the cerebellopontine angle in individuals with hearing loss.

*AJNR* 12:13–16, January/February 1991

The sudden onset of hearing loss with or without vertigo is a difficult diagnostic problem for clinicians. The evaluation of these findings includes not only audiologic and vestibular testing but also axial CT and MR imaging with or without gadopentetate dimeglumine. To date, the primary role of MR imaging in this setting has been to exclude cerebellopontine angle and intraaxial lesions [1, 2].

In this article we report observations of labyrinthine enhancement when the MR contrast agent gadopentetate dimeglumine was administered to five patients with sudden unilateral hearing loss or vertigo or both and correlate the MR findings with objective measures of auditory and vestibular function by audiologic and electronystagmographic (ENG) studies, respectively.

## Materials and Methods

Five patients (two men and three women 39–73 years old) with sudden onset (over a period of less than 48 hr) of unilateral hearing loss or vertigo or both are described. Three patients had a recent or concurrent history suggestive of a viral illness; two patients had a reactive serum fluorescent treponemal antibody (FTA) test, suggesting the diagnosis of luetic labyrinthitis. All patients were given IV gadopentetate dimeglumine in a dosage of 0.1 mmol/

Received May 8, 1990; revision requested June 7, 1990; revision received July 12, 1990; accepted July 13, 1990.

Presented at the annual meeting of the American Society of Head and Neck Radiology, New Orleans, May 1990, where it was the recipient of the Resident's Award for best paper.

<sup>1</sup> Department of Radiology, George Washington University, Washington, DC 20052. Present address: Department of Radiology, SB-05, University of Washington, Seattle, WA 98195.

<sup>2</sup> Department of Radiology, Washington Hospital Center, Washington, DC 20010. Address reprint requests to A. S. Mark.

0195-6108/91/1201-0013

© American Society of Neuroradiology



kg. All patients were studied on a 1.5-T superconductive magnet with T2-weighted axial images, 2800/30,80/1 (TR/TE/excitations), through the whole brain, as well as enhanced T1-weighted axial images, 600/20/2, through the temporal bone. Enhanced T1-weighted sagittal images through the whole brain were obtained also. In one patient, coronal images were obtained too. The axial images were 3 mm thick with a 0.5-mm gap. In some patients, because of slight asymmetry in positioning, the right and left labyrinths did not appear on the same image. In these cases, a split-screen technique was used for display to allow direct comparison of the right and left labyrinths. Each half of the image was displayed using identical window and level settings. With this technique, it was verified that the background intensity of the temporal bone on each side was the same, allowing comparison of the intensity of the labyrinths. This technique resulted in slight differences in the intensity of the cerebellar hemispheres, but did not affect the comparison of the labyrinths.

A series of 30 patients referred for exclusion of acoustic neuromas or brainstem disease were evaluated using the same MR protocol, including 3-mm-thick enhanced T1-weighted axial images through the internal auditory canals. The MR images of the asymptomatic labyrinth were evaluated retrospectively for labyrinthine enhancement and were used as controls. We also reviewed the labyrinths of six patients with intracanalicular and/or cisternal acoustic neuromas. In the four patients with localizing symptoms and signs, the asymptomatic side provided an internal control for comparison. All audiologic and ENG studies were reviewed by a certified audiologist.

**TABLE 1: Findings in Patients with Audiologic Evidence of Severe Hearing Loss**

Case No.	Age	Sex	Vestibular Function (Electronystagmography)	MR Enhancement	
				Cochlea	Vestibule
1	73	F	Severely decreased	Yes	Yes
2	71	M	Severely decreased	Yes	Yes
3	39	M	Normal	Yes	No
4	67	F	Minimally decreased	Yes	No
5	70	F	Abnormal <sup>a</sup>	Yes	Yes

<sup>a</sup> Caloric inversion on warm water stimulation of symptomatic ear, a response that can indicate a brainstem lesion.

## Results

Table 1 summarizes our results. All five patients had sudden deafness, four with unilateral hearing loss and one with bilateral but asymmetric hearing loss. Cochlear enhancement was present only on the symptomatic side in the four patients with unilateral deafness and in the profoundly deaf ear of the patient with bilateral hearing loss (Figs. 1–3). Four of the five patients also had vertigo, but vestibular enhancement was seen only in the three patients with severe ENG abnormalities. The patient with bilateral deafness also had facial paresis on the profoundly deaf side. The facial nerve on the paretic side enhanced. No enhancement of the asymptomatic labyrinth was seen in the 30 control subjects. None of the six patients with acoustic neuromas had labyrinthine enhancement on the symptomatic side. The T2-weighted images showed no brainstem abnormalities.

## Representative Case Reports

### Case 2

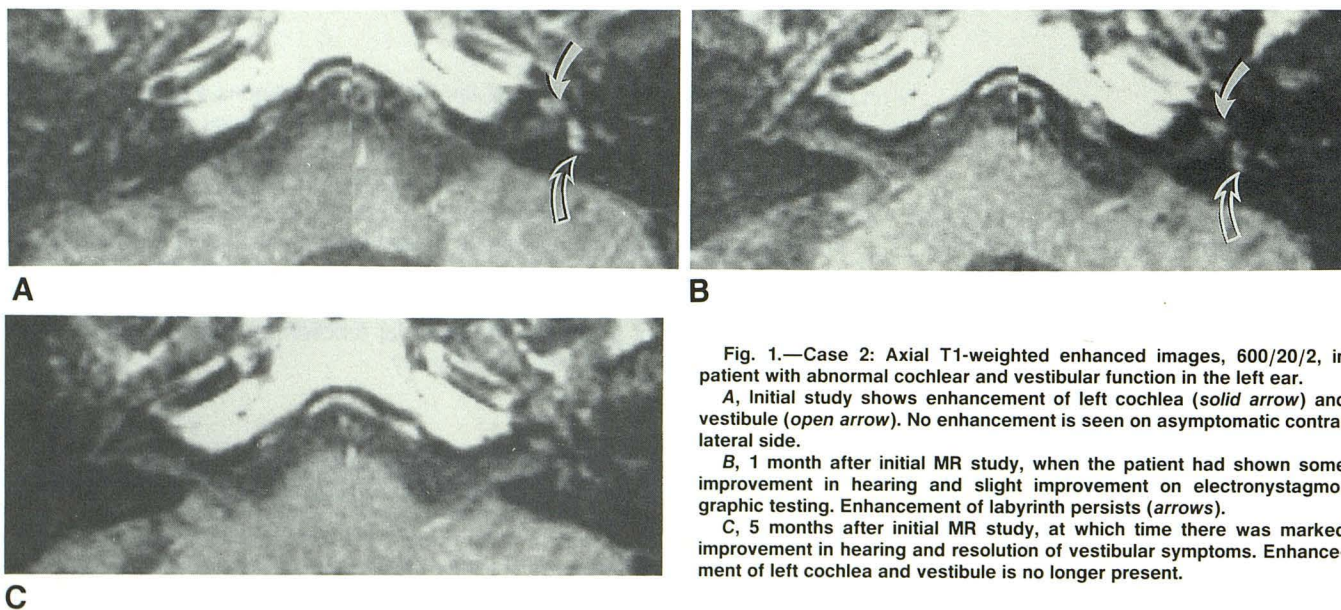
A 71-year-old man experienced sudden onset of vertigo, left-sided hearing loss, and tinnitus associated with a flulike illness. There was moderate to severe hearing loss on the left, with no response to caloric stimulation, consistent with severe vestibular dysfunction. Enhanced MR imaging (Fig. 1A) revealed enhancement of the left cochlea and vestibule but no enhancement on the right.

An audiogram 6 weeks after the onset of symptoms showed somewhat improved hearing and discrimination. The patient still experienced dizziness. A repeat ENG was still abnormal although slightly improved. Enhanced MR imaging at this time showed persistent enhancement of the left cochlea and vestibule (Fig. 1B).

An audiogram 3½ months later showed continued improvement in hearing in the patient's left ear. The dizziness had resolved completely. A follow-up enhanced MR study 1 month later (5 months after the initial MR study) showed no enhancement of either the left cochlea or vestibule (Fig. 1C).

### Case 3

A 39-year-old man experienced sudden bilateral deafness, right worse than left, and a peripheral right facial paresis. An audiogram



**Fig. 1.—Case 2: Axial T1-weighted enhanced images, 600/20/2, in patient with abnormal cochlear and vestibular function in the left ear.**

**A**, Initial study shows enhancement of left cochlea (solid arrow) and vestibule (open arrow). No enhancement is seen on asymptomatic contralateral side.

**B**, 1 month after initial MR study, when the patient had shown some improvement in hearing and slight improvement on electronystagmographic testing. Enhancement of labyrinth persists (arrows).

**C**, 5 months after initial MR study, at which time there was marked improvement in hearing and resolution of vestibular symptoms. Enhancement of left cochlea and vestibule is no longer present.



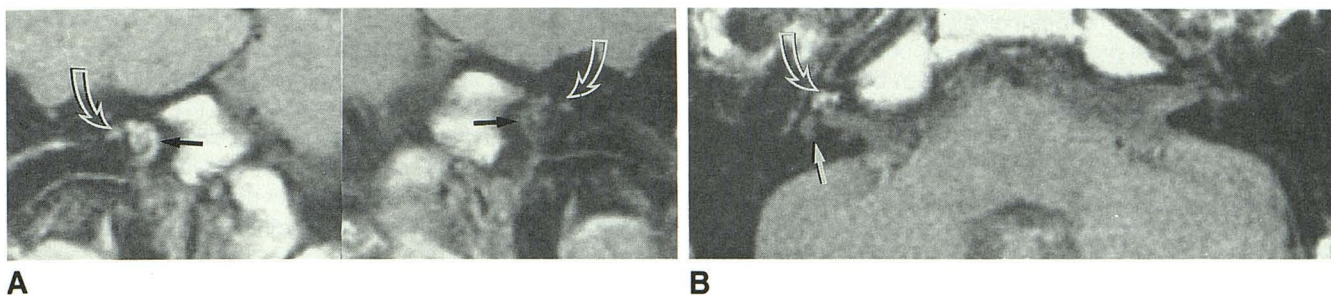


Fig. 2.—Case 3: T1-weighted enhanced images, 600/20/4, in patient with profound right-sided hearing loss, facial palsy on the right, moderate left-sided hearing loss, and positive CSF and blood serology for syphilis.

A, Coronal image shows enhancement of right cochlea (solid arrows) and right facial nerve (open arrows). Left cochlea and facial nerve are normal. B, Axial image 5 weeks after initial study reveals lack of vestibular enhancement (solid arrow) and persistent cochlear enhancement (open arrow).

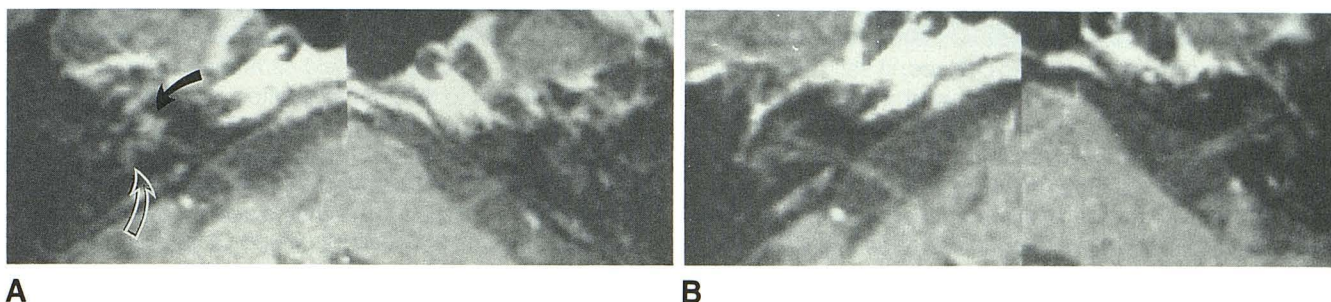


Fig. 3.—Case 4: Axial T1-weighted enhanced images, 600/20/2, in patient with right-sided hearing loss and vertigo with only minimally abnormal electronystagmogram.

A, Initial study shows enhancement of cochlea (solid arrow) but not of vestibule (open arrow) on right side. No enhancement is seen of asymptomatic side.

B, 6 months after initial study, by which time the patient's hearing and discrimination had improved. Right cochlea no longer enhances.

revealed profound hearing loss in the right ear (no response) and a moderate sensorineural loss in the left ear with fair discrimination. An enhanced MR image (Fig. 2A) revealed enhancement of the right cochlea and right facial nerve.

The patient's FTA was 4+ reactive, and he was treated with penicillin and steroids. An MR image 5 weeks later, with unenhanced and enhanced images (Fig. 2B), revealed persistent but decreased enhancement of the cochlea and no enhancement of the facial nerve.

#### Case 4

A 67-year-old woman presented with acute onset of hearing loss and tinnitus on the right following a recent flu-like illness. There was a severe sensorineural hearing loss in the right ear, but on the left the ENG was only mildly abnormal. Enhanced MR imaging (Fig. 3A) demonstrated enhancement of the cochlea, but not of the vestibule, on the right side. The other side was normal. An audiogram 6 months after the onset of symptoms revealed significant but incomplete resolution of the hearing deficit. No enhancement of the labyrinth was seen on a follow-up enhanced MR image (Fig. 3B) at the time of the repeat audiogram.

#### Discussion

Sensorineural hearing loss due to cerebellopontine angle/internal auditory canal lesions, especially acoustic neuromas, and intraaxial causes have been reported extensively [1, 2]. Little attention has been paid to MR identification of abnormalities of the bony and membranous labyrinth.

In this report we present a series of patients with sudden hearing loss and/or vertigo who had enhancement of the labyrinth on contrast-enhanced MR images. We believe this

finding represents labyrinthitis. The membranous labyrinth is an interconnecting series of tubes and sacs containing endolymphatic fluid and the vestibular and cochlear sensory structures. It is suspended in perilymphatic fluid and lies within the bony labyrinth. The membranous labyrinth has precarious vascularization with no collateral circulation from the otic capsule [3].

The membranous labyrinth with its surrounding perilymph is well seen as an intermediate-signal-intensity structure against the low signal intensity of the temporal bone on T1-weighted MR images. The fluid in the cochlea and vestibule produces high signal intensity on T2-weighted images.

Enhancement on contrast-enhanced T1-weighted sequences is well documented in a number of inflammatory as well as neoplastic lesions, reflecting the breakdown of the blood-brain barrier [4, 5]. We believe the labyrinthine enhancement seen in our cases represents accumulation of gadopentetate dimeglumine in the abnormal labyrinthine membrane.

There are many causes of sudden sensorineural hearing loss and vertigo [6]. In the five cases we report, viral labyrinthitis is postulated as the most likely disease process in cases 1, 2, and 4, with luetic labyrinthitis most likely in cases 3 and 5. Previous reports have pointed out that the labyrinth may become involved in the course of specific viral infections such as measles, mumps, and upper respiratory infections and that sudden deafness may be caused by viral infection without clinical evidence of systemic involvement [3, 7, 8]. Luetic labyrinthitis, which can occur in the presence of a positive serum but negative CSF FTA test (as was found in case 5), is also recognized as a cause of hearing loss and vertigo [3]. The history of virallike illnesses in the three patients with



recent epidemiologic, histopathologic, immunologic, and virologic studies [7, 8] provides strong support for viral labyrinthitis as the underlying disease process in our patients. The argument for viral labyrinthitis is particularly strong in cases 2 and 4, both of which had documented improvement in hearing over a period of several months—a clinical course much more consistent with viral labyrinthitis than with a vascular insult.

Even though ischemic injury to the labyrinth has been hypothesized as a cause of sudden hearing loss, experimental studies in guinea pigs have shown that ischemia of 30 min or longer results in permanent severe loss of inner ear function [9, 10]. Thus, ischemia would be an unlikely explanation for our patients' symptoms, since significant recovery of function occurred in cases 2 and 4.

The lack of unenhanced images in some of our patients is unfortunate because they might have provided unequivocal proof of labyrinthine enhancement, as opposed to high signal intensity from proteinaceous fluid or blood, in each case. Axial unenhanced images were not obtained in these patients because the majority of studies in patients referred to our institution to exclude acoustic neuromas were normal. For technical reasons, we were unable to obtain unenhanced T1-weighted images in these patients at a later time. Subacute hemorrhage in the labyrinth theoretically could produce high signal intensity in the labyrinth on T1-weighted images and persist on enhanced studies, thus mimicking enhancement. Proteinaceous fluid also could theoretically cause T1 shortening and high signal intensity on unenhanced T1-weighted images. Elevated protein in perilymphatic fluid has been reported [11] in patients with acoustic neuromas. Although hemorrhage or proteinaceous fluid in the labyrinth could mimic enhancement, the appearance of high signal intensity in the cochlea and vestibule on unenhanced T1-weighted images was never reported in the numerous studies of patients evaluated for hearing loss before the availability of gadopentetate dimeglumine. There was no high signal in the labyrinth on the affected side in the six patients with acoustic neuromas. Therefore, if the perilymphatic protein was elevated in the neuroma cases, it was insufficient to cause high signal in the labyrinth. In case 3, however, both unenhanced and enhanced follow-up images were obtained and confirmed enhancement of the cochlea.

In the future, additional correlative studies such as viral titers might help elucidate the pathologic significance of labyrinthine enhancement in patients with sudden hearing loss and vertigo.

In our series, there seems to be a relationship between the degree of functional impairment and enhancement with gadopentetate dimeglumine. There appears to be a threshold of labyrinthine inflammation beyond which enhancement becomes apparent. In this series, enhancement of the labyrinth appears to be a highly specific sign of labyrinthine disease, since all patients with this finding had markedly abnormal labyrinthine function on the enhancing side. The sensitivity of this finding remains to be determined, but our study suggests that patients with lesser degrees of involvement (as in the vestibule in case 4 and the right cochlea in case 3) may not demonstrate enhancement of the labyrinth. A similar threshold phenomenon was described in experimental studies of bac-

terial meningitis in dogs: areas of meningeal enhancement correlated with areas of pathologically proved meningeal inflammation, but several areas of milder inflammation did not enhance with gadopentetate dimeglumine [4].

Enhancement of the cochlea is not specific for inflammatory lesions. A case report of cochlear enhancement in a patient with a surgically proved intracochlear neuroma was published recently [12]. Previously, intralabyrinthine neurinomas were rarely suspected on the basis of radiologic studies or diagnosed during life, although they have been reported in histopathologic studies of temporal bones [13]. Because intracochlear neuromas are so rare, it is not known whether they could present with sudden hearing loss. Thus, intralabyrinthine neuromas cannot be excluded completely unless resolution of the enhancement can be documented, as in cases 2 and 4.

In conclusion, when evaluating a patient with hearing loss or vertigo, the radiologist should carefully scrutinize the labyrinth, in addition to the internal auditory canal, cerebellopontine angle, and brainstem. Since the abnormalities seen on ENG and audiograms are nonspecific and indicate only a sensorineural problem, enhanced MR scans may separate patients with retrocochlear lesions, such as acoustic neuromas, from patients in whom the abnormal process is labyrinthine or intraaxial.

#### ACKNOWLEDGMENTS

We thank Joseph C. Chapman, Jr., and A. Julia Gulya for clinical correlation, Janice Nelson-Drake for reviewing the audiologic and vestibular studies, David O. Davis for support, and H. Ric Harnsberger for valuable suggestions.

#### REFERENCES

- Stack JP, Ramsden RT, Antoun MK, et al. Magnetic resonance imaging of acoustic neuromas: the role of gadolinium-DTPA. *Br J Radiol* **1988**;61:800-805
- Armington WG, Harnsberger HR, Smoker WRK, et al. Normal and diseased acoustic pathways: evaluation with MR imaging. *Radiology* **1988**;167:509-515
- Schuknecht HF. Pathology of the ear. Cambridge, MA: Harvard University, **1974**;61, 258-262
- Matthews VP, Kuharik MA, Edwards MK, D'Amour PG, Azzarelli B, Dreesen RG. Gd-DTPA enhanced MR imaging of experimental bacterial meningitis: evaluation and comparison with CT. *AJNR* **1988**;9:1045-1050
- Brant-Zawadzki M, Berry I, Osaki L, et al. Gd-DTPA in clinical MR of the brain: 1. Intraaxial lesions. *AJNR* **1986**;147:1223-1230
- Wilson WR. Sudden sensorineural hearing loss. In: English GM, ed. *Otolaryngology*, vol. 1. Philadelphia: Harper & Row, **1987**;34:2
- Cole RR, Jahrsdoerfer RA. Sudden hearing loss: an update. *Am J Otol* **1988**;9:211-215
- Wilson WR, Veltri RV, Laird N, Sprinkle PM. Viral and epidemiologic studies of idiopathic sudden hearing loss. *Otolaryngol Head Neck Surg* **1983**;91:653-658
- Perlman H, Kimura R. Experimental obstruction of venous drainage and arterial supply of the inner ear. *Ann Otol Rhinol Laryngol* **1957**;66:537-546
- Perlman H, Kimura R, Fernandez C. Experiments on temporary obstruction of the internal auditory artery. *Laryngoscope* **1959**;69:591-613
- Silverstein H. Diagnostic labyrinthotomy. In: English GM, ed. *Otolaryngology*, vol. 1. Philadelphia: Harper & Row, **1987**;44:6-7
- Brogan M, Chakeres DW. Gd-DTPA-enhanced MR imaging of cochlear schwannoma. *AJNR* **1990**;11:407-408
- Babin RW, Harker LA. Intralabyrinthine acoustic neurinomas. *Otolaryngol Head Neck Surg* **1980**;88:455-461