



Discover Generics

Cost-Effective CT & MRI Contrast Agents



FRESENIUS
KABI

WATCH VIDEO

AJNR

Cranial osteopetrosis: MR findings.

A Demirci and G Sze

AJNR Am J Neuroradiol 1991, 12 (4) 781-782

<http://www.ajnr.org/content/12/4/781.citation>

This information is current as
of June 5, 2025.

Cranial Osteopetrosis: MR Findings

Osteopetrosis is an inherited bone disorder characterized by general skeletal sclerosis. The cortex and spongiosa are increased in thickness and density, and the bone marrow spaces are reduced in volume [1]. Histopathologically, excessive retention of chondroosseous tissue and failure of remodeling of bones are the result of retarded osteocytic osteolysis and osteocytic chondrolysis [2]. Signs and symptoms may be related to the osteosclerosis and may be manifested as cranial nerve abnormalities and vascular compromise caused by foraminal narrowing. Other manifestations include extramedullary hematopoiesis caused by decreased bone marrow volume and an increased frequency of fracture of long bones.

Case Report

A 25-year-old man was hospitalized because of epistaxis. His medical history indicated that a diagnosis of osteopetrosis had been made when he was 1 year old. He was mentally retarded, had a short stature (151 cm), and had decreased vision and hearing. He previously had had several fractures of the extremities and mandibular osteomyelitis. During a previous hospitalization, the results of laboratory tests were carbon dioxide level of 14–19 mEq/l (14–19 mmol/l; normal, 24–30 mmol/l); chloride level of 112–116 mEq/l (112–116 mmol/l; normal, 98–103 mmol/l); and phosphorus level of 4.9–5.5 mg/dl (1.6–1.8 mmol/l; normal, 0.8–1.4 mmol/l); serum levels of calcium and parathormone and urinary pH were normal. Earlier plain films had shown diffuse skeletal sclerosis, bowing and distal enlargement of the femoral shaft, hypoplastic maxillae, poorly developed mastoid air cells and paranasal sinuses, and paraventricular and cerebellar calcifications.

Cranial CT scans obtained during the hospitalization for epistaxis showed diffuse intraparenchymal calcifications in the dentate nuclei, basal ganglia, thalami, and subcortical white matter (Fig. 1A). Also noted were hyperdense but not frankly calcified red nuclei, slightly narrowed optic foramina, poorly developed paranasal sinuses, and minimal mastoid aeration. T1-weighted MR images (400/20 [TR/TE], Fig. 1B) showed bilateral abnormally hyperintense caudate nuclei, putamina, globi pallidi, and thalami, and slightly hyperintense red nuclei. Except for the red nuclei, the hyperintense lesions were superimposed on the areas that appeared calcified on the CT scan,

but were smaller than the calcifications and had well-defined borders. Proton-density (2000/35) and T2-weighted (2000/70, Fig. 1C) MR images showed hypointense basal ganglia, thalami, white matter, red nuclei, and cerebellum. MR images (400/20) obtained after administration of gadopentetate dimeglumine showed no enhancement.

Discussion

Two major types of osteopetrosis occur: (1) an autosomal recessive form, which is diagnosed in the infant or young child and which is severe, and (2) an autosomal dominant form, which is diagnosed later in life and which causes mild symptoms. In addition, intermediate forms with variable severity may occur [1].

Cranial CT findings of osteopetrosis include thickening of the cranial bones with loss of corticomedullary interfaces, narrowing of foramina, absence or underdevelopment of the paranasal sinuses with mucosal thickening, biparietal bossing, hydrocephalus, megacephaly, brain atrophy, and underdevelopment of the skull base [1]. Our patient had some of these findings. Diffuse parenchymal calcifications in the basal ganglia, thalami, dentate nuclei, and white matter areas have been reported in osteopetrosis associated with renal tubular acidosis, attributed to carbonic anhydrase II enzyme deficiency [3, 4]. Because of the laboratory findings, our patient also might have had mild renal tubular acidosis. Decreased levels of carbonic anhydrase II are implicated as the cause of some cases of osteopetrosis. This enzyme is normally present in oligodendrocytes, osteoclasts, renal tubules, and in several other tissues, such as muscles and erythrocytes. In bone cells, carbonic anhydrase II, activated by parathyroid hormone, promotes bone resorption; therefore, decreased levels may impair resorption. Calcifications in the brain also are thought to be caused by decreased levels of carbonic anhydrase II, either as a direct effect of the decreased neuronal level of the enzyme or as a result of systemic acidosis [3].

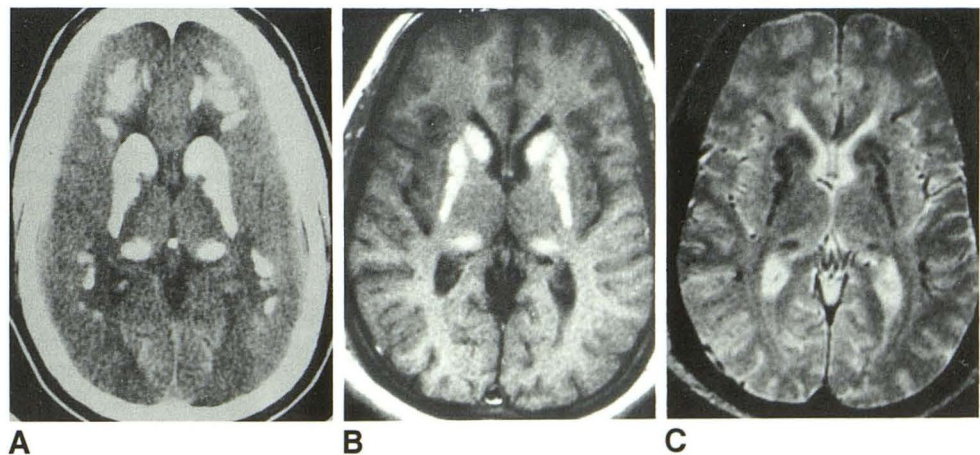
The cranial MR findings of osteopetrosis include hyperintense regions in the basal ganglia, thalami, and red nuclei on T1-weighted images. Dell et al. [5] found high-signal-intensity calcifications of the basal ganglia on T1-weighted images of a patient with pseudohypoparathyroidism. The authors suggested that calcium salt and possibly other elements decrease the T1 of surrounding water. In their case, not all the calcified regions appeared hyperintense, and the hyperin-

Fig. 1.—Cranial osteopetrosis.

A, Unenhanced CT scan shows diffuse calcifications of basal ganglia, thalami, and white matter.

B, T1-weighted MR image (400/20) shows hyperintense areas in basal ganglia and thalami bilaterally.

C, T2-weighted MR image (2000/70) shows hypointense areas in basal ganglia, thalami, and subcortical white matter.



tense areas coincided with regions of frequent deposition of paramagnetic substances, such as iron-containing compounds, or melanin.

Ali Demirci

Gordon Sze

Yale University School of Medicine

New Haven, CT 06510

REFERENCES

1. Bartynski WS, Barnes PD, Wallman JK. Cranial CT of autosomal recessive osteopetrosis. *AJNR* 1989;10:543-550
2. Krook L, Whalen JP, Dorfman HD, Norman A, Nunez EA. Osteopetrosis: an interpretation of its pathogenesis. *Skeletal Radiol* 1981;7:185-189
3. Sly WS, Whyte MP, Sundaram V, et al. Carbonic anhydrase II deficiency in 12 families with the autosomal recessive syndrome of osteopetrosis with renal tubular acidosis and cerebral calcification. *N Engl J Med* 1985;313:139-145
4. Cumming WA, Ohlsson R. Intracranial calcification in children with osteopetrosis caused by carbonic anhydrase II deficiency. *Radiology* 1985;157:325-327
5. Dell LA, Brown MS, Orrison WW, Eckel CG, Matwiyoff NA. Physiologic intracranial calcification with hyperintensity on MR imaging: case report and experimental model. *AJNR* 1988;9:1145-1148