



Get Clarity On Generics

Cost-Effective CT & MRI Contrast Agents



FRESENIUS
KABI

WATCH VIDEO

AJNR

Dural "tail" associated with an acoustic schwannoma in MR imaging with gadopentetate dimeglumine.

R Paz-Fumagalli, D L Daniels, S J Millen, G A Meyer and T M Thieu

This information is current as
of August 30, 2025.

AJNR Am J Neuroradiol 1991, 12 (6) 1206
<http://www.ajnr.org/content/12/6/1206.citation>

Dural "Tail" Associated with an Acoustic Schwannoma in MR Imaging with Gadopentetate Dimeglumine

A dural "tail" has been described in association with some meningiomas in MR imaging with IV gadopentetate dimeglumine, but, to our knowledge, never with an acoustic schwannoma [1–3]. In a recent MR study, we evaluated a lesion of the cerebellopontine angle that had a tail. The lesion was thought to be a meningioma but at surgery was proved to be an acoustic schwannoma.

Case Report

A 58-year-old woman had a 4-month history of sudden decrease in hearing. She did not have headache, tinnitus, imbalance or dizziness, facial numbness, or twitching. The results of clinical examination were unremarkable. An audiogram showed moderate to severe neurosensory hearing loss. MR showed a 2-cm mass in the cistern of the right cerebellopontine angle. The epicenter of the mass was at the porus acusticus, and tumor extension into the internal auditory canal was minimal. Intense tumor enhancement occurred after administration of gadopentetate dimeglumine (0.1 mmol/kg). A dural tail along the surface of the posterior edge of the petrous bone and enhancing to the same degree as the tumor was found in two

contiguous sections and in two planes (Fig. 1A). The mass was resected via a right suboccipital craniectomy. Pathologic examination showed that the tumor was an acoustic schwannoma (Fig. 1B). The tail itself was not studied histologically.

Discussion

The dural tail was defined by Goldscher et al. [1] as a small amount of enhancing tissue extending along the dura and tapering away from a meningioma that is present in at least two contiguous sections through the tumor and in more than one imaging plane and that enhances more than the meningioma itself does. In a retrospective review, we found that this last feature was seen in MR studies of only three of five meningiomas of the cerebellopontine studied at our institution.

With meningiomas, the histopathologic nature of the tail sign has not been clearly established. It has been described as tumoral infiltration within or at the surface of the dura [3]; loose connective tissue proliferation, hypervascularity, and vascular dilatation [2, 4]; and increased vascularity within the tail and/or a larger extracellular space in this tissue [1].

The dural tail is not pathognomonic of meningioma. Although it is most often seen with this tumor, it can be found with other tumors, such as metastases, or other meningeal processes, such as inflammatory or radiation changes [5]. This case shows that this sign may be associated with acoustic schwannoma. Thus, the tail is not a completely reliable sign to differentiate meningioma from acoustic schwannoma.

Ricardo Paz-Fumagalli
David L. Daniels
Steven J. Millen
Glenn A. Meyer
Thu-Minh Thieu
Medical College of Wisconsin
Milwaukee, WI 53226

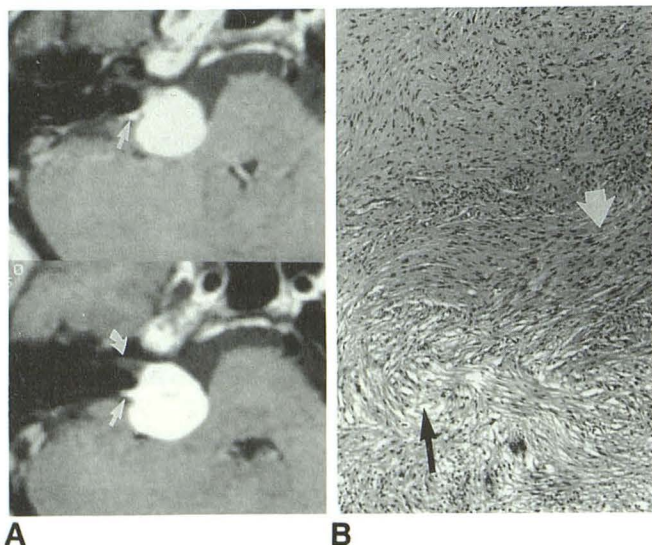


Fig. 1.—Dural tail associated with an acoustic schwannoma on contrast-enhanced MR imaging.

A, Axial T1-weighted MR images obtained after injection of IV gadopentetate dimeglumine show enhancing tail (straight arrow) adjacent to enhancing acoustic schwannoma in two contiguous sections. Schwannoma does not extend to apex of internal auditory canal (curved arrow).

B, Histologic specimen shows tumor consists of areas of interlacing bundles of spindle cells with prominent fibrillary processes (white arrow) alternating with areas of loose structure consisting of foam cells with small nuclei surrounded by clear cytoplasm (black arrow), typical of schwannoma.

ACKNOWLEDGMENT

We thank Khang-Cheng Ho for his help in preparing this manuscript.

REFERENCES

1. Goldscher D, Litt AW, Pinto RS, Bannon KR, Kricheff II. Dural "tail" associated with meningiomas on Gd-DTPA-enhanced MR images: characteristics, differential diagnostic value, and possible implications for treatment. *Radiology* 1990;176:447–450
2. Tokumaru A, O'uchi T, Eguchi T, et al. Prominent meningeal enhancement adjacent to meningioma on Gd-DTPA-enhanced MR images: histopathologic correlation. *Radiology* 1990;175:431–433
3. Wilms G, Lammens M, Marchal G, et al. Thickening of dura surrounding meningiomas: MR features. *J Comput Assist Tomogr* 1989;13:763–768
4. Aoki S, Sasaki Y, Machida T, Tanioka H. Contrast-enhanced MR images in patients with meningioma: importance of enhancement of the dura adjacent to the tumor. *AJNR* 1990;11:935–938
5. Henkes H, Schoerner W, Saunders B, Felix R. MR imaging of the meninges (abstr). *Magn Reson Imaging* 1989;7 [suppl 1]:3