



Get Clarity On Generics

Cost-Effective CT & MRI Contrast Agents



FRESENIUS
KABI

WATCH VIDEO

AJNR

Clinical aspects of temporal bone anomalies.

R A Jahrsdoerfer

AJNR Am J Neuroradiol 1992, 13 (2) 821-825

<http://www.ajnr.org/content/13/2/821.citation>

This information is current as
of August 16, 2025.

Clinical Aspects of Temporal Bone Anomalies

Robert A. Jahrsdoerfer¹

From the Department of Otolaryngology–Head and Neck Surgery,
University of Texas Medical School, Houston, Texas

The term “anomaly” refers to a marked deviation from a normal standard usually caused by a hereditary or congenital defect. While there are many classifications of temporal bone anomalies, we believe that a simple division into major and minor anomalies of the temporal bone is sufficient. Major malformations (anomalies) are those in which there is stenosis or atresia of the external ear canal. The auricle is usually small and poorly formed (microtia). In minor malformations, the congenital problem is largely limited to the middle ear and frequently involves the stapes/facial nerve axis. The external ear is fairly well formed, perhaps even normal. The external ear canal is patent and a tympanic membrane can be identified.

Based on experience in over 800 patients evaluated for congenital ear malformations, we have developed a practical grading scheme to rate the patient’s candidacy for surgery. This rating is based primarily on the computed tomography (CT) scan, although the appearance of the external ear factors into the final score. In cases carefully selected according to this system, there is an 80% chance of restoring hearing to normal or near normal levels through surgery. This manuscript will focus on the reasons for the decision to operate and will show selected case material to illustrate the salient points.

Minor Malformations

Minor malformations of the ear are important, because they may be associated with a significant conductive hearing loss, and because surgery may be hazardous to the patient. Preoperative signs are often subtle, so the ear surgeon may be unaware that he is dealing with a middle ear anomaly. In this scenario, the inner ear may be violated, the facial nerve may be injured, and major vascular structures may be penetrated. Misadventure may cause serious and permanent injury to the patient.

Minor malformations may involve the ossicles, labyrinthine windows, facial nerve, and vascular structures, or they may present as congenital cholesteatomas. Most minor malformations affecting ossicles involve the stapes/facial nerve axis. If the developing facial nerve is not “locked in” against the otic capsule during embryogenesis, it will migrate inferiorly passing through and influencing the blastema of the stapes. The facial nerve that is found at operation may be bare and displaced. Failure to recognize this anomaly intraoperatively may subject the facial nerve to iatrogenic injury (1). Secondary anomalies of the stapes and oval window vary from mild fixation of the stapes footplate to rudimentary stapes to congenital absence of the stapes. The oval window may be underdeveloped or absent. High resolution CT scanning preoperatively may reveal the displaced facial nerve and closed oval window, but a correct diagnosis requires an astute radiologist knowledgeable in congenital ear malformations.

Vascular anomalies involving the middle ear include: 1) a persistent stapedia artery, 2) a high and uncovered jugular bulb, and 3) an anomalous internal carotid artery. A persistent stapedia artery is difficult to diagnose preoperatively. The

¹ Address reprint requests to Dr Jahrsdoerfer, Professor and Chairman, Department of Otolaryngology–Head and Neck Surgery, University of Texas Medical School–Houston, 6431 Fannin, Suite 6.132, Houston, TX 77030.

Index terms: Temporal bone, abnormalities and anomalies; Pediatric neuroradiology

AJNR 13:821–825, Mar/Apr 1992 0195-6108/92/1302-0821

© American Society of Neuroradiology

other vascular conditions are amenable to diagnosis by clinical inspection using the operating microscope, provided the ear drum is transparent. When a thick opaque tympanic membrane obscures the lesion, preoperative diagnosis is still possible by high-resolution CT. If a CT scan has not been requested and these lesions are undiagnosed preoperatively, the stage is set for potential catastrophe.

A high uncovered jugular bulb will commonly present as a bluish dome-shaped mass in the lower third of the middle ear. This high, bare jugular bulb is prone to injury when the surgeon performs a routine myringotomy or raises a tympanomeatal flap. In this situation, the wall of the jugular bulb may be lacerated, causing serious hemorrhage.

An anomalous internal carotid artery coursing through the middle ear may present as a pinkish mass pressing against the medial surface of the tympanic membrane (Fig. 1). Pulsations of the blood vessel may be seen and the artery may blanch with each pulsation. Objective tinnitus can be heard on auscultation over the ear or high on the neck. An anomalous internal carotid artery is clinically relevant when the surgeon fails to recognize the structure as a major vessel and elects to biopsy the "lesion." Potential exsanguinating hemorrhage ensues. This requires immediate packing and prompt arteriography to confirm the diagnosis. Further surgery is required to either ligate the vessel or occlude it with a balloon. Bypass surgery is rarely possible because of the close confines of the temporal bone. The patient is at risk for neurologic sequelae, even death. If an anomalous internal carotid artery is discovered at the time of surgery, it should be left alone. There is no justification for manipulating the vessel or attempting to cover it with muscle or other soft tissue.

Congenital cholesteatoma may present as a small mound of squamous epithelial debris in an otherwise normal middle ear, or it may be very extensive within the temporal bone. The latter aggressive congenital cholesteatoma may destroy the middle ear and lay bare the facial nerve. Preoperative high resolution CT will show the bony destruction but the course of a displaced and bare facial nerve will be concealed by the soft-tissue density of the cholesteatoma. The facial nerve is at risk for injury in this condition.

Major Malformations

Major malformations are those in which there is atresia or stenosis of the external ear canal (Fig. 2). In atresia, the external ear canal has failed to develop. The atresia may be complete,

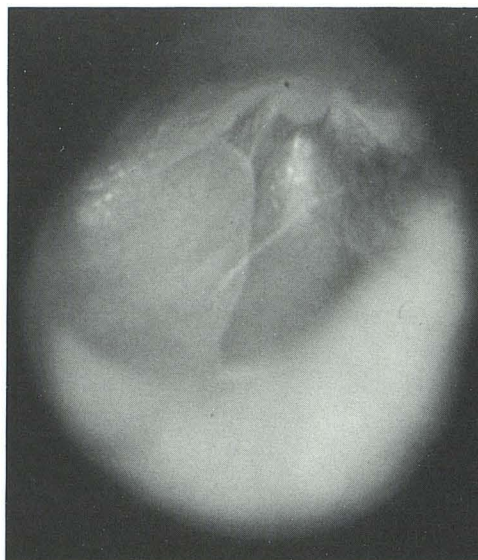


Fig. 1. Anomalous course of the internal carotid artery through the middle ear cleft as seen through an intact tympanic membrane.

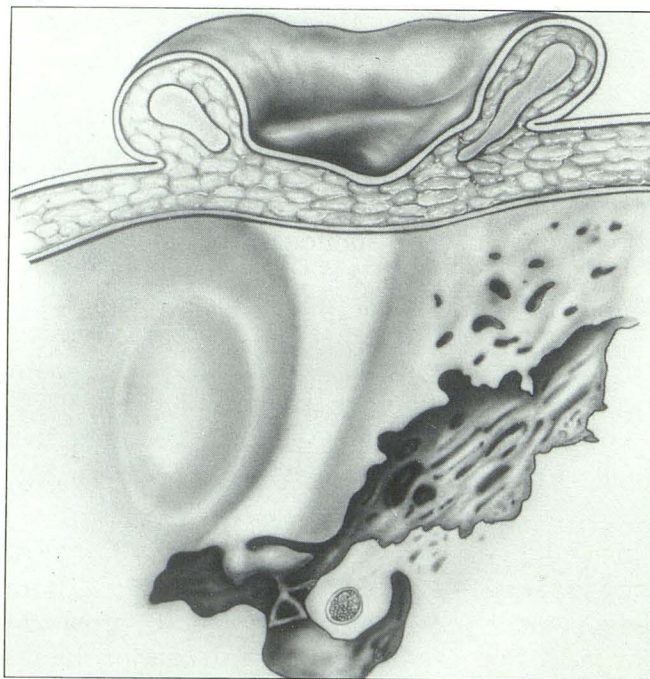


Fig. 2. Diagrammatic representation of a sagittal section through temporal bone showing congenital aural atresia. Note the dense bone extending from the lateral skull to the middle ear cleft and the fixation of the malleus neck to the atretic bone.

involving the bone, or may be soft tissue only, in which case there is found a plug of tissue filling a small bony ear canal. Microtia is often seen in concert with atresia, although on occasion the external ear may be well formed. Congenital aural atresia means that the external ear canal has failed to develop. It does not imply that the child was born with a patent external ear canal that later closed.

The microtia which usually accompanies aural atresia may be Grade III, in which the external ear is simply a small, irregular mound of skin and cartilage on the lateral face (Figure 3); Grade II, in which the external ear has some form but is one-half to two-thirds normal size; and Grade I, in which the external ear has fairly good form and is almost normal in size. In this latter category, a patient with soft tissue atresia and a blind epithelial pit for an ear canal may go undiagnosed for years, sometimes decades.

Major ear malformations occur in one in 10,000 births. Unilateral atresia is six times more common than bilateral atresia. The right ear, for some unexplained reason, is affected more often than the left. Approximately 20% of cases are inherited, while 10% are syndromic, eg, Treacher Collins syndrome or hemifacial microsomia.

Most cases of congenital aural atresia are apparent at birth. Once the diagnosis is made the most important question to be answered is, "Can my baby hear?" As behavioral audiometry is not possible in the newborn, other methods of audiologic testing must be undertaken. The most accurate method of assessing hearing in a newborn is by use of auditory brain stem evoked response testing (ABR). By using multichannel, simultaneous recordings of the ABR, ear-specific hearing can be determined without the use of masking noise. This means that it is possible, in cases of bilateral aural atresia, to specify which ear, or both, is capable of hearing. Prior to the advent of ABR, ear-specific information was almost impossible to obtain. Once a normal hearing threshold has been confirmed in at least one ear, the urgency of the situation is attenuated. Thereafter, the child may be allowed to grow and develop normally. If a bilateral hearing loss is confirmed, or even suspected, it is prudent to place a hearing aid on the child until he or she is older and better able to respond to behavioral audiologic testing.

CT

At about age 5–6 years, high-resolution CT of the temporal bones should be done. This is the single most important study performed and will determine if the patient is a candidate to have the ear opened for hearing purposes. The CT scan is performed in the 30° axial and 105° coronal planes. Life-size images are produced without loss of resolution through a special format. We also routinely obtain three-dimensional reconstructions of the CT scan. Magnetic resonance (MR) imaging is not routinely done, as this modality does not image bone. Remember that the information we seek concerns bony structures: the size of the middle ear cleft, ossicles, labyrinthine windows, and facial nerve canal, and the degree of mastoid pneumatization.

We have developed a rating scheme based on the CT scan to grade the candidacy of our patients for surgery. The scale is based on a best possible score of 10 (Table 1). In the grading scheme, the stapes is assigned 2 points, since

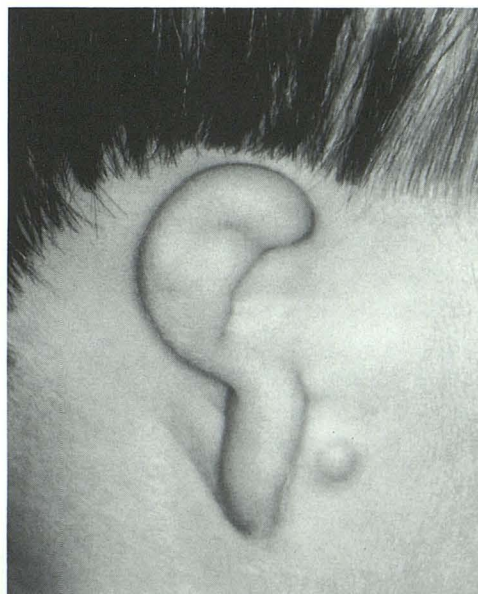

Fig. 3. Grade III microtia.

TABLE 1: Rating Scale—10 Point Total

Stapes present	2
Oval window open	1
Middle ear space	1
Facial nerve	1
Malleus/incus complex	1
Mastoid pneumatized	1
Incus-stapes connection	1
Appearance external ear	1
Round window	1

this is the most important ossicle upon which the success or failure of the operation will hinge. All other parameters are assigned 1 point. We also factor-in the preoperative appearance of the external ear, which is assigned 1 point. The relevance of the grading scale is that it enables us to identify with accuracy those ears that have the greatest chance of success through surgery. For example, a preoperative grade of 8/10 translates to an 80% chance of restoring hearing to normal or near normal levels through surgery (15–25 dB postoperatively). A grade of 5/10 or below disqualifies the patient for surgery, since the risk does not justify the small chance of success. Recently, we reported on our experience with the rating scale over the past 5 years (2). In 112 patients operated during this period, we predicted that 80% of those with a grade of 8/10 would achieve normal hearing. On final count, 82% achieved this end result.

It is our philosophy that reconstruction of the external ear must be done prior to opening the ear for hearing purposes. Simply stated, microtia repair precedes atresia repair. This requires the reconstructive surgeon to have completed at least stages I and II (stage I = cartilage implantation; stage II = lobule transposition) before the otologic surgeon operates. This point is firm in our minds and is no longer negotiable. We have not seen a cosmetically acceptable reconstructed external ear if the ear was opened prior to microtia repair.

It should be noted that not every microtic ear needs to be reconstructed. While grade III microtia needs reconstruction, grade I almost never requires surgery, and patients with grade II microtia seldom do. This means that patients with grade I and II microtia may have their atresia repaired first.

Successful reconstruction of the external ear depends on the child's having enough rib cartilage to sculpt into an acceptable ear framework. This is predicated on the size of the child's chest wall that has attained sufficient growth by 6–7 years for rib cartilage to be harvested. As atresia repair follows implantation of the sculpted rib cartilage and transposition of the lobule, the otologic surgeon will usually open the ear at about 8 years of age. Children with grade I and grade II microtia not requiring external ear reconstruction may have the ear opened earlier, usually about 5–6 years of age. In bilateral cases every effort is made to open at least one ear before the child starts school.

Other Options

It is incumbent upon the otologist to inform the patient or parents that other options are available. These include: 1) a standard bone conduction hearing aid, 2) an implantable bone conduction hearing device, and 3) the creation of an ear canal in an otherwise poor surgical candidate to accommodate an ear level or in-the-ear hearing aid.

Not every patient we evaluate is a surgical candidate for atresia repair. Only about one-half of those we evaluate ever qualify for surgery. If the patient has Treacher Collins syndrome or hemifacial microsomia, only one-fourth become candidates for surgery. In these and similar syndromes, the middle ear is usually poorly developed and the surgical grade is often 5/10 (poor or marginal candidate) or worse. Moreover, we have previously established that patients with Treacher Collins syndrome have three unusual anatomic findings that make surgery hazardous: 1) the mastoid bone is never pneumatized; 2) the fused incus/malleus is often far removed—up to 4 mm—from the stapes, so ossicular reconstruction using these ossicles is not possible; and 3) the facial nerve exits the temporal bone in a lateral bony cleft and is vulnerable to injury (3).

Surgical Technique

A detailed description of surgical technique is beyond the scope of this journal. However, there are salient points that I believe are of interest to the readership.

As previously mentioned, we routinely do three-dimensional surface reconstructions of the CT scan. This has allowed us to debunk a popular otologic premise, namely, the notion that patients with congenital atresia have the condyle of the mandible flush against the anterior face of the mastoid bone. This simply is not so. We have found that the usual location of the condyle is approximately 1 cm anterior to the mastoid bone. This indicates that in most patients with isolated aural atresia, although the tympanic bone has failed to develop, the position of the mandibular condyle has not been influenced. Clinically, this means that the surgeon has room to work and is not constrained by the condyle. We recognize that occasionally there may be exceptions to this finding, particularly in severe ear malformations with marked hypoplasia of the lateral face. However, these patients would not be surgical candi-

dates in any event, because of the primitive development of the middle ear.

Another aspect of the problem that has clinical relevance and is of interest to the neuroradiologist is the condition of the ossicular chain. It is common for the malleus and incus to be fused. It is also common for the malleus handle to be absent. Of great clinical importance is the fact that the immature ossicular chain is fixed to the atretic plate at the level of the malleus neck. This bond may be bony or periosteal but effectively fixes the ossicles in place and contributes to the conductive hearing loss. The absence of a malleus handle is clearly demonstrated on the 105° coronal CT scan, as is the point of bony fixation. If a malleus handle is found, there will usually be noted an early attempt at ear drum formation. It is uncommon for the ossicular chain to be fixed elsewhere. On occasion, the stapes may be fixed by failure of the annular ligament of the footplate to differentiate, or by lateral bony struts to the stapes crura. These conditions affecting the stapes are not amenable to radiologic diagnosis by preoperative CT scan.

Surgery of congenital aural atresia entails drilling out a new bony external ear canal, inspecting the middle ear and reconstructing the ossicular chain as necessary, building a new tympanic membrane, skin grafting the ear canal, and creating a new meatus.

If the external ear does not align well with the opening drilled through the bone, the auricle may be relocated in a superior and posterior direction, using a mini face-lift to align it better with the new bony canal.

The drilling approach to the middle ear is direct; we assiduously avoid opening into the mastoid. Indiscriminate drilling of the mastoid bone creates a large, unsightly cavity that is difficult to manage postoperatively and is prone to chronic infection. Another important point is to drill away middle ear bone peripherally to

center the ossicular mass in the approximate middle of the new tympanic membrane. One cannot replicate the normal relationship of an ear drum to the ossicles in the absence of a malleus handle. This is why a homograft tympanic membrane is not the tissue of choice in repairing the ear drum. Temporalis fascia is used routinely and has successfully withstood the test of time.

Proper placement of the split-thickness skin graft is the most difficult part of the operation and demands both talent and patience on the part of the surgeon. The operation takes 4–5 hours and requires a skilled pediatric anesthesiologist who has experience in craniofacial malformations. The operation is complex and difficult, but rewarding.

Successful surgery will allow the child to discard his/her hearing aid and assume a more mainstream pathway in life. The goal of the surgery is normal or near-normal hearing. Successful acquisition of this threshold is gratifying, not only to the patient and parents, but to the otologic surgeon as well.

Acknowledgments

Throughout this manuscript I have used the plural form to designate my colleagues on the University of Texas ear malformation team. I would like to acknowledge them individually: Fred Aguilar, MD, Facial Plastic Surgeon; Randolph Cole, MD, Pediatric Otolaryngologist; and Joel Yeakley, MD, Neuroradiologist. Moreover, I want to pay tribute to Burt Brent, MD, Plastic Surgeon, who is world renowned for his reconstructive ear surgery and who has pioneered many of the techniques in use today.

References

1. Welling DB, Glasscock ME, Gantz B. Avulsion of the anomalous facial nerve at stapedectomy. *Laryngoscope* 1992 (in press)
2. Jahrsdoerfer PA, Yeakley JW, Aguilar EA, et al. A Grading system for the selection of patients with congenital aural atresia. *Am J Otol* 1992;13:6–12
3. Jahrsdoerfer RA, Aguilar EA, Yeakley JW, et al. Treacher Collins syndrome: an otologic challenge. *Ann Otol Rhinol Laryngol* 1989;98:807–812