



Get Clarity On Generics

Cost-Effective CT & MRI Contrast Agents

**FRESENIUS
KABI**

[WATCH VIDEO](#)

AJNR

MR of the hypothalamic-pituitary axis in Langerhans cell histiocytosis.

M Maghnie, M Aricò, A Villa, E Genovese, G Beluffi and F
Severi

AJNR Am J Neuroradiol 1992, 13 (5) 1365-1371

<http://www.ajnr.org/content/13/5/1365>

This information is current as
of August 10, 2025.

MR of the Hypothalamic-Pituitary Axis in Langerhans Cell Histiocytosis

Mohamad Maghnie^{1,4} Maurizio Aricò,¹ Andrea Villa,² Eugenio Genovese,² Giampiero Beluffi,³ and Francesca Severi¹

PURPOSE: To describe the MR findings in the hypothalamic pituitary area in children with Langerhans cell histiocytosis and to define those MR alterations especially associated with the risk of developing diabetes insipidus. **METHODS:** The hypothalamic-neurohypophyseal axis was studied by sagittal and coronal 1.5 T1-weighted MR imaging in 14 children with Langerhans cell histiocytosis (five with diabetes insipidus) and in 28 low-stature controls, ages 6–14 years. **RESULTS:** The pituitary stalk was thicker in seven/14 patients (three with diabetes insipidus) than in controls ($P < .05$). Bright posterior pituitary signal was undetectable in children with diabetes insipidus and in one/9 without diabetes insipidus. **CONCLUSIONS:** Thickening of the hypothalamus and/or the pituitary stalk in the absence of the posterior pituitary bright signal is seen in children with Langerhans cell histiocytosis with overt diabetes insipidus. Those Langerhans cell histiocytosis patients without diabetes insipidus but showing thickened stalk with or without posterior pituitary bright signal could be at high risk to develop diabetes insipidus.

Index terms: Hypothalamus; Histiocytosis; Pediatric neuroradiology; Diabetes insipidus; Pituitary stalk

AJNR 13:1365–1371, September/October 1992

Langerhans cell histiocytosis (LCH), formerly called histiocytosis X, is an inflammatory disorder most often confined to bone and adjacent soft tissue, but sometimes responsible for hemopoietic, hepatic, or pulmonary dysfunction (1–3). The central nervous system (CNS) may be involved, usually with the clinical picture of diabetes insipidus (DI) occurring in 5% at the time of original diagnosis but in one quarter to one third of all cases on follow-up evaluation (4, 5).

Recent magnetic resonance (MR) imaging of patients with DI showed lack of the posterior neurohypophyseal hyperintensity in most cases (6–14). Preliminary reports suggest a peculiar MR picture of the hypothalamic-hypophyseal area in

patients with LCH-dependent DI (11–14). However, no information is available from those children before they develop DI, which occurs when more than 80% of the paraventricular-supraoptic neurons are destroyed (15).

The aim of the study was to describe the MR findings in the hypothalamic pituitary area in children with LCH and to define those MR alterations specifically associated with the risk of developing DI.

Patients and Methods

Fourteen patients were enrolled in the study, four boys and 10 girls, aged 1 to 15 years. LCH was diagnosed by skin (cases 1–3, 6, 8, 12, and 13) or bone (cases 4, 5, 7, 9, 10, 11, and 14) biopsy. Five patients had DI and were receiving treatment with 1-desamino-8-D-arginine vasopressin (DDAVP) orally or intranasally.

DI was assessed by the presence of polyuria and polydipsia and by plasma and urinary osmolality measurements, the water deprivation test, and the DDAVP therapeutic trial.

MR Study

MR imaging studies were performed with a spin-echo technique and the use of a 1.5-T superconductive unit in

Received July 19, 1991; revision requested September 26; final revision received February 12, 1992 and accepted February 24.

Part of the material reported in this work was presented at the International Congress of Pediatric Radiology 1991, the XXXI Meeting of the European Society for Pediatric Endocrinology, and at the 1991 Histiocyte Society Meeting.

Departments of ¹Pediatrics, ²Radiology, ³Pediatric Radiology, University of Pavia, IRCCS Policlinico S. Matteo, Pavia, Italy.

⁴Address reprint requests to Dr. M. Maghnie, Department of Pediatrics, University of Pavia, IRCCS Policlinico S. Matteo, I-27100 Pavia, Italy.

AJNR 13:1365–1371, Sep/Oct 1992 0195-6108/92/1305-1365
© American Society of Neuroradiology

all cases but for one patient using a 0.5-T unit. Sagittal and coronal 3-mm sections with a matrix size of 256×256 pixels and field of view of 20 cm were obtained. T1-weighted images, 400/15/4 (TR/TE/excitations) (800/50/2 when performed by 0.5-T unit) were obtained; out of the 14 patients, six were examined also after intravenous gadolinium-DTPA (Gd-DTPA) rapid injection (0.2 ml/kg).

MR images of the posterior pituitary lobe and stalk were obtained from 28 control children (age range 6–14 years) without evidence of polyuria and polydipsia, who were being investigated because of short stature. Informed consent was obtained from all subjects and/or their parents.

The transverse diameter of the pituitary stalk (PS) was measured by three observers from examination of the film taken prior to contrast administration, with the help of a hand precision-micrometric optic caliper, 0.02-mm interval scale (Tesa, Switzerland); the measurement was taken on midstalk except for those patients with PS-thickening at a higher level. The 5-cm grid that appears on each scan was used as a reference standard for conversion of these measurements to millimeters. Mean values and standard deviation were calculated.

Results

Clinical and MR findings are summarized in Table 1. The bright posterior signal was not detected in the pituitary fossa in any of the five

patients with LCH and DI. The PS was enlarged in three (Table 1—cases 2, 4, and 5): at the medium eminence of hypothalamus in case 2 (Fig. 1), at the proximal infundibulum in case 4 (Fig. 2), and uniformly in case 5 (Fig. 3); cases 2 and 3 also had a small anterior pituitary (Fig. 1). All areas of stalk enlargement were homogeneously enhanced and better defined after Gd-DTPA administration. The PS was normal in two cases (cases 1 and 3).

Nine patients had LCH without DI. The bright posterior signal was present in eight/nine cases. The PS was normal in five (Fig. 4) and enlarged in four (Fig. 5). All areas of stalk enlargement were homogeneously enhanced and better defined after Gd-DTPA administration (Fig. 5).

The PS diameter values are reported in Table 2. Normal hyperintense posterior pituitary signal was observed in all controls.

Discussion

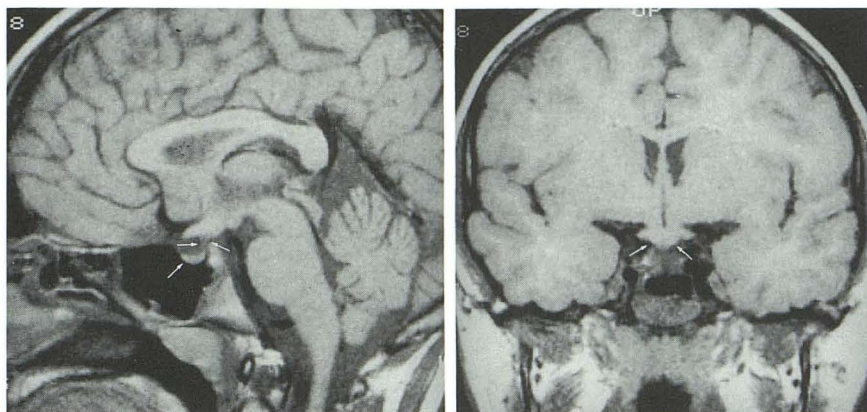
Although granulomatous infiltration may occur occasionally anywhere in the CNS in the course of LCH, the hypothalamic nuclei are the most common targets (11–14, 16–25). As a result, DI

TABLE 1: Clinical and MR imaging features of 14 children with LCH

Patient	Sex/Age	DI	Hypothalamus	Enlarged Stalk	Stalk Size (mm S/C)	Anterior	Posterior	Gd-DTPA
1	F/1	+	Normal	—	1.32/1.54	Normal	Absent	NP
2	M/12	+	Thickened	+	5.69/5.47 6.16/5.83 ^a	Hypoplastic	Absent	+
3	F/10	+	Normal	—	2.27/2.06	Hypoplastic	Absent	NP
4	M/14	+	Normal	+	3.88/4.22	Normal	Absent	NP
5	F/7	+	Normal	+	4.88/4.88	Normal	Absent	NP
6	F/3	—	Normal	—	0.83/1.54	Normal	Normal	NP
7	F/7	—	Normal	+	2.96/2.96 3.45/3.32 ^a	Normal	Normal	+
8	F/6	—	Normal	—	1.91/1.67	Normal	Normal	NP
9	M/10	—	Normal	+	2.89/2.86 3.31/3.22 ^a	Normal	Normal	+
10	M/15	—	Normal	—	1.73/2.26 1.76/2.12 ^a	Normal	Normal	+
11	F/5	—	Normal	—	1.62/1.24	Normal	Normal	NP
12	F/5	—	Normal	+	3.51/2.95	Normal	Absent	NP
13	F/6	—	Normal	—	1.57/1.65 1.59/1.71 ^a	Normal	Normal	+
14	F/11	—	Normal	+	3.41/3.31 4.44/4.23 ^a	Normal	Normal	+

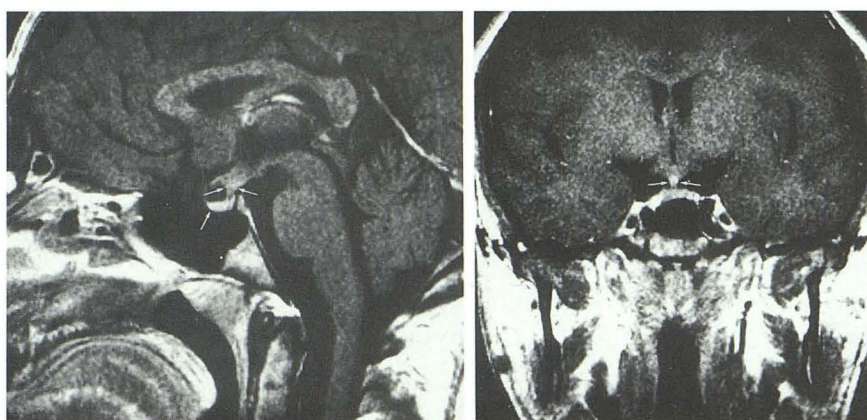Note.—Normal pituitary stalk size: sagittal section 1.42–2.51 (mean 1.85 ± 0.32); coronal section 1.37–2.63 (mean 1.92 ± 0.33). DI = diabetes insipidus; S/C = sagittal/coronal; NP = not performed.

^a After Gd-DTPA.



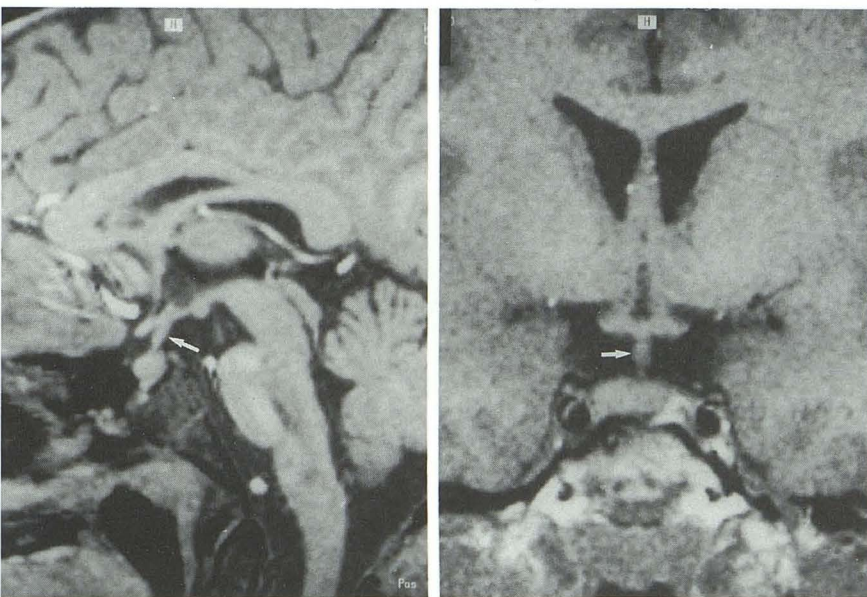
A

B



C

D



A

B

Fig. 1. Case 2, 12-year-old boy with DI.

A and B, Sagittal (A) and coronal (B) T1-WI images (400/15) showing thickened median eminence (sagittal width = 5.69 mm, coronal width = 5.47 mm) (arrows) and absence of normal bright posterior pituitary signal. Small anterior pituitary (lower arrow).

C and D, Sagittal (C) and coronal (D) T1-WI images, 400/15, obtained after intravenous injection of Gd-DTPA showing better definition of the lesion (sagittal width = 6.16 mm, coronal width = 5.83 mm) (arrows).

Fig. 2. Case 4, 14-year-old boy with DI. Sagittal (A) and coronal (B) T1-WI images (400/15) showing thickened PS (arrow) (sagittal width = 3.88 mm, coronal width = 4.22 mm) and absence of normal bright posterior pituitary signal.

occurs in the follow-up of one quarter to one third of LCH children (4, 5). Recently, the superiority of MR imaging to CT scan in the evaluation of posterior pituitary has been reported in children

with pituitary dwarfism (26, 27) as well as in children with DI of different origin, including LCH (10-14, 28).

MR evidence of a normal bright posterior pi-

Fig. 3. Case 5, 7-year-old girl with DI. Sagittal (A) and Coronal (B) T1-WI images (800/50) showing uniformly thickened PS (arrows) (sagittal width = 4.88 mm, coronal width = 4.88 mm) and absence of normal bright posterior pituitary signal.

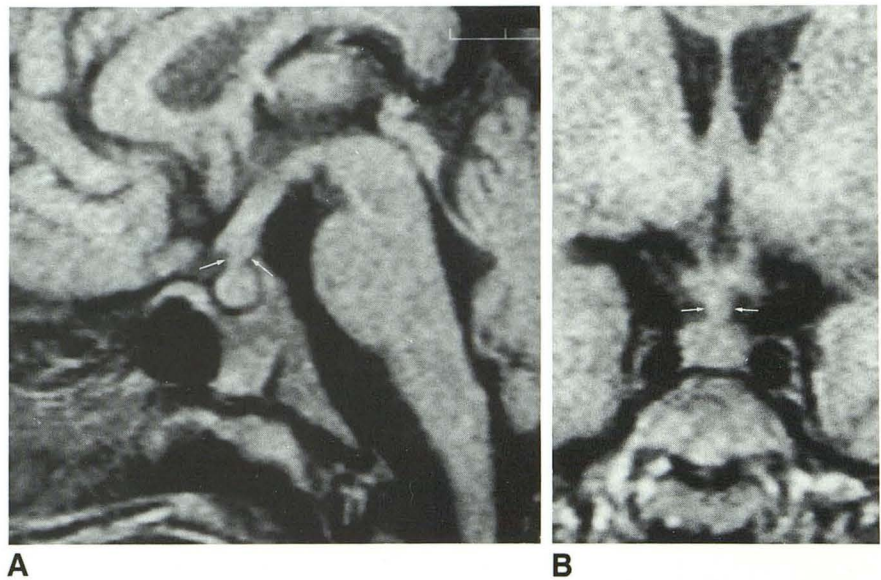
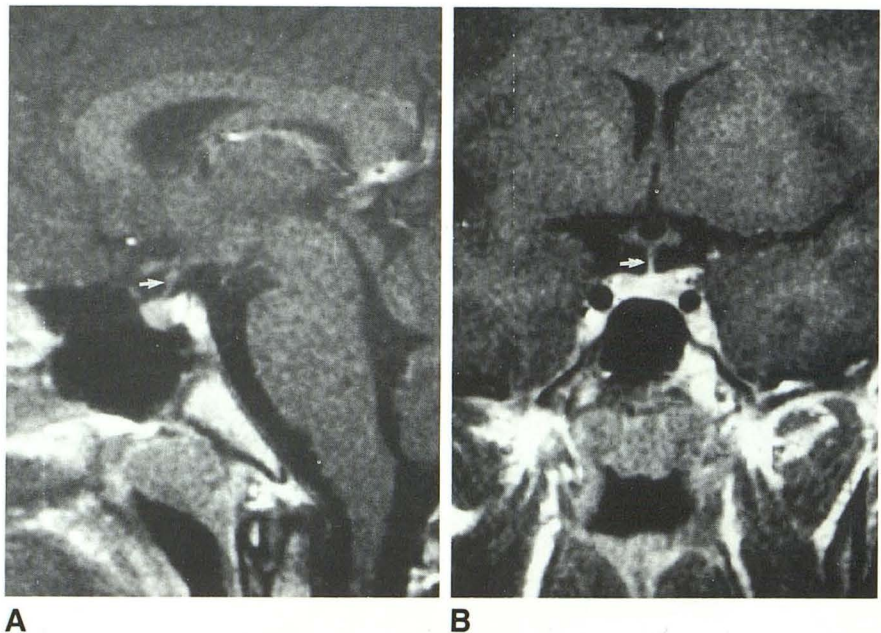


Fig. 4. Case 10, 15-year-old boy without DI. Sagittal (A) and coronal (B) T1-WI images (400/15) showing normal PS (arrow) (sagittal width = 1.73 mm, coronal width = 2.26 mm), and normal bright posterior pituitary signal.



tuitary signal indicates normal hypothalamic-neurohypophyseal axis function, as is suggested also by its presence in 90%–100% normal subjects (8, 10, 29) and its absence in children with central DI (8, 11–14, 28). The hyperintense posterior signal was lacking in all of our five LCH children with DI. Moreover, thickening of the hypothalamus and/or of the stalk was observed in three of the five. The thickening pattern varied, involving in different cases the hypothalamic median eminence, the proximal infundibular tract, and the whole stalk. This is in agreement with some recent MR reports of combined thickened

PS and absent posterior hyperintense signal in patients with either systemic or CNS isolated, biopsy-proven LCH with DI (11–13). Thus hypothalamic-stalk enlargement with undetectable posterior hyperintense signal probably represents the imaging of the CNS involvement in LCH children with DI. Its frequency ranges between 60% in our series and 80%–100% in other reports (11–13). In our two patients with no evidence of stalk enlargement, we cannot rule out that this feature may have been modified by specific treatment. This would be in keeping with recent reports of therapy-related reversible PS

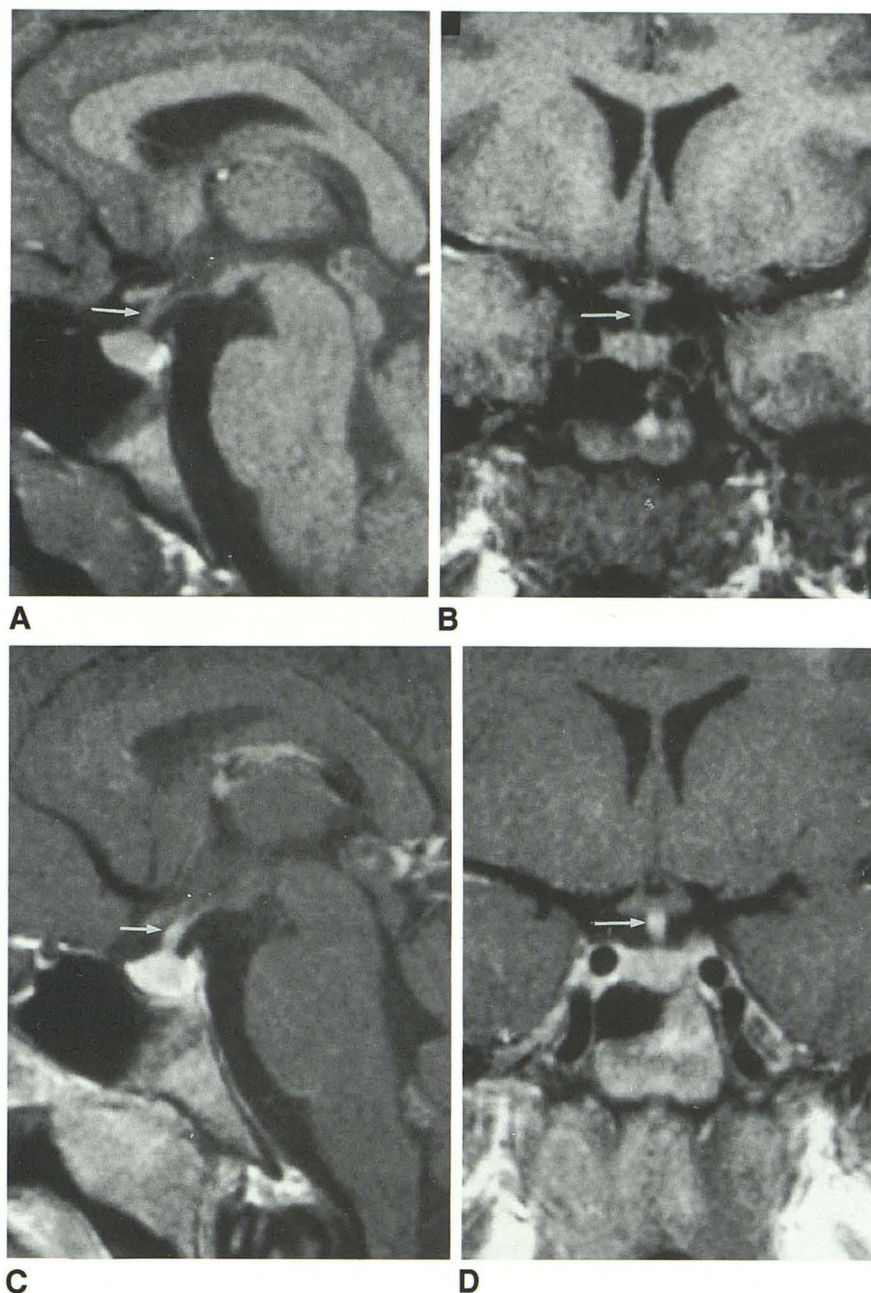


Fig. 5. Case 14, 11-year-old girl without DI. Sagittal (A) and coronal (B) T1-WI images (400/15) obtained before and after (C and D) intravenous injection of Gd-DTPA showing thickened pituitary stalk (arrow) (sagittal width = 3.41 mm, coronal width = 3.31 mm before Gd-DTPA and 4.44 mm and 4.23 mm after Gd-DTPA) and normal bright posterior pituitary signal.

thickening and even of secondary regrowth (12). We believe that different phases of activation, peculiar to LCH, may also play a major role in this variation.

The presence of a small anterior pituitary gland in two patients with growth hormone deficiency is in agreement with their functional status, as lack of hypothalamic growth hormone-releasing hormone may be responsible for smallness of the pituitary gland (26, 27).

Eight patients with systemic LCH without clinical features of DI had normal hyperintense pos-

terior signal, three had unexpectedly thickened PS, and one had a combination of thick PS and absent hyperintense posterior signal. Normal posterior pituitary signal in eight/nine children without DI is compatible with observation of normal subjects (8, 10, 29), whereas evidence of thickened PS in children with systemic LCH without DI, as in our four, has never been reported in the literature, nor was it observed in any of our control children. Thus this pattern seems dependent on the disease and possibly due to partial granulomatosis. It is well known that complete DI

TABLE 2: Pituitary stalk measurements in 14 children with LCH and in controls

	Prior to Gd-DTPA		Post-Gd-DTPA	
	Coronal	Sagittal	Coronal	Sagittal
Pituitary stalk controls				
Range	1.37–2.63	1.42–2.51		
Mean	1.92 ± 0.33	1.85 ± 0.32		
Children with LCH with and without DI				
Range	1.24–5.47	0.83–5.69	1.71–5.83	1.59–6.16
Mean	2.75 ± 1.32	2.74 ± 1.41	3.40 ± 1.49	3.45 ± 1.71
Children with LCH with DI				
Range	1.54–5.47	1.32–5.69	5.83	6.16
Mean	3.63 ± 1.74	3.60 ± 1.80	—	—
Children with LCH without DI				
Range	1.24–3.31	0.83–3.51	1.71–4.23	1.59–4.44
Mean	2.27 ± 0.76	2.27 ± 0.94	2.92 ± 1.00	2.91 ± 1.21

Note.—Mean stalk diameter prior to Gd-DTPA in LCH children vs controls: sagittal $P < .025$; coronal $P < .05$.

develops only when more than 80% of the neurons are destroyed (15). Before then, no clinical or imaging markers are currently known for screening of those at-risk patients. A prospective study with the water deprivation test showed that some asymptomatic patients have a partial vasopressin defect and are at risk of developing DI (5). Unfortunately, no data are available about MR evaluation of these patients. Functional hypothalamic neurohypophyseal challenge, coupled with MR follow-up study, seems particularly advisable in LCH patients with PS-thickening without DI.

It remains to be determined whether or not evidence of combined thickened PS and absent posterior pituitary without DI, as in the present case 12, represents a further stage of local damage with occult DI.

The sagittal and coronal measurements of the PS are similar either in the LCH group and in the controls. Children with LCH had a significantly larger PS than did controls. In particular, the highest values were observed in those patients who had DI and local evidence of histiocytic granuloma, while patients with LCH without DI had PS size ranging from the average value in controls up to twice that figure. The exiguity of our control sample did not allow us to draw an age-related chart for PS size. Comparison of val-

ues from our LCH patients without DI with the only published chart obtained by CT (30) suggests that some of them have PS size above the age- and sex-matched normal value.

Contrast medium injection was helpful to better define the PS shape and thus seems advisable in the evaluation of LCH patients. Dynamic study using Gd-DTPA could provide additional information in children with systemic LCH at risk of developing hypothalamic lesion (31).

MR imaging appears to provide a substantial contribution to the understanding of the natural history of the granulomatous infiltration caused by LCH in the hypothalamic-hypophyseal region. Hypothalamic nuclei damage and/or isolated thickening of the stalk at the infundibular level probably represent the preliminary phase of the histiocytic lesion. The progression of this could lead to functional section of the stalk, responsible for disappearance of the posterior pituitary hyperintensity, leading to the final stage represented by DI, which is seen in the follow-up of one quarter to one third of LCH patients and perhaps represents the final stage of this process. Prospective, systematic MR follow-up studies of LCH patients are needed to define better the frequency of CNS disease at the onset of histiocytosis, its progression rate during the course of the disease, its correlation with different activation phases in

untreated patients, the impact of different specific therapeutic regimens, and the predictive value of thicker stalks for DI.

References

1. Jaffe HL, Lichtenstein L. Eosinophilic granuloma of bone: a condition affecting one, several or many bones, but apparently limited to the skeleton, and representing the mildest clinical expression of the peculiar inflammatory histiocytosis also underlying Letterer-Siwe disease and Hand-Schuller-Christian disease. *Arch Pathol* 1944;37:99-106
2. Chu T, D'Angio GJ, Favara B, Ladisch S, Nesbit M, Pritchard J. Histiocytosis syndromes in children. *Lancet* 1987;1:208-209
3. Bokkerink JPM, deVaan GAM. Histiocytosis X. *Eur J Pediatr* 1980;135:129-146
4. Sims DG. Histiocytosis X. Follow-up of 43 cases. *Arch Dis Child* 1977;52:433-440
5. Dunger DB, Broadbent V, Yeoman E. The frequency and natural history of diabetes insipidus in children with Langerhans-Cell Histiocytosis. *N Engl J Med* 1989;321:1157-1162
6. Fujisawa I, Asato R, Nishimura K, et al. Anterior and posterior lobes of the pituitary gland: assessment by 1.5 T MR imaging. *J Comput Assist Tomogr* 1987;11:214-220
7. Fujisawa I, Asato R, Kawata M, et al. Hyperintense signal of the posterior pituitary on T1-weighted MR images: an experimental study. *J Comput Assist Tomogr* 1989;13:371-377
8. Gudinchet F, Brunelle F, Barth MO, et al. MR imaging of the posterior hypophysis in children. *AJNR* 1989;10:511-514
9. Chiumello G, Di Natale B, Pellini C, Beneggi A, Scotti G, Triulzi F. Magnetic resonance imaging in diabetes insipidus. *Lancet* 1989;1:901
10. Colombo N, Berry I, Kucharczyk J, et al. Posterior pituitary gland: appearance on MR images in normal and pathologic states. *Radiology* 1987;165:481-485
11. Rosenfield NS, Abrahams J, Komp D. Brain MR in patients with Langerhans Cell Histiocytosis: findings and enhancement with Gd-DTPA. *Pediatr Radiol* 1990;20:433-436
12. Tien R, Newton TH, McDermott MW, Dillon WP, Kucharczyk J. Thickened pituitary stalk on MR images in patients with diabetes insipidus and Langerhans cell histiocytosis. *AJNR* 1990;11:703-708
13. Tien R, Kucharczyk J, Kucharczyk W. MR imaging of the brain in patients with Diabetes insipidus. *AJNR* 1991;12:533-542
14. Maghnie M, Villa A, Aricò M, et al. Correlation between magnetic resonance imaging of posterior pituitary and neurohypophyseal function in children with diabetes insipidus. *J Clin Endocrinol Metab* 1992;74:795-800
15. Felig P, Baxter JD, Broadus AJ, Frohman LA. Endocrinology and metabolism. In: Robertson GL, ed. *Posterior pituitary*. New York: McGraw Hill, 1987:338-385
16. O'Sullivan RM, Sheehan M, Poskitt KJ, Graeb DA, Chu AC, Joplin GF. Langerhans Cell Histiocytosis of hypothalamus and optic chiasm: CT and MR studies. *J Comput Assist Tomogr* 1991;15:52-55
17. Avioli LV, Lasersohn JT, Lopresti JM. Histiocytosis X (Schuller-Christian Disease): a clinico-pathological survey, review of ten patients and the results of prednisone therapy. *Medicine* 1963;42:119-147
18. Kepes JJ, Kepes M. Predominantly cerebral forms of histiocytosis-X: a reappraisal of "Gagel's hypothalamic granuloma," "granuloma infiltrans of the hypothalamus" and "Ayala's disease" with a report of four cases. *Acta Neuropathol (Berl)* 1969;14:77-98
19. Bernard JD, Aguilar MJ. Localized hypothalamic histiocytosis-X: report of a case. *Arch neurol* 1969;20:368-372
20. Graif M, Pennock JM. MR imaging of histiocytosis X in the central nervous system. *AJNR* 1986;7:21-23
21. Pressman BD, Waldron RL II, Wood EH. Histiocytosis-X in the hypothalamus. *Br J Radiol* 1975;48:176-178
22. Ragland RL, Moss DS, Duffis AW, Wolf D, Knorr JR. CT and MR findings in diffuse cerebral histiocytosis: case report. *AJNR* 1991;12:525-526
23. Manelfe C, Louvet JP. Computed tomography in diabetes insipidus. *J Comput Assist Tomogr* 1979;3:309-316
24. Bonneville JF, Cattin F, Portha C, et al. Computed tomographic demonstration of the posterior pituitary. *AJNR* 1986;146:263-266
25. Bonneville JF, Cattin F, Diemann JL. The pituitary stalk. In: *Computed tomography of the pituitary gland*. New York: Springer Verlag, 1986;106-114
26. Maghnie M, Triulzi F, Larizza D, et al. Hypothalamic pituitary dwarfism: comparison between MR imaging and CT findings. *Pediatr Radiol* 1990;20:229-235
27. Maghnie M, Triulzi F, Larizza D, et al. Hypothalamic-pituitary dysfunction in growth hormone-deficient patients with pituitary abnormalities. *J Clin Endocrinol Metab* 1991;73:79-83
28. Fujisawa I, Nishimura K, Asato R, et al. Posterior lobe of the pituitary in diabetes insipidus: MR findings. *J Comput Assist Tomogr* 1987;11:221-225
29. Brooks BS, El Gammal T, Allison JD, Hoffman WH. Frequency and variation of the posterior pituitary bright signal on MR images. *AJNR* 1989;10:943-948
30. Seidel FG, Towbin R, Kaufman RA. Normal pituitary stalk size in children: CT study. *AJNR* 1985;6:733-738
31. Sakamoto F, Takashi M, Korogi Y, Bussaka H, Ushio Y. Normal and abnormal pituitary glands: gadopentetate dimeglumine-enhanced MR imaging. *Radiology* 1991;178:441-445